

A simplified post preparation technique after Thermafil obturation: evaluation of apical microleakage and presence of voids using methylene blue dye penetration

Luca Pusinanti
Riccardo Rubini¹
Agnese Pellati²
Nicoletta Zerman¹

¹ Restorative Department, Dental School,
University of Ferrara, Italy

² Department of Morphology and Embriology,
University of Ferrara, Italy

Corresponding author:

Luca Pusinanti
Via Migliari, 15
44123 Ferrara, Italy
Phone: +39 3334700102
E-mail: lucapuso@gmail.com

Summary

Aim. To evaluate the apical microleakage of Thermafil obturations after three different post space preparation techniques.

Materials and methods. 33 root canals of monoradicated extracted teeth were prepared with M two and then obturated with Thermafil. Teeth so treated were then divided into three groups and the post space to middle root was prepared using three different techniques. In samples in group A the housing for the post was created using a Torpan bur, and the carrier was partially removed only in the coronal portion. In samples in group B the carrier was completely removed and gutta-percha was hand compacted, before canal preparation using a Torpan bur. In samples in group C the carrier was completely removed, without gutta-percha compaction, before canal preparation using a Torpan bur. The roots were immersed for 72 hours in methylene blue dye solution and sectioned transversely at 1-3-5 mm from the apex for evaluation of dye penetration using a stereomicroscope. The data collected were processed using Win CAD software and subjected to statistical analysis using the Student t test for $p < 0.05$.

Results. There were no significant differences between the three groups, except for the presence of voids in the intermediate section of teeth in groups B and C.

Conclusions. Post space preparation did not influence the apical seal, and gutta-percha without

voids was always found in the last millimetre of the canal obturation. This study proposes a post preparation technique which provides for complete carrier removal using pliers, hand compaction of residual gutta-percha with a manual plugger and enlargement of the root canal, using appropriate post space burs, free of any interference from the carrier. Operating time is reduced, as is the risk of creating ledges or iatrogenic perforations.

Key words: thermafil, post space, apical micro leakage.

Introduction

The Thermafil (Dentsply Maillefer – Switzerland) obturation technique derives from an idea of Dr. W. Ben Johnson (1), who first described a technique in which gutta-percha moulded on a file was softened in a flame and inserted into the root canal with the file. The coronal portion of the file was then sectioned and removed and the apical portion left behind as a part of the root filling (2, 3). Marketed at the beginning of the 1990s, Thermafil endodontic obturators have since been completely modified and now form an integral part of a complete and sophisticated system of root canal obturation that, when used correctly, can give optimal results (4).

The wedge effect that occurs during carrier insertion, together with the very fine and homogeneous reticular structure of the gutta-percha, favours the penetration of the obturating materials into the lateral canals and dentinal tubules (5, 6) as in the vertical condensation technique and System-B (Sybron Endo – USA), but with an efficacy which is significantly superior to that of the lateral condensation, warm lateral condensation and Obtura (7, 8) (Obtura Spartan Endodontics – USA) techniques. The Thermafil technique shows a capacity to completely adapt to the canal walls which is comparable to that of other methods like vertical and lateral condensation (9-20). As for the capacity to hermetically seal the apical third, where more than 90% of all endodontic anatomical complexities are found, what emerges from the literature is that Thermafil obturations demonstrate better hermetic seal than is obtainable using the lateral condensation, Obtura or Ultrafil (Coltène/Whaledent - Switzerland) techniques, and equally good hermetic seal compared to warm vertical condensation or System-B (21-40).

The excellent results obtainable using the modern Thermafil obturation technique are largely due to standardization of the technique, regarding both the operative steps and the most recent techniques of root canal shaping using rotary instruments in NiTi, which allow the high-

est quality and the most homogeneous canal preparation. The Thermafil system is the best solution available today for the obturation of curved canals because the carrier is very flexible and easily adapts even to tight curves and limited canal diameters, making it possible to drastically reduce the time necessary for conservative preparation and obturation to working length, even in those canals which do not allow precise cone fitting.

The difficulty for post space preparation in cases where Thermafil has been used is due to the presence of the plastic carrier: the risks of inadvertently making ledges or lateral root perforations limit the use of carrier-based techniques. Many techniques for cutting down the carriers are described in the literature. The classic method is with a heat source using Touch'n Heat (Sybron Endo – USA) or System-B tips, or using appropriate burs like Post Space Burs, Calibrated burs, Torpan burs or Peeso reamers passively, without forcing, between carrier and gutta-percha. The rationale for these burs is to remove the carrier to the desired depth through the frictional heat generated during rotation. Even though there is no evidence for the risk of apical seal loss following immediate post space preparation, it is common practice to delay post placement to a second appointment, to permit complete setting of the sealer and stabilization of the whole obturation (41-47). In order to make the entire procedure for placing posts after Thermafil obturations safer, easier and quicker, the aim of this study was firstly to evaluate the apical seal and the presence of voids, using dye penetration into root canals obturated using the Thermafil technique after two different post preparations which both involved complete removal of the plastic carrier, and secondly to compare the results obtained with those of conventional post space preparation.

Because the capacity to hermetically seal the apical third is the most important criterion for evaluating endodontic procedures and techniques, it has been the subject of research projects using a great variety of methods (5-47), including infiltration of liquids and dyes, electrochemical methods, and infiltration with resin and radio-isotopes.

The infiltration of colorants is a common technique involving the immersion of the root in dyes like methylene blue, Prussian blue, eosin and India ink. Normally only the apical third comes into contact with the dye while the rest of the tooth is isolated using silicone or varnish. The infiltration can be either passive, obtained by simple immersion in the dye at atmospheric pressure or in a vacuum, or else active, forcing the dye into the root under pressure or by centrifugation. The root is then sectioned vertically or even diaphanized for measurement of the microleakage using an optical microscope. Passive methylene blue dye penetration is probably the technique most commonly used to evaluate the apical seal, and was chosen for this study because of its simplicity and limited cost.

Materials and methods

This study involved 33 single-rooted extracted teeth, stored in saline solution and subsequently divided into three groups as follows: group A (control group): 4 up-

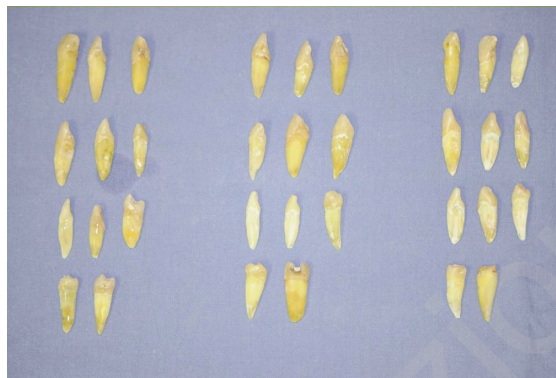

Figure 1. 33 extracted teeth.

per incisors, 1 canine, 3 premolars, 3 lower incisors; group B (study group 1): 4 upper incisors; 2 canines, 3 premolars and 2 lower incisors and group C (study group 2): 5 upper incisors, 2 canines, 3 premolars and 1 lower incisor (Fig. 1).

The root canals of all the teeth were prepared according to the following protocol: access to the pulp chamber was gained using a cylindrical diamond bur mounted on a high-speed handpiece and later expanded using a round bur mounted on a contrangle. Endodontic access was sounded with an EXDG-16 probe (Hu - friedy - USA), and the working length was visually determined using a K-file (Dentsply Maillefer - Switzerland) # 0.10. The root canals were shaped with Mtwo (Sweden & Martina - Italy) rotary NiTi instruments # 10/.04 – # 15/.05 – # 20/.06 mounted on an X-smart (Dentsply Maillefer - Switzerland) endodontic handpiece, used with delicate brushing movements to maintain a conservative preparation, alternated with thorough washing with 5% sodium hypochlorite (Ogna - Italy). After shaping of root canals, the preparation was checked with a Thermafil naked carrier and wiped dry with fine and medium paper points (Mynol Chemical Co. - USA). An x-fine paper point Pulp Canal Sealer (Kerrdental - USA) was placed above the canal walls and the root canals were obturated with the Thermafil technique, using caliber 20, 30 and 35 obturators to working length, choosing the obturator best suitable to the single root canal anatomy according to the root canal conformation and to the canal apex diameter. Thirty minutes after canal obturation, the carrier was sectioned with a Thermacut bur (Dentsply Maillefer - Switzerland) and post space preparations were carried out.

The samples in group A were then subjected to preparation of the endodontic space for application of fiber post as far as the middle root with a Torpan bur, used passively between the carrier and the gutta-percha, to enlarge the root canal correctly and to separate the most coronal portion of the Thermafil obturator, but without removing the apical portion.

The samples in group B were subjected to preparation of the endodontic space for application of fiber post as far as the middle root with a Torpan bur, after complete removal of the Thermafil carrier, which was pulled out with tweezers. Prior to the preparation of post space, gutta-percha was manually compacted using Schilder's

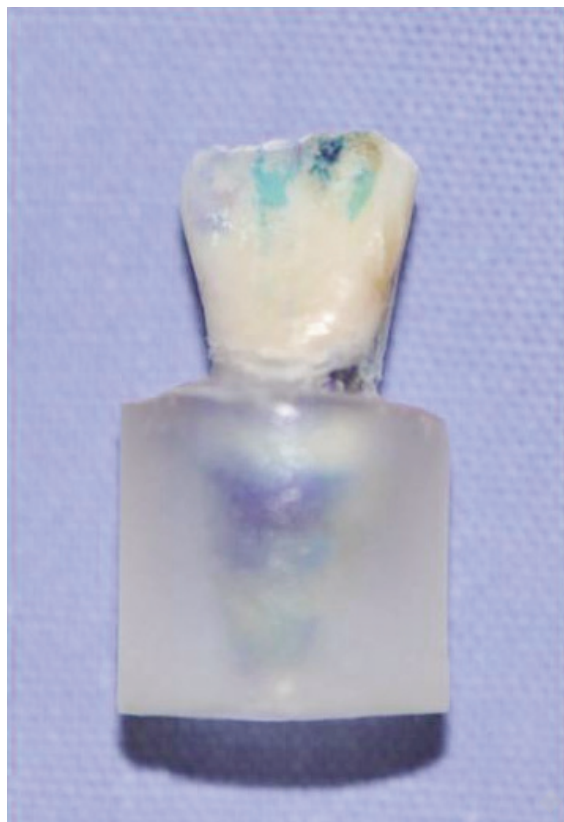

Figure 2. Tooth embedded in resin.

plugger (Dentsply Maillefer - Switzerland) # 8 and # 9. The samples in group C were subjected to preparation of the endodontic space for application of fiber post as far as the middle root with a Torpan bur, after complete removal of the Thermafil carrier, which was pulled out with tweezers. In this group no compaction of gutta-percha was carried out before using the Torpan bur.

The access to the pulp chamber was sealed with composite resin. Subsequently, the samples were immersed and stored for seven days in saline solution at 37 degrees before applying a homogeneous layer of nail polish on the root surface up to 1 mm from the apical foramen. When the insulating layer had dried, the teeth were fully immersed for 72 hours in methylene blue dye. After three days the samples were cleaned thoroughly in water and embedded in acrylic resin (Figure 2).

Subsequently for each of the 33 teeth three sections were made using Micromet Automatica (Remet - Italy) cutting system at 1 mm (level "a"), 3 mm (level "b"), and 5 mm (level "c") from the apex, making a total of 99 thin sections. The sections thus obtained were then analyzed using an optical microscope and processed using Win CAD software, to calculate the area of dentin colored by methylene blue in relation to the total dentinal area. The aim was to evaluate the degree of infiltration of root fillings at three distances from the apex (Figs. 3, 4). Optical magnification also made it possible to assess the presence of voids in the endodontic material (Fig. 5). Findings were subjected to statistical analysis using Student T Test for $p < 0.05$.

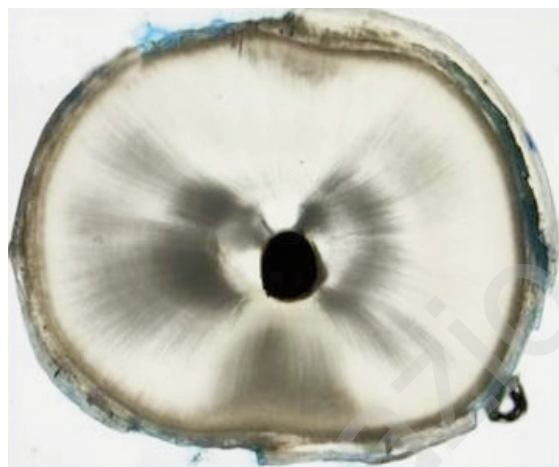

Figure 3. Sectioned sample without dentinal leakage.

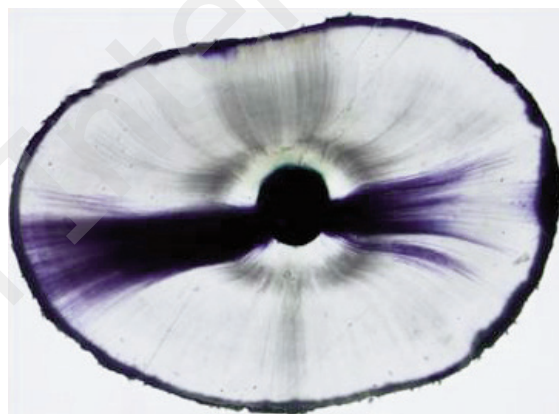

Figure 4. Sectioned sample with dentinal leakage 2.




Figure 5. Sectioned sample with void.

Results

In group A (the control group) the area which was infiltrated averaged 25.89% at 1 mm from the apex (section 1), 14.83% at 3 mm from the apex (section 2) and

Table 1. Section at 1 mm from apex.

Group A	% Dentin showing leakage	Voids	Group B	% Dentin showing leakage	Voids	Group C	% Dentin showing leakage	Voids
A1 a	0.61	No	B1 a	19.40	No	C1 a	4	No
A2 a	52.96	No	B2 a	0	No	C2 a	0	No
A3 a	1.55	No	B3 a	0	No	C3 a	35.67	No
A4 a	35.43	No	B4 a	3	No	C4 a	7.91	No
A5 a	27	No	B5 a	22	No	C5 a	82	No
A6 a	14.52	No	B6 a	22	No	C6 a	3	Yes
A7 a	41.21	No	B7 a	11.62	No	C7 a	4.70	No
A8 a	12.05	No	B8 a	7.44	No	C8 a	2.94	No
A9 a	44.80	No	B9 a	12.50	No	C9 a	43.40	No
A10 a	53.97	No	B10 a	44.76	No	C10 a	3.46	No
A11 a	0.66	No	B11 a	35.84	No	C11 a	26.73	No
Mean	25.89		Mean	16.26		Mean	19.39	
Standard Deviation	20.96		Standard Deviation	14.47		Standard Deviation	25.66	

Table 2. Section at 3 mm from apex.

Group A	% Dentin showing leakage	Voids	Group B	% Dentin showing leakage	Voids	Group C	% Dentin showing leakage	Voids
A1 b	0	No	B1 b	22.81	No	C1 b	2	No
A2 b	53.07	No	B2 b	0	No	C2 b	0	No
A3 b	0.42	No	B3 b	0	No	C3 b	48.78	Yes
A4 b	7.67	No	B4 b	2.28	No	C4 b	7.14	No
A5 b	0.93	No	B5 b	24.34	Yes	C5 b	91	Yes
A6 b	3.41	No	B6 b	40.51	Yes	C6 b	9.34	Yes
A7 b	9.18	No	B7 b	23.80	Yes	C7 b	7.14	Yes
A8 b	7.60	No	B8 b	10.13	No	C8 b	6.36	No
A9 b	37.02	No	B9 b	2.31	No	C9 b	81.03	Yes
A10 b	39.83	No	B10 b	54.67	No	C10 b	4.55	No
A11 b	4.02	No	B11 b	88	No	C11 b	40.21	Yes
Mean	14.83		Mean	24.44		Mean	27.05	
Standard Deviation	18.92		Standard Deviation	27.55		Standard Deviation	33.23	

19.88% at 5 mm from the apex (section 3). No voids were found in the endodontic obturating material. In group B (study group 1) the area which was infiltrated averaged 16.26% at 1 mm from the apex (section 1), 24.44% at 3 mm from the apex (section 2), with 3 voids found, and 30.7% at 5 mm from the apex (section 3) with 3 voids found.

In group C (study group 2) the area which was infiltrated averaged 13.39% at 1 mm from the apex (section 1) with 1 void found, 27.05% at 3 mm from the

apex (section 2) with 6 voids found, and 37.37% at 5 mm from the apex (section 3) with 7 voids found (Tabs. 1, 2 and 3).

What emerges from the statistical analysis is that there were no statistically significant differences with regard to infiltration of endodontic obturation by methylene blue between the three groups of data, distributed by level and distance from the apex of the sections.

There were also no statistically significant differences between the groups regarding the presence of voids in

Table 3. Section at 5 mm from apex.

Group A	% Dentin showing leakage	Voids	Group B	% Dentin showing leakage	Voids	Group C	% Dentin showing leakage	Voids
A1 c	0	No	B1 c	47.39	Yes	C1 c	4	No
A2 c	37.25	No	B2 c	0	No	C2 c	0	No
A3 c	0	No	B3 c	0	No	C3 c	100	Yes
A4 c	24.31	No	B4 c	22.86	No	C4 c	12.58	No
A5 c	0.53	No	B5 c	8.98	No	C5 c	65,43	Yes
A6 c	20.75	No	B6 c	60.44	Yes	C6 c	10.44	Yes
A7 c	35.87	No	B7 c	35.54	Yes	C7 c	29.84	Yes
A8 c	0.86	No	B8 c	14.92	No	C8 c	30.29	Yes
A9 c	39.64	No	B9 c	18.25	No	C9 c	85.78	Yes
A10 c	52.19	No	B10 c	44.32	No	C10 c	0	No
A11 c	7.27	No	B11 c	85	No	C11 c	72.79	Yes
Mean	19.88		Mean	30.70		Mean	37.37	
Standard Deviation	19.22		Standard Deviation	26.72		Standard Deviation	36.96	

the root canal obturating material in the sections at 1 and 3 mm from the apex.

Statistically significant differences were seen between groups B and C, and between groups A and C, regarding the presence of voids in sections 5 mm from the apex.

Discussion

It has been widely demonstrated in the literature that the Thermafil system gives excellent results in endodontic fillings (21-40), whereas this technique constitutes an obstacle and is difficult to use when preparing the lodging for a retention intraradicular pivot. In the literature several methods for post-space preparation in root canals filled with Thermafil are described, but they seem complicated. With a view to simplifying the procedure, in the present study we evaluated the effect on the quality of endodontic seals of a method which involves removal of the Thermafil carrier, possibly followed by the recompaction of gutta-percha while it is still warm.

The first important point which emerged from the study was the presence of possible infiltration in all the groups, including samples in which the integrity of Thermafil obturators was not altered before or during the phase of post-space preparation. We suppose that mechanical and thermal stresses generated during post-space preparation can have a negative influence on sealing precision which can compromise the correct adaptation of gutta-percha to the canal walls, as claimed by Gopikrishna & Parameswaren in 2006 (43). It is also true that microleakage between gutta-percha and canal dentin could occur in root canals completely filled with Thermafil before, or else in the absence of any post space preparation. There are studies, in fact,

which observed three times more infiltration in canals filled with Thermafil which had a plastic carrier than in those obturated with Thermafil using a metallic carrier, or using the lateral technique of compaction (44). The timing of the post space preparation does not seem to influence microleakage, as can be deduced from the literature: statistically significant differences were not found between microleakage from samples in which post space was prepared immediately after obturation and microleakage from samples in which post space was prepared 7 days after obturation (45). Significant differences in the quality of apex seal were not seen in root canals filled with Thermafil before or after post space preparation (46, 47). Our results show, moreover, that the standard deviation of the mean percentages of infiltrated surface is relatively high, which could indicate insufficient predictability regarding the possibility of apical microleakage; this may be due to the high morphologic endodontic variability of radicular apices. Our results suggest that canal filling seal obtained using the Thermafil technique does not depend on, and is not modified by, the technique used for post-space preparation, even without waiting 24 hours for full setting of the gutta-percha. Another important result which emerged during our evaluation of the precision of the endodontic filling in the apical third, was the observation under the optical microscope of the presence or absence of gutta-percha well adapted to the dentinal canal walls in the three sections investigated (at 1, 3 and 5 millimeters from the apex). It was also important to find endodontic filling material without voids in the apical millimeter of the root canal, in the presence or absence of the Thermafil carrier, while a statistically significant difference in the occurrence of voids in the canal filling material was found only between group C and groups A and B.

At this point we can assert that this research has proposed a technique which simplifies the procedure for post space preparation of root canals filled using the Thermafil technique. Even if further studies will be necessary, we can say that it is possible to completely remove the Thermafil carrier using tweezers, and to compact gutta-percha inside the root canal using manual pluggers, to limit the formation of voids inside the endodontic filling materials that could alter canal seal in the long term. Using a common bur for post space preparation, the canal lumen can easily be enlarged since the coronal portion of the root canal is free from interference. Operating times are considerably shortened and the risk of creating iatrogenic perforations is notably reduced.

References

1. Johnson WB. A new gutta-percha technique. *J Endod* 1978; 4:184.
2. Becker TA, Donnelly JC. Thermafil obturation: a literature review. *Gen Dent* 1997; 45(1):46-55.
3. Gulabivala K, Leung SF. Review of a new root canal obturation technique. *Dent Update* 1994; 21(2):73-78,80-83.
4. Buchanan S. Common misconceptions about carrier-based obturation. *Endod Pract* 2009 Nov; 7-11.
5. Blum JY, Machtou P, Micallief JP. Analysis of forces developed during obturations. Wedging effect: Part II. *J Endod* 1998; 24(4):223-228.
6. Weis MV, Parashos P, Messer HH. Effect of obturation technique on sealer cement thickness and dentinal tubule penetration. *Int Endod J* 2004; 37(10):653-663.
7. Clinton K, Van Himel T. Comparison of a warm gutta-percha obturation technique and lateral condensation. *J Endod* 2001; 27(11):692-695.
8. Goldberg F, Artaza LP, De Silvio A. Effectiveness of different obturation techniques in the filling of simulated lateral canals. *J Endod* 2001; 27(5):362-364.
9. Weller RN, Kimbrough WF, Anderson RW. A comparison of thermoplastic obturation techniques: adaptation to the canal walls. *J Endod* 1997; 23(11):703-706.
10. Somma F, Cretella G, Carotenuto M, Pecci R, Bedini R, De Biasi M, Angerame D. Quality of thermoplasticized and single point root fillings assessed by micro-computed tomography. *Int End J* 2011; 44(4):362-369.
11. Marciano MA, Ordinola-Zapata R, Cunha TV, Duarte MA, Cavengao BC, Garcia RB, Bramante CM, Bernardineli N, Moraes IG. Analysis of four gutta-percha techniques used to fill mesial root canals of mandibular molars. *Int End J* 2011; 44(4):321-329.
12. Jarrett IS, Marx D, Covey D, Karmazin M, Lavin M, Gound T. Percentage of canals filled in apical cross-sections - an in vitro study of seven obturation techniques. *Int Endod J* 2004; 37(6):392-398.
13. Gençoğlu N, Samani S, Günday M. Dentinal wall adaptation of thermoplasticized gutta-percha in the absence or presence of smear layer: a scanning electron microscopic study. *J Endod* 1993; 19(11):558-562.
14. De-Deus G, Gurgel-Filho ED, Magalhães KM, Coutinho-Filho T. A laboratory analysis of gutta-percha filled area obtained using Thermafil, System B and lateral condensation. *Int Endod J* 2006; 39(5):378-383.
15. Schäfer E, Olthoff G. Effect of three different sealers on the sealing ability of both Thermafil obturators and cold laterally compacted gutta-percha. *J Endod* 2002; 28(9):638-642.
16. Anbu R, Nandini S, Velmurugan N. Volumetric analysis of root filling using spiral computed tomography: an in vitro study. *Int Endod J* 2010; 43(1):64-68.
17. Gutmann JL, Saunders WP, Saunders EM, Nguyen L. A assessment of the plastic Thermafil obturation technique. Part 1. Radiographic evaluation of adaptation and placement. *Int End J* 1993; 26(3):173-178.
18. Juhlin JJ, Walton RE, Dovgan JS. Adaptation of Thermafil components to canal walls. *J Endod* 1993; 19(3):130-135.
19. Johnson B, Lasater D. Adaptation of Thermafil components to canal walls. *J Endod* 1993; 19(6):266.
20. Lee CQ, Cobb CM, Robinson SJ, LaMartina T, Vo T. In vitro evaluation of the thermafil technique with and without gutta-percha coating. *Gen Dent* 1998; 46(4):378-381.
21. Pathomvanich S, Edmunds DH. The sealing ability of Thermafil obturators assessed by four different microleakage techniques. *Int Endod J* 1996; 29(5):327-334.
22. Haikel Y, Freymann M, Fanti V, Claisse A, Poumier F, Watson M. Apical microleakage of radiolabeled lysozyme over time in three techniques of root canal obturation. *J Endod* 2000; 26(3):148-152.
23. Xu Q, Ling J, Cheung GS, Hu Y. A quantitative evaluation of sealing ability of 4 obturation techniques by using a glucose leakage test. *Oral Surg Oral Med Oral Pathol Oral Radiol Endod* 2007; 104(4):e109-113.
24. Karagenç B, Gençoğlu N, Ersoy M, Canserver G, Külekçi G. A comparison of four different microleakage tests for assessment of leakage of root canal fillings. *Oral Surg Oral Med Oral Pathol Oral Radiol Endod* 2006; 102(1):110-113.
25. Kontakiotis E, Chantotis A, Georgopoulou M. Evaluation of 3 obturation techniques. *Quintessence Int* 2007; 38(4):e195-200.
26. Kytridou V, Gutmann JI, Nunn MH. Adaptation and sealability of two contemporary obturation techniques in the absence of the dentinal smear layer. *Int Endod J* 1999; 32(6):464-474.
27. Pommel L, Camps J. In vitro apical leakage of System B compared with other filling techniques. *J Endod* 2001; 27(7):449-451.
28. Gençoğlu N, Samani S, Günday M. Evaluation of sealing properties of Thermafil and Ultrafil techniques in the absence or presence of smear layer. *J Endod* 1993; 19(12):599-603.
29. McMurtrey LG, Krell KV, Wilcox LR. A comparison between Thermafil and lateral condensation in highly curved canals. *J Endod* 1992; 18(2):68-71.
30. Scott AC, Vire DE, Swanson R. An evaluation of the Thermafil endodontic obturation technique. *J Endod* 1992; 18(7):340-343.
31. Fabra-Campos H. Experimental apical sealing with a new canal obturation system. *J Endod* 1993; 19(2):71-75.
32. Bhambhani SM, Sprechman K. Microleakage comparison of Thermafil versus vertical condensation using two different sealers. *Oral Surg Oral Med Oral Pathol* 1994; 78(1):105-108.
33. Dummer PM, Lyle L, Rawle J, Kennedy JK. A laboratory study of root fillings in teeth obturated by lateral condensation of gutta-percha or Thermafil obturators. *Int Endod J* 1994; 27(1):32-38.
34. Hata G, Kawazoe S, Toda T, weine FS. Sealing ability of thermoplasticized gutta-percha fill techniques as assessed by a new method of determining apical leakage. *J Endod* 1995; 21(4):167-172.
35. Abarca AM, Bustos A, Navia M. A comparison of apical sealing and extrusion between Thermafil and lateral condensation techniques. *J Endod* 2001; 27(11):670-672.
36. Punia SK, Nadig P, Punia V. An in vitro assessment of apical microleakage in root canals obturated with gutta-flow, Resilon, Thermafil and lateral condensation. A stereomicroscopic study. *J Conserv Dent* 2011; 14(2):173-177.

37. Gulabivala K, Holt R, Long B. An in vitro comparison of thermoplasticized gutta-percha obturation techniques with cold lateral condensation. *Endod Dent Traumatol* 1998; 14(6):262.
38. Gençoğlu N, Oruçoğlu H, Helvacioğlu D. Apical leakage of different gutta-percha techniques: Thermafil, Js Quick-Fill, Soft Core, Microseal, System B and lateral condensation with a computerized fluid filtration meter. *Eur J Dent* 2007; 1(2):97-103.
39. Dalat DM, Spångberg LS. Comparison of apical leakage in root canals obturated with various gutta-percha techniques using a dye vacuum tracing method. *J Endod* 1994; 20(7):315-319.
40. Inan U, Aydemir H, Taşdemir T. Leakage evaluation of three different root canal obturation techniques using electrochemical evaluation and dye penetration evaluation methods. *Aust Endod J* 2007; 33(1):18-22.
41. Gutmann JL, Saunders WP, Saunders EM, Nguyen L. A assessment of the plastic Thermafil obturation technique. Part 3. The effect of post space preparation on the apical seal. *Int End J* 1993; 26(3):184-189.
42. Ravanshad S, Torabinejad M. Coronal dye penetration of the apical filling materials after post space preparation. *Oral Surg Oral Med Oral Pathol* 1992; 74(5):644-647.
43. Gopikrishna V, Parameswaren A. Coronal sealing ability of three sectional obturation techniques – SimpliFill, Thermafil and warm vertical compaction – compared with cold lateral condensation and post space preparation. *Aust Endod J* 2006; 32(3):95-100.
44. Ricci ER, Kessler JR. Apical seal of teeth obturated by the laterally condensed gutta-percha, the Thermafil plastic and Thermafil metal obturator techniques after post space preparation. *J Endod* 1994; 20(3):123-126.
45. Saunders WP, Saunders EM, Gutmann JL, Gutmann ML. An assessment of the plastic Thermafil obturation technique. Part 3. The effect of post space preparation on the apical seal. *Int Endod J* 1993; 26(3):184-189.
46. Dalat DM, Spångberg LS. Effect of post preparation on the apical seal of teeth obturated with plastic Thermafil obturators. *Oral Surg Oral Med Oral Pathol* 1993; 76(6):760-765.
47. Rybicki R, Zillich R. Apical sealing ability of Thermafil following immediate and delayed post space preparations. *J Endod* 1994; 20(2):64-66.