

Uveitis and Acute Interstitial Nephritis: What to Expect

Noel Lorenzo Villalba, Silvia Marrero Robayna, Davinia Ramírez Medina, Sara Moreno Casas, José Carlos Rodríguez Pérez

Hospital Universitario Dr. Negrin, Las Palmas de Gran Canaria, Spain

Abstract:

A 46-year-old female patient presenting with acute interstitial nephritis and anterior uveitis was admitted. The renal biopsy disclosed the presence of interstitial nephritis, confirming the clinical diagnosis of tubulointerstitial nephritis and uveitis (TINU) syndrome. Treatment with oral steroids was started, with prompt improvement of symptoms and laboratory abnormalities.

Keywords: TINU syndrome, acute interstitial nephritis, anterior uveitis

Received: 28/07/2014

Accepted: 26/08/2014

Published: 01/10/2014

How to cite this article: Villalba NL, Marrero Robayna S, Ramírez Medina D, Moreno Casas S, Rodríguez Pérez JC. Uveitis and Acute Interstitial Nephritis: What to Expect, *EJCRIM* 2014;1:doi: 10.12890/2014_000111

Conflicts of Interests: The authors declare that they have no conflicts of interest related to this research.

Introduction

Tubulointerstitial nephritis and uveitis (TINU) syndrome is rare. A unique subset of patients with interstitial nephritis has TINU syndrome (tubulointerstitial nephritis and uveitis). Although most patients with TINU are adolescents and young women, with a median age of 15 years, the disease has also been reported in adults. No identifiable risk factors were found in most cases reported in the literature. Prior infection or the use of specific drugs (antibiotics to treat upper respiratory infections and nonsteroidal anti-inflammatory drugs) have been claimed to play a causative role. Clinical manifestations in addition to uveitis and interstitial nephritis may include a wide range of systemic findings including fever, weight loss, fatigue, malaise, anorexia, abdominal and flank pain, arthralgias, myalgias, headache, polyuria and nocturia.

Case description

A 46-year-old female patient was transferred to our hospital because of unresolving acute renal failure. She had been followed in the outpatient clinic for generalized adenopathies and anterior uveitis, but no conclusive diagnosis had been reached. Her previous medical history consisted of a deep venous thrombosis in 2011; factor V deficit had been demonstrated and she was being treated with oral anticoagulants (acenocumarol 1 mg/day). Recurrent polyarthralgias were referred without a definite diagnosis. She was taking steroid ophthalmic drops twice daily. Family history was non-contributive.

On examination, she was afebrile, her heart rate was 62 beats/min, blood pressure 110/80 mmHg and oxygen saturation 98% on room air. Cervical, supraclavicular and inguinal adenopathies were noted. Pelvic examination revealed an active haemorrhage. The remaining physical examination was unremarkable. The patient was sent for a complete laboratory evaluation (*Table 1*) and abdominal ultrasound.

| CBC/Chemistry panel | Value | Normal range | Units |
|---|---|--------------|------------|
| Leucocytes | 7.2 | 4.5–11.0 | 103 u/l |
| Erythrocytes | 5.2 | 4.5–6.5 | 103 u/l |
| Haemoglobina | 10.4 | 13–17 | g/dl |
| MCV | 76 | 80–98 | fl |
| IST | 13 | 20–45 | % |
| Iron | 47 | 59–158 | µg/dl |
| Ferritin | 33 | 25–300 | ng/ml |
| Transferrin | 231 | 185–380 | mg/dl |
| Platelets | 135 | 150.0–450.0 | 103 u/l |
| Urea | 107 | 8–53 | mg/dl |
| Creatinine | 4.39 | 0.7–1.2 | mg/dl |
| Glucose | 89 | <136 | mg/dl |
| Fractional excretion of sodium ^b | 4.15 | | % |
| Sodium | 134 | 136–145 | mEq/l |
| Potassium | 4.2 | 3.5–5.5 | mEq/l |
| Chloride | 100 | 98–111 | mEq/l |
| Calcium | 8.7 | 8.4–10.2 | mEq/l |
| Coagulation tests | | | |
| INR | 7.00 | | |
| Blood gases | | | |
| pHc | 7.29 | 7.35–7.45 | |
| pCO2 | 42 | 35–45 | mmHg |
| HCO3 | 14.5 | 20–22 | mEq/l |
| Anion gap | 20 | 12±2 | mEq/l |
| Urinalysis | | | |
| pH | 7 | 4.7–8.1 | |
| Leucocytes | 25 | <25 | 7µl |
| Proteins | 25 | 0–30 | mg/dl |
| Density | 1002 | 1005–1025 | g/l |
| Glucose | 250 | | mg/dl |
| Nitrites | Negative | | |
| Sediment | 1-6 RBC, epithelial cats Normal Alb/Cr ratio | | |
| 24-h urine | | | |
| Diuresis | 2500 | 1–2 | l |
| Proteinuria | 0.2 | 0–0.3 | g/24 h |
| Sodium | 42 | 20–200 | (mEq/24 h) |
| Potassium | 28 | 25–130 | (mEq/24 h) |
| Glucose | 0.4 | 0 | g/24 h |
| Creatinine clearance | 15 | 75–115 | ml/min |

^a Anaemia was attributable to renal failure.

^b Fractional excretion of sodium >>1% is in part indicative of tubular damage. In this case, interstitial nephritis was consistent with the presence of polyuria and normoglycaemic glycosuria. Urine analysis showed glycosuria and low urine density, consistent with tubular interstitial damage. Surprisingly, there were no leukocyte or epithelial casts.

^c Metabolic acidosis with slightly increased anion gap and normal chloride secondary to uraemic acidosis in the context of acute renal failure.

The acenocumarol was discontinued and the international normalized ratio (INR) became normal in 48 h. The vaginal haemorrhage stopped after INR was controlled and abdominal ultrasound ruled out gynaecologic abnormalities. The clinical and laboratory findings suggested that we were facing a patient with renal tubular derangement and acute uveitis. renal tubular derangement and acute uveitis.

The viral serology screening (HIV, HBV, HCV, EBV, CMV) was negative; cryoglobulins, immunoglobulins, angiotensin-converting enzyme and serum complement were normal. Autoimmunity exams showed positive antinuclear antibodies (ANA; 1/320), while anti-DNA, anti-Smith, anti-Ro, anti-La, ANCA and anti-GBM antibodies were negative. Schirmer and pathergy tests were negative. HLA-B51 and PPD skin test were negative. A renal biopsy was deemed necessary. The acenocumarol was discontinued and the international normalized ratio (INR) became normal in 48 h. The vaginal haemorrhage stopped after INR was controlled and abdominal ultrasound ruled out gynaecologic abnormalities. The clinical and laboratory findings suggested that we were facing a patient with renal tubular derangement and acute uveitis. The viral serology screening (HIV, HBV, HCV, EBV, CMV) was negative; cryoglobulins, immunoglobulins, angiotensin-converting enzyme and serum complement were normal. Autoimmunity exams showed positive antinuclear antibodies (ANA; 1/320), while anti-DNA, anti-Smith, anti-Ro, anti-La, ANCA and anti-GBM antibodies were negative. Schirmer and pathergy tests were negative. HLA-B51 and PPD skin test were negative. A renal biopsy was deemed necessary. It showed an important mononuclear infiltration, mainly consisting of lymphocytes. There was tubular swelling, but the vascular structures were preserved (Figs. 1–3).

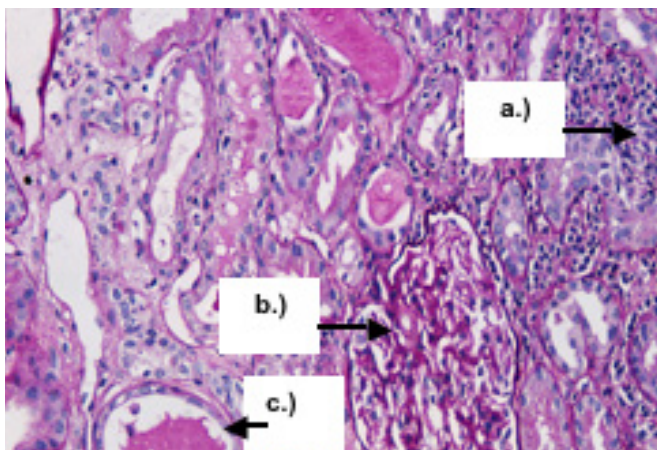


Figure 1: PAS staining, magnification x20. The interstitium is occupied by an extensive acute inflammatory infiltrate (a), with adjacent areas of initial fibrosis. The glomeruli (b) are spared by the inflammatory process. (c) Tubules

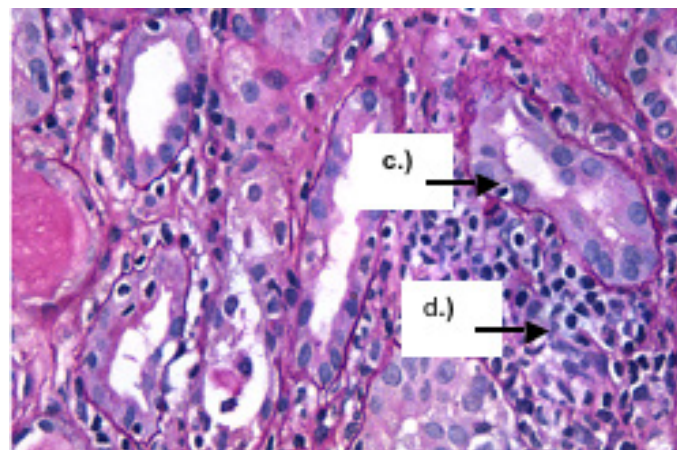


Figure 2: PAS x40. Interstitial infiltration with lymphocytes (d) surrounding the tubules (c). A lymph cell can be seen within the epithelium. Immunofluorescence (not shown) was negative.

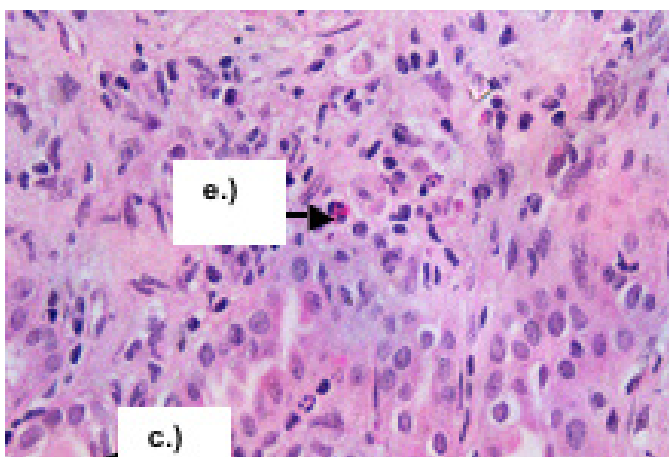


Figure 3: HE x40. The tubules (c) are surrounded by an extensive area of fibrosis. Eosinophils (e), polymorphonuclear cells and apoptotic epithelial cells isolated from the tubules (nuclei appear as debris in dark blue) are visible.

TINU syndrome was diagnosed and the patient was treated with oral steroids, attended by a gradual improvement of renal function (*Table 2*).

| Serum Creatinine (mg/dl) | | | |
|--------------------------|------------|-----------|-----------|
| Discharge | 13 days | 1 month | 2 months |
| 2.7 mg/dl | 2.04 mg/dl | 1.3 mg/dl | 1.2 mg/dl |

Table 2: Renal function curve after discharge

Discussion

The differential diagnosis of interstitial nephritis occurring in association with ocular findings is broad. Thus, many autoimmune diseases should be considered in this setting such as sarcoidosis, Sjögren's syndrome, systemic lupus erythematosus, Wegener's granulomatosis and Behçet's disease. On the other hand, infectious diseases, such as tuberculosis, brucellosis, toxoplasmosis and histoplasmosis, could also lead to a similar clinical picture [1]. The initial workup of the patient was aimed at ruling out these medical conditions.

Interestingly, many of these disorders may present with additional ocular findings that are distinct from uveitis [2], as well as with evidence of the involvement of additional organs, thereby suggesting the correct diagnosis. However, they were not present in this patient. In addition, sarcoidosis and Sjögren's syndrome have similar findings to TINU, making accurate diagnosis difficult in the absence of characteristic involvement of other organs, as in our case, except for the presence of adenopathies. Another difficult task is to distinguish patients with TINU syndrome and late-onset uveitis from those with drug-induced interstitial nephritis.

In our case, there was no previous drug exposure.

There are no specific serum markers or laboratory findings that are unique to patients with TINU. Laboratory findings may include leukocyturia, eosinophilia, anaemia, slightly abnormal liver function tests and an elevated erythrocyte sedimentation rate and C-reactive protein [3]. Associations of TINU with a variety of serologic markers in the absence of their correspondent disease have been reported. Thus, the disorder has been associated with ANA as in our case, where there were no other clinical signs of the systemic involvement of systemic lupus.

The definite diagnosis of TINU syndrome requires a renal biopsy, which was consistent with acute interstitial nephritis [4]. It confirmed the diagnosis and the patient was treated with oral steroids, even though renal involvement is generally believed to be self-limited [5]. Renal function began to improve in a week, such that serum creatinine was 2.7 mg/dl at discharge (*Table 2*).

Learning Points

- TINU syndrome is the association of tubulointerstitial nephritis and uveitis.
- The pathogenesis of TINU syndrome is unknown, although its association with systemic findings suggests autoimmunity.
- The diagnosis of TINU syndrome is suggested by the clinical combination of uveitis and renal involvement, requiring renal biopsy for confirmation.

References

1. Li C, Su T, Chu R, Li X, Yang L. Tubulointerstitial nephritis with uveitis in Chinese adults, *Clin J Am Soc Nephrol* 2014;**9**:21.
2. Mandeville JT, Levinson RD, Holland GN. The tubulointerstitial nephritis and uveitis syndrome, *Surv Ophthalmol* 2001;**46**:195.
3. Tan Y, Yu F, Qu Z, Su T, Xing GQ, Wu LH et al. Modified C-reactive protein might be a target autoantigen of TINU syndrome, *Clin J Am Soc Nephrol* 2011;**6**:93.
4. Joss N, Morris S, Young B, Geddes C. Granulomatous interstitial nephritis, *Clin J Am Soc Nephrol* 2007;**2**:222.
5. Takemura T, Okada M, Hino S, Fukushima K, Yamamoto S, Miyazato H et al. Course and outcome of tubulointerstitial nephritis and uveitis syndrome, *Am J Kidney Dis* 1999;**34**:1016.