

## Late Infective Endocarditis Associated with an Atrial Septal Defect Occluder Device

Ana Milena Mejía Sanjuanelo<sup>1</sup>, María Carolina Manzur Barbur<sup>2</sup>, María Cristina Martínez-Ávila<sup>2</sup>, Juan Camilo García Domínguez<sup>3</sup>

<sup>1</sup> Internal Medicine Department, Hospital Universidad del Norte, Barranquilla, Colombia

<sup>2</sup> Internal Medicine Department, Centro Hospitalario Serena del Mar, Cartagena, Colombia

<sup>3</sup> Cardiology Division, Centro Hospitalario Serena del Mar, Cartagena, Colombia

Doi: 10.12890/2022\_003238 - European Journal of Case Reports in Internal Medicine - © EFIM 2022

Received: 04/02/2022

Accepted: 08/02/2022

Published: 15/03/2022

**How to cite this article:** Mejía Sanjuanelo AM, Manzur Barbur MC, Martínez-Avila MC, García Domínguez JC. Late infective endocarditis associated with an atrial septal defect occluder device. *EJCRIM* 2022;9:doi:10.12890/2022\_003238.

**Conflicts of Interests:** The Authors declare that there are no competing interests.

This article is licensed under a [Commons Attribution Non-Commercial 4.0 License](https://creativecommons.org/licenses/by-nc/4.0/)

### ABSTRACT

The Amplatzer septal occluder is one of several percutaneous devices used for the closure of secundum atrial septal defects. The main complications are related to the procedure, with infection being the least common. We present the case of a 67-year-old woman with a secundum atrial septal defect, who, 3 years after repair with an Amplatzer occluder, was admitted with sepsis and bacteraemia following recent hospitalization in an intensive care unit. Transoesophageal echocardiography showed the presence of a mobile echogenic structure in the left atrium suggestive of a vegetation. Few cases of late endocarditis involving the Amplatzer device have been reported, even though partial endothelialization is one of the risk factors. There are no guidelines for the prevention, diagnosis or management of this complication.

### KEYWORDS

Late endocarditis, Amplatzer, atrial septal defect, transoesophageal echocardiography

### LEARNING POINTS

- The Amplatzer septal occluder is one of several alternatives for the closure of atrial septal defects and has few related complications, with infection being the least common.
- Device-related endocarditis presents either early (<6 months) or late (>6 months).
- In our case, transoesophageal echocardiography played a key role in the diagnosis of late endocarditis.

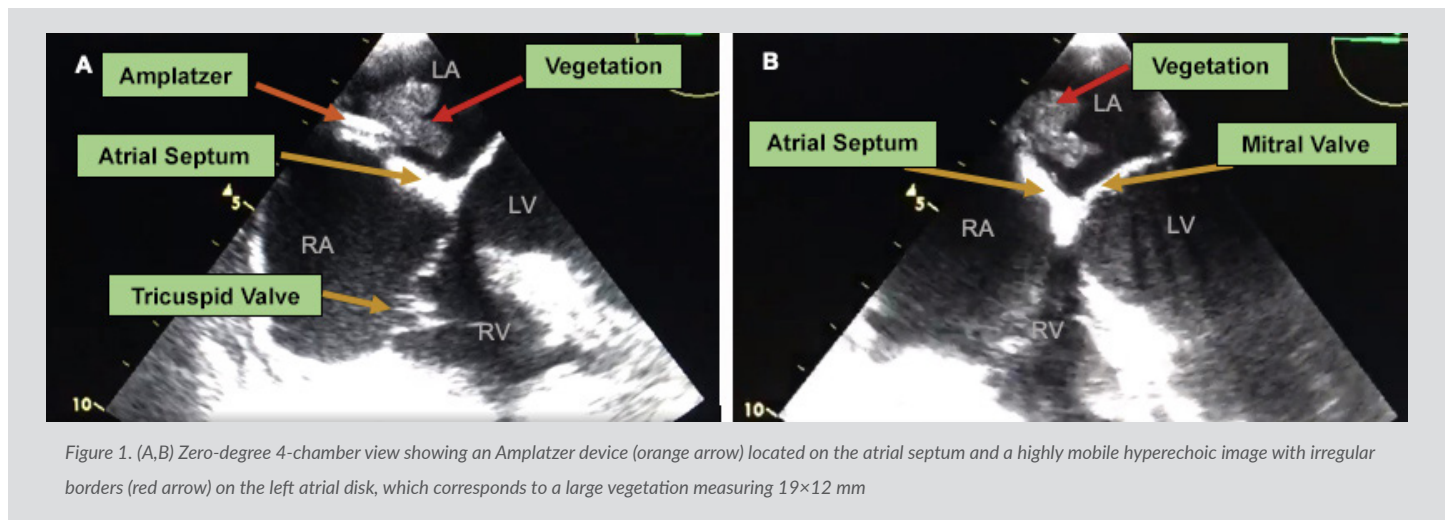
### INTRODUCTION

The Amplatzer septal occluder is one of several percutaneous devices used for the closure of secundum atrial septal defects. It is made of nitinol-titanium memory wire mesh infused with polyester patches that facilitate occlusion and endothelialisation<sup>[1, 2]</sup>. Most of the complications are related to the procedure itself, and include embolization, malposition of the device, cardiac perforation and arrhythmias, with infection being the least common complication (0–1%)<sup>[3]</sup>. Most associated infections occur in the first 6 months after implantation and are related to the procedure<sup>[4]</sup>. There are few reported cases of late endocarditis involving this device.

We present the case of a patient with transient ischaemic stroke secondary to septic thrombi due to late bacterial endocarditis associated with an Amplatzer device.

## CASE DESCRIPTION

A 67-year-old woman with history of obesity, hypertension, ischaemic stroke and an atrial septal defect (3-mm ostium secundum interatrial communication), which had been percutaneously occluded with an Amplatzer device 3 years previously, was admitted to the emergency department due to 5 days of persistent crampy abdominal pain and vomiting suggestive of intestinal obstruction that required immediate surgery. A right hemicolectomy was performed with an ileocolic anastomosis, revealing a moderately differentiated adenocarcinoma which had spread to nearby lymph nodes and through the peritoneum. She was discharged after 7 days in the intensive care unit in good condition. One week later, the patient attended the emergency room with sudden onset of right-sided weakness that had lasted 3 minutes, with spontaneous recovery. Swelling was evident along the anterior edge of the left sternocleidomastoid measuring approximately 3×4 cm, at the central venous catheter insertion site from the previous hospitalization. Her heart rate was 124 bpm, auscultation revealed sinus tachycardia, and temperature was 39°C. The patient was admitted, and initial laboratory work-up carried out. Blood samples showed leucocytosis and neutrophilia (white cell count 20,120/l, neutrophils 93.8%, lymphocytes 1.3%) and elevated acute phase reactants (PCR 150.7 mg/l). Doppler ultrasonography of neck veins identified deep vein thrombosis in the internal jugular, subclavian and left axillary vein, so anticoagulation with low-molecular-weight heparin (dalteparin 200 U/kg/daily) was initiated in light of her recent neoplasm diagnosis. Blood cultures were obtained which showed methicillin-sensitive *Staphylococcus aureus*. A transoesophageal echocardiogram performed on hospital day 2 revealed the presence of a large, highly mobile echodense mass on the surface of the Amplatzer device, measuring 19×12 mm with irregular edges and corresponding to a large vegetation, considered to be late endocarditis associated with the device (Fig. 1).



Echocardiographic findings and neurological manifestations suggested a high embolic risk, with the potential need for surgical intervention. However, the patient and her family refused the procedure due to the advanced stage of her recently diagnosed neoplasm, opting instead for a conservative approach with a pathogen-directed intravenous antibiotic regime with oxacillin. The patient remained hospitalized with antibiotic treatment alongside persistent bacteraemia, clinical worsening, increasing dyspnoea, and hypotension, requiring supplemental oxygen and vasopressor, leading to cardiac arrest and death. *Table 1* shows the timeline of events.

## DISCUSSION

Infection of an Amplatzer device can occur in two ways: in association with the procedure, involving microorganism inoculation, or by later haematogenous spread<sup>[4]</sup>. Endothelialisation of the device takes 6 months, with the risk of infective endocarditis reducing thereafter<sup>[4]</sup>. For this reason, the American Heart Association and the European Heart Society recommend 6 months of antibiotic prophylaxis after implantation to prevent early endocarditis<sup>[2, 3, 5]</sup>.

It has been reported that late endocarditis is related to partial endothelialisation, but its actual prevalence is not known<sup>[3, 4]</sup>. The risk factors for partial endothelialization have not been determined either, so there are no current recommendations on the administration of routine prophylaxis to prevent this late complication<sup>[3, 4, 6]</sup>.

Echocardiography has been shown to be an important method for the diagnosis of endocarditis, mainly in cases where the symptoms are not typical and when blood cultures are negative<sup>[3, 7]</sup>. Transoesophageal echocardiography is substantially better than transthoracic echocardiography for the detection of vegetations, with a positive predictive value of almost 100%<sup>[8]</sup>.

Day 1	Patient admitted because of 5 days of abdominal pain and vomiting suggesting intestinal obstruction, requiring immediate surgery
Day 2	Patient transferred to the intensive care unit after a right hemicolectomy, with a clinical diagnosis of adenocarcinoma with peritoneal carcinomatosis
Day 7	Patient discharged, after tolerating oral intake
Day 14	Patient readmitted with sudden right-sided weakness that resolved within a few minutes. Swelling of the left side of the neck, at the central venous catheter insertion site
Day 15	Patient found to be septic, with a deep vein jugular thrombus and blood cultures positive for methicillin-sensitive <i>Staphylococcus aureus</i> . Antibiotic therapy with oxacillin was started. Transoesophageal echocardiography showed a large right atrial vegetation associated with the Amplatzer device surface
Day 16	The patient refused surgical procedures, continuing with a conservative antibiotic regime
Day 21	The patient remained hospitalized with antibiotic treatment with persistent bacteraemia, with clinical worsening, leading to death

Table 1. Timeline of events

Cerebral embolism is the most common neurological complication of bacterial endocarditis [3]. The most effective way to prevent this occurring is through early diagnosis with the identification of high-risk patients [7]. Echocardiography provides the location and morphological characteristics of the vegetation, so the risk of future complications can be determined and an early surgical approach taken when necessary [1, 8].

There is no consensus on the prevention of late infection which, in our case, presented in a 67-year-old woman 3 years after Amplatzer septal occluder implantation and shortly after ICU hospitalization.

## CONCLUSION

Valve prostheses and implanted medical devices are the most common risk factors for infective endocarditis. The literature has described, as in the presented case, the appearance of late endocarditis involving the Amplatzer septal defect occluder device in adults, highlighting the need for surveillance in these patients. Transoesophageal echocardiography allows close anatomical study, with good image quality and resolution, so it should be considered in patients with an atrial septal defect closure device and suspected endocarditis. There are no guidelines on the prevention and management of late endocarditis infection involving the Amplatzer septal defect occluder device.

## REFERENCES

- Kim DJ, Shim CY, You SC, Lee SH, Hong GR. Late bacterial endocarditis and abscess formation after implantation of an Amplatzer septal occluder device. *Circulation* 2015;131(25):e536–538.
- Nguyen AK, Palafox BA, Starr JP, Gates RN, Berdjis F. Endocarditis and incomplete endothelialization 12 years after Amplatzer septal occluder deployment. *Texas Heart Inst J* 2016;43(3):227–231.
- Aruni B, Sharifian A, Eryazici P, Herrera CJ. Late bacterial endocarditis of an Amplatzer atrial septal device. *Indian Heart J* 2013;65(4):450–451.
- Białkowski J, Pawlak S, Banaszak P. Incomplete endothelialisation of an Amplatzer Septal Occluder device followed by meningitis and late acute bacterial endocarditis. *Cardiol Young* 2016;26(4):808–810.
- Habib G, Lancellotti P, Antunes MJ, Bongiorni MG, Casalta JP, del Zotti F, et al. 2015 ESC Guidelines for the management of infective endocarditis: The Task Force for the Management of Infective Endocarditis of the European Society of Cardiology (ESC). Endorsed by: European Association for Cardio-Thoracic Surgery (EACTS), the European Association of Nuclear Medicine (EANM). *Eur Heart J* 2015;36(44):3075–3123.
- Pristipino C, Sievert H, D'Ascenzo F, et al. European position paper on the management of patients with patent foramen ovale. General approach and left circulation thromboembolism [published correction appears in *Eur Heart J*. 2021 May 7;42(18):1807]. *Eur Heart J*. 2019;40(38):3182–3195.
- Anglada Pintado JC, Pérez Muñoz C, Vargas-Machuca JC, Valdivia Gutiérrez R, García de Arboleda F, Castro Fernández A, et al. Utilidad de la ecocardiografía transesofágica en la detección del riesgo embólico en un caso de endocarditis por *Staphylococcus aureus*. *Rev Esp Cardiol* 1997;50:283–286.
- Amedro P, Soulatges C, Fraise A. Infective endocarditis after device closure of atrial septal defects: case report and review of the literature. *Catheter Cardiovasc Interv* 2017;89(2):324–334.