

Psoriasis of the lips

M. NAPOLITANO, F. SUPPA, L. PANARIELLO, F. AYALA

SUMMARY: Psoriasis of the lips.

M. NAPOLITANO, F. SUPPA, L. PANARIELLO, F. AYALA

Psoriasis is a common chronic inflammatory skin disease, present in 1-3% of the world's population (1). It affects both sexes equally (2) and is characterized by various clinical features. Common sites of involvement are the extremities, trunk, scalp and nails. Although cutaneous lesions are generally sufficiently distinct to make a diagnosis, diagnostic difficulties can be found in cases of unusual involvement. Herein, we present a case of psoriasis involving the lips in a 20-year-old woman, who had a 2-months history of erythemosquamous lesions on her lips.

RIASSUNTO: Psoriasi delle labbra.

M. NAPOLITANO, F. SUPPA, L. PANARIELLO, F. AYALA

La psoriasi è una malattia cutanea infiammatoria cronica, presente nell'1-3% della popolazione mondiale (1). Si manifesta in entrambi i sessi con eguale frequenza (2). Si localizza principalmente agli arti, al tronco, al cuoio capelluto e alle unghie. Le lesioni cutanee sono in genere tipiche e non pongono difficoltà diagnostiche, se non nel caso del coinvolgimento di sedi insolite. Proponiamo un caso di psoriasi delle labbra in una donna di 20 anni, che presentava da circa 2 mesi lesioni eritemato-desquamative alle labbra e alla regione periorale.

KEY WORDS: Psoriasi - Labbra - Diagnosi.
Psoriasis - Lips - Diagnosis.

Case report

A 20-year-old woman presented to our clinic with a history of fissuring, cracking and scaling of her lips that had been present for about 2 months. The lesions started at the corners of the mouth and insidiously migrated towards the centre, involving both lips completely. She complained of a burning sensation and severe discomfort during eating and speaking. She had been prescribed various medications including emollient creams and topical steroids, with no effective improvement.

Dermatological examination revealed diffuse erythema, adherent silvery scales and fissuring on both upper and lower lips, extending beyond the vermilion border (Fig. 1). The oral mucous membranes, palate and ton-

gue appeared normal. Erythema and silvery scales were present also in the external portion of the ears (Fig. 2). She had characteristic psoriatic lesions on her elbows, knees and scalp. Routine laboratory tests were normal.

Histopathologic examination of a biopsy taken from the lip revealed features of parakeratosis with neutrophils (Munro's abscesses), psoriasiform acanthosis, and spongiform pustules. There was mild lymphocytic infiltrate noted in the upper dermis.

Discussion

Involvement of the lips and oral mucosa with psoriasis has been rarely recorded (3-5).

Because neither the clinical nor the histological changes are absolutely specific for psoriasis, diagnosis is difficult (6, 7). Many authors propose strict criteria for its diagnosis (5, 6, 8), which is best made when the clinical course of the oral lesions parallels that of the skin lesions and is supported by histological examination. Some

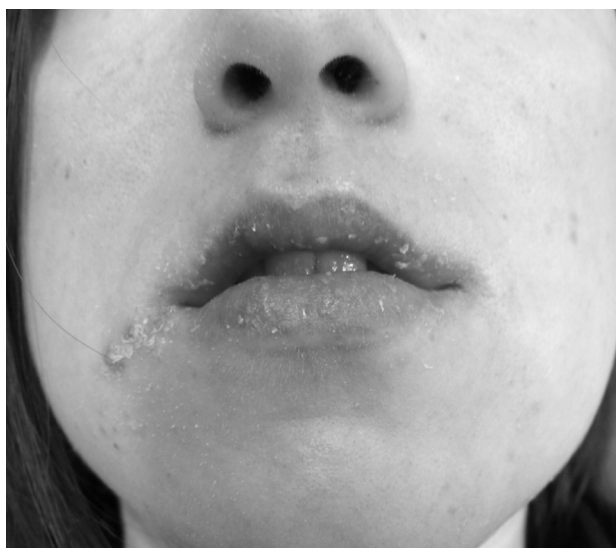


Fig. 1 - Diffuse erythema, adherent silvery scales and fissuring on both upper and lower lips.

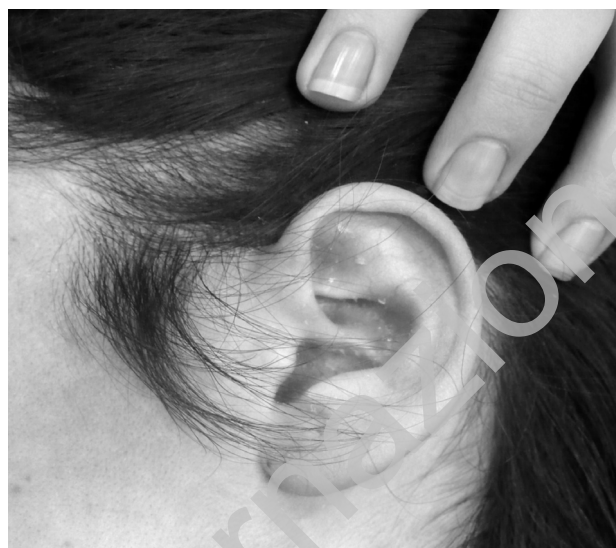

Fig. 2 - Erythema and silvery scales in the external portion of the ears.

additional criteria such as a positive family history and human leucocyte antigen (HLA) typing have also been considered important in supporting a diagnosis of oral psoriasis (5, 8).

Mild trauma or cheilitis can lead to psoriatic lesions on the lips (Koebner's phenomenon), especially in a genetically predisposed individual. It is usually resistant to treatment, probably because of the continuous daily activity of the lips (9).

Brenner et al. reported a case with lip psoriasis, which was triggered by protruding teeth. Their case did not clear with any type of dermatological treatments including topical corticosteroids and calcipotriol; however, the lesions on the lips completely resolved after replacement

of the protruding teeth by a non-irritating prosthesis (10).

Our case was treated with mometasone furoate cream twice a day for 3 weeks, then once a day for 1 week. The lesions had cleared by the end of the third week.

Psoriasis of the lips, which is more commonly reported in women, poses a serious cosmetic and psychological concern for patients. Occasionally it can be the sole presentation of psoriasis, preceding the appearance of typical psoriasis lesions by several years. Therefore, in chronic and relapsing xerosis and fissuration of the lips, which is resistant to low-potency topical steroid therapy, psoriasis should be included in the differential diagnosis (9).

References

1. Rahman MA, Fikree M. Perioral psoriasis. *J Eur Acad Dermatol Venereol* 2000; 14: 521-522.
2. Christophers E, Mrowietz U. Psoriasis. *Fitzpatrick's Dermatology in General Medicine*. 5th Ed; New York; McGraw-Hill, 1999: 495-520.
3. Baumal A, Kantor I, Sachs P. Psoriasis of the lips. *Arch Dermatol* 1961; 84: 185-187.
4. Klapholz L, Weinrauch L, Katz M. Perioral psoriasis. *Cutis* 1989; 43: 157-158.
5. Tosti A, Misciali C, Cameli N, Vincenzi C. Psoriasis of the lips. *Eur J Dermatol* 2001; 11: 589-590.
6. Bruce AJ, Rogers RS 3rd. Oral psoriasis. *Dermatol Clin* 2003; 21: 99-104.
7. Migliari DA, Penha SS, Marques MM, Matthews RW. Considerations on the diagnosis of oral psoriasis: a case report. *Med Oral* 2004; 9: 300-303.
8. Younai FS, Phelan JA. Oral mucositis with features of psoriasis: report of a case and review of the literature. *Oral Surg Oral Med Oral Pathol Oral Radiol Endod* 1997; 84: 61-67.
9. Ersoy-Evans S, Nuralina L, Erkin G, Ozkaya O. Psoriasis of the lips: a rare entity. *J Eur Acad Dermatol Venereol* 2007; 21: 104-143.
10. Brenner S, Lipitz R, Illie B, Krakowski A. Psoriasis of the lips: the unusual Köbner phenomenon caused by protruding upper teeth. *Dermatologica* 1992; 164: 413-416.

Corresponding author:

M. Napolitano, MD.

Department of Systematic Pathology, Section of Dermatology, University Federico II of Naples

Via S. Pansini, 5 - 80131 Naples - Italy

Tel. 0039 081 7462412 - Fax. 0039 081 7462442

E-mail: maddy.napolitano@gmail.com