

MICROSURGERY FLAP IN ENDODONTIC SURGERY: CASE REPORT

F. CECCHETTI*, S. RICCI**, G. DI GIORGIO***, C. PISACANE**, L. OTTRIA****

* DDS, Contract Researcher, PhD, Faculty of Medicine, S. Giovanni Calibita Fatebenefratelli Hospital, University of Rome "Tor Vergata" - Department of Periodontics

** DDS, University of Rome "Tor Vergata"; S. Giovanni Calibita Hospital Fatebenefratelli - Rome

*** Student of Dentistry

**** DDS, Researcher, Department of Odontostomatologic Science University of Rome "Tor Vergata"

Department of Periodontology, University of Rome "Tor Vergata", "S. Giovanni Calibita" Fatebenefratelli Hospital - Rome
Director and Chief: Prof. C. Arcuri

SUMMARY

Microsurgery flap in endodontic surgery: case report

In periodontal plastic surgery it is increasingly more evident the relevance of the protection of the gingival marginal anatomy through the realization of a conservative flap. Minimizing the recession of the treated tissue. A correct healing always needs to take into account the diameter and type of the suture and the time of removal from the wound.

Key words: papilla preservation, suture, parodontal aesthetic.

RIASSUNTO

Microchirurgia del lembo nell'endodonzia chirurgica: case report

Negli interventi di chirurgia plastica parodontale diviene sempre più evidente l'importanza del rispetto dell'anatomia del margine gengivale attraverso la realizzazione di un lembo conservativo, rendendo minimo il potenziale di recessione del tessuto trattato chirurgicamente. Per una corretta guarigione dei tessuti marginali risultano importanti altre due variabili: il tipo di sutura usato e il tempo di permanenza della sutura sulla ferita.

Parole chiave: preservazione della papilla, suture, estetica parodontale.

Introduction

Aesthetics has a primary role in dentistry. It is necessary to follow surgery's guidelines that respect scrupulously the soft tissues.

The essential requirement of dental surgery is repair or remove the tissues bringing them back as close as possible to the situation preceding the surgery; in order to achieve this result a correct preparation of the surgeon on the nature and physiology of the cut tissues is required. Before flap surgery the anatomic structure of the mucosa

needs to be assessed and a correct timing must be kept with the minimum possible trauma; for instance, when possible, a design of the flap allowing to avoid post-surgery recessions should be elected.

It is necessary, from an aesthetic and functional point of view, the preservation of the interdental papilla; in this context the studies of several Authors (1) revealed that the distance between the interdental contact point from the bone crest is a basic element influencing the correct healing of the papilla. When this distance is below 5mm the papilla closes the interproximal space in 100% of the cases, when instead the distance is 6mm

the closure takes place in 56% of the cases; eventually when the distance is of 7mm or above the closure can be observed in 27% of the cases. In addition it is important that the papilla is sustained by a bone structure, which from a complex network of blood vessels (Fig. 1) which should be traumatised as little as possible to allow a post-surgery healing.

Studies related to the blood irrigation of the alveolar mucosa (2) provided evidence of how supra-periosteal vessels run in parallel to the dental axe; from this observation a series of implications on the importance of the design of the flap and whether this can trail the anatomic structures mentioned above emerged.

■ Preliminary consideration

In relation to the importance of the design of the flap, specific information on the type of the flap are indispensable so that this could allow the most conservative level of the soft tissues of the area affected by surgery; it is therefore necessary to have high precision instruments for surgery.

The **semilunar flap** causes an excessive scratch of the blood vessels due to its horizontal incision; in addition the positioning of the suture in the apical area of the mucosa, rich of muscle fibers, makes the suture hard to stabilise and the constant tension the flap is exposed to generates aes-

thetically and functionally unacceptable scars (3).

The **triangular** and **trapezoidal flaps** demonstrated to be more conservative from a network vessels' point of view due to the introduction of vertical release incisions, although showing problems in marginal incisions with consequent recessions of the gingival margin.

The flap with papillary preservation consists in leaving the buccal portion adhering to the lingual one without separating the papilla, avoiding recessions of the latter. The papilla plays a fundamental role as a biological barrier to protect the periodontal ligament, the alveolar cement and bone but also for the aesthetic and phonetic functionalities (7, 8). This flap consists of two vertical release incisions coupled with a horizontal cut (Fig. 2) performed with two different surgery techniques, one of which is performed at the base of the papilla and the other in the cervical area of the tooth, intrasulcularly. The incisions are per-

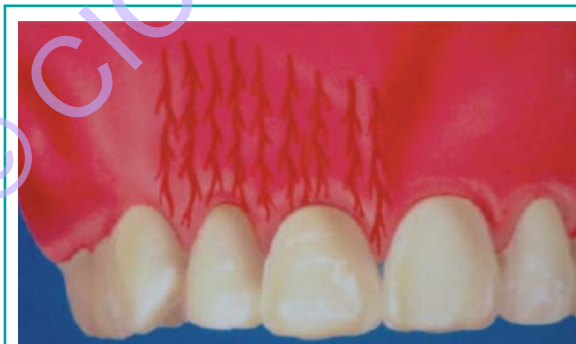

Figure 1
Supra-periosteal vessels.

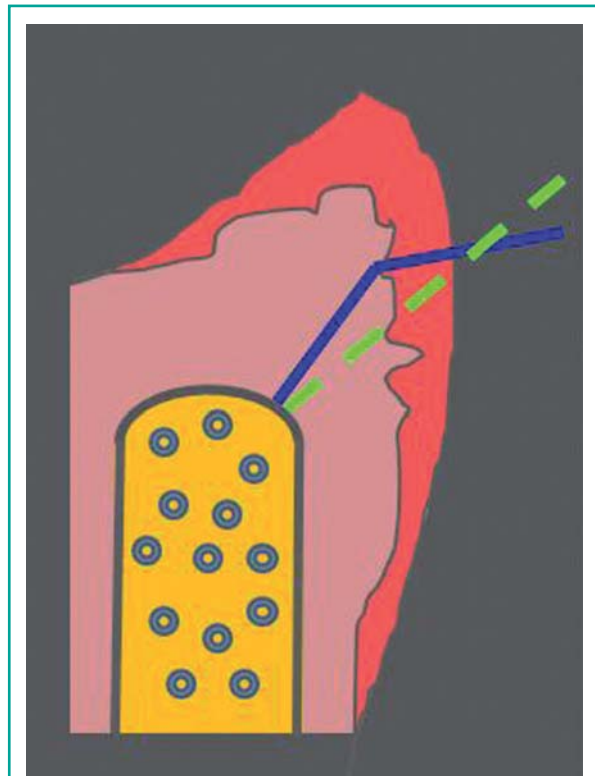


Figure 2
Incisions' design.

formed with a microsurgery blade 2.5mm long, fundamental size for a correct execution of the flap.

Operative procedure

The case discussed in this study is related to a patient who suffered a large lesion at the periapical level of the teeth 2.1 and 2.2, previously treated with endodontic therapy (Fig. 3); an apicectomy was necessary.

The biotype of the soft tissues of the patient can be considered as “thick” (Fig. 4) and the target is to reach the healing of the periapical lesion preserv-

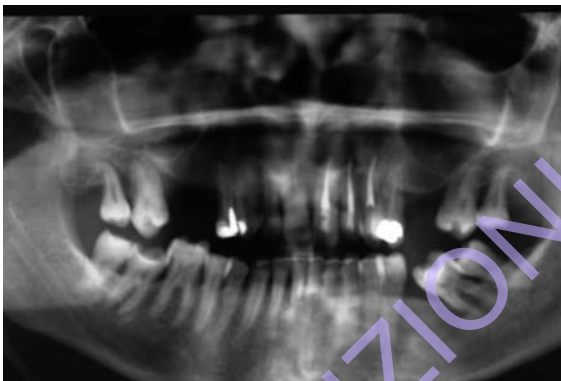

Figure 3
OPT with details of teeth 2.1 and 2.2.

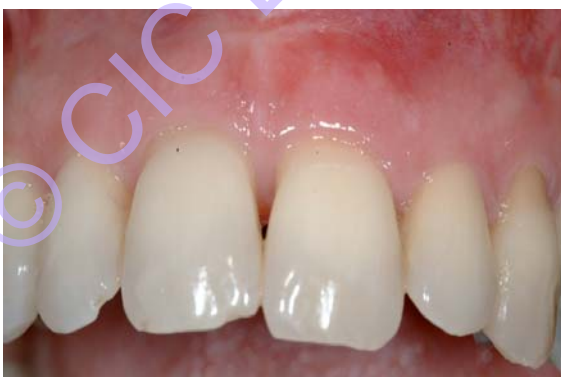

Figure 4
Starting situation.

ing at the same time the existing periodontal architecture.

It can be observed an existent scar deriving from a preceding attempt of apicectomy which did not lead to a successful outcome.

The surgery procedure consists in two vertical release incisions performed with two different techniques, one executed at the base of the papilla and the other in the cervical area of the tooth, intrasulcularly (Fig. 5).

The first incision at the base of the papilla must be performed in two phases: in the first phase the blade cut the tissues perpendicularly to the gingival margin with a 1.5mm depth, drawing a slightly curved line with apical convexity; in the second phase the blade follows the first incision and then from the base of the latter cuts with a vertical inclination through the crestal bone margin (Fig. 5).

The result of the flap is a split-thickness at the base of the papilla. A full-thickness mucoperiosteal flap is lifted in the apical zone. The split-thickness flap at the base of the papilla must be extracted with non traumatic surgery to obtain first intention healing.

The thickness of the tissue that must sustain the split-thickness flap is currently under study; if the tissue is too thin it could cause a scar, preceded by a necrosis of the epithelial tissue, instead if it is too thick it could impede the survival of the buccal papilla left in situ.

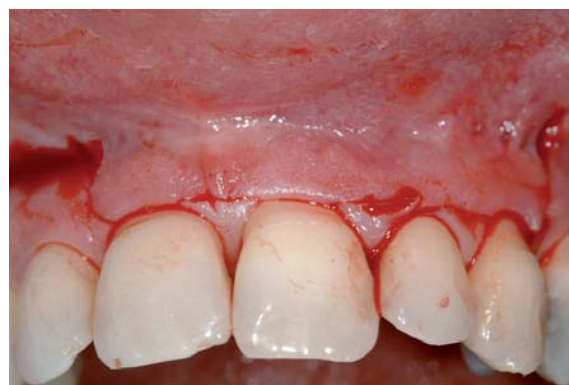

Figure 5
Incision.

Several studies (9) showed how a 1.5mm thickness for the flap at the base of the papilla allows to achieve excellent healings.

In periodontal plastic surgery it is increasingly more evident the relevance of the protection of the anatomy of the gingival margin through the realisation of a conservative flap, minimising the recession potential of the surgery treated tissue.

Post-surgery results are conditional on the contraction that the tissue is subject to during the surgery and the time length of the surgery which influences the quantity of the tissue perfusion (10, 11). It has been demonstrated the importance of not creating excessive tensions with the suture, particularly at the level of the flap margin. The tissual trauma can be reduced through the utilisation of microsurgery tools (12, 13).

During the surgical manoeuvres it is important to keep the periost intact, thus avoiding the connective cells to migrate to the underlying bone cavity during the osteoformative process.

Once created the flap, the surgical manoeuvre is performed (Figs 6, 7 and 8) with Piezo-Surgery device.

The retrograde filling was performed with Aureoseal (OGNA), material with moderate radiopacity to X-rays control.

According to different studies the type of suture must be selected with care, using a monofilament product or a multifilament covered by a synthetic polyamid sheath, reabsorbable in 7-10 days; such type of suture shows a reduction of the inflammation after 3 days. These sutures are less traumatic and less subject to bacterial colonisation compared to the non reabsorbable ones and more importantly proved to accumulate less bacterial plaque (14). It is fundamental to state that the inflammation

following the positioning of the suture is not reduced through antibiotics, this is due to the fact that bacteria are positioned at the level of the nodes of the suture knots; on this basis the choice of the suture wire inducing the lowest possible inflammation (15).

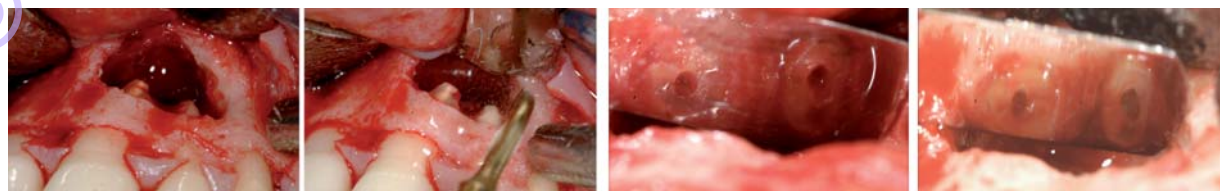
Microsurgery tends to increase the number of sutures to position the flaps, but at the same time reduces the size of their diameters, preferring 6-0 to 8-0 calibres.

After having performed the suture creating a minimal tension at the margin of the flap, it must be put attention to close the margins as much as possible to allow a good healing (Fig. 9).

There are no precise rules related to the number of sutures required to sustain a flap, but on a case by case basis the area of the suture and how much the area is subject to biting and phonetic forces must be evaluated.

High relevance is given nowadays to how long the suture has to be kept. Traditionally it was accepted that the timing had to be 7 days, although currently the scientific community has collected evidence indicating that better healings can be obtained by removing the suture not earlier than 48 hours but no later than four or five days (9, 16-18). It has been observed for instance that the epithelium around the suture starts developing on the third day and that it can overlap the suture after seven days; waiting for a week to remove the suture could cause an additional wound.

In addition, after three days an intense inflammatory response becomes visible; this is due to the suture material and the trauma caused by the positioning of the suture itself. An epithelial weft forms after two days although it becomes a real barrier in four days.



Figures 6, 7, 8

Surgical procedure performed with Piezo-Surgery.

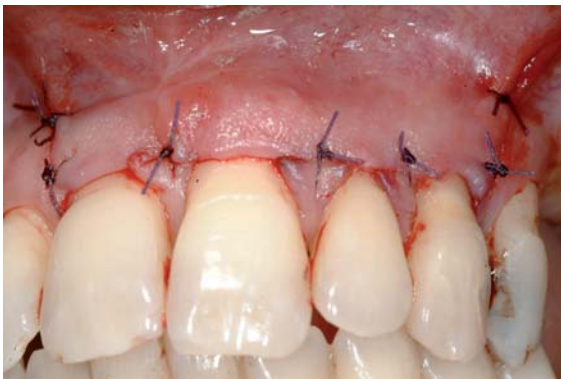

Figure 9
Suture.

The granulation layer positions the blood clot of thin fibrin between the flap and the cortical bone after four days, while the fibrous connective tissue replaces the granulation tissue after two weeks.

Following the observation of these data, the advantage of removal of the sutures before seven days becomes evident (Fig. 10).

Some Authors prefer to remove sutures after two or three days (10), while others wait for the fourth day as the collagen in the granulation tissue, that causes excessive tension to the wound, can be found only after three days.

However it must be stressed that the best timing for the removal of the suture is also determined by the gap between the two margins of the tissue; effectively their perfect matching and the ab-

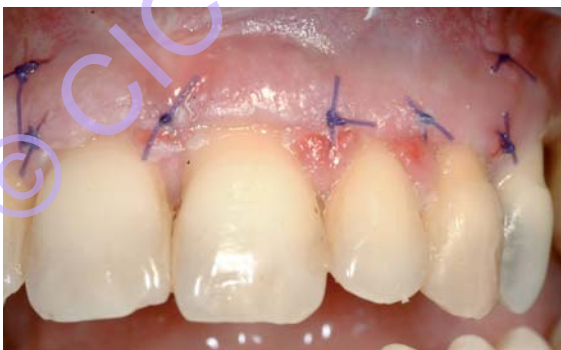

Figure 10
Healing after seven days.

sence of tensions are fundamental to obtain a successful healing and the consequent restoration of functionality and aesthetic.

Microsurgery has contributed to an improvement of the post-surgery results and the design of the flap is of primary importance, reducing gingival recession.

Oral mucosa is characterised by a cell turnover much faster than other tissues; among the causes endothelial growth factors like the VEGF, which can start the angiogenesis, has high relevance (19-21); in 24 hours a complex process characterised of several phases bringing to the healing of the treated tissue starts. Leukocytes and macrophages start moving in the blood toward the wound. Inflammation and repairing cells reach the area through the fibrin layers supported by the microvascularization of the flap and the underlying tissue (22).

It can be observed the strong regenerative potential of the epithelial tissue, consequent to the creation of an extracellular matrix formed by fibrin and fibronectin which allow the epithelial cells to migrate through the wound (23, 24).

In the process of re-epitheliation the integrins have a very important role; these surface proteins regulate the growth, diversification and the immune response functions of the cell by picking up information from the extracellular matrix through a receptor system of glycoprotein dimers and connecting through exchanges of information with the internal side of the cell (25, 26).

Under this action, the margins of the flap start migrating to cover the underlying connecting tissue.

The keratinocytes that cover the connective tissue are phagocytes able to enter the fibrin layer, remove it and generate, through integrins, new intracellular organelles, the hemidesmosomes, and eventually generate a new basal membrane.

Cells then organise themselves creating a layer of two to three cells called basal layer which is the germinative state of epithelial cells.

This phase lasts one to two days depending on the distance between the two flaps.

Approximately on the seventh day, the epithelium

matures in several layers while the corneal layer becomes evident (27, 28).

In contrast the healing of the connective tissue takes longer than the epithelial tissue; in fact the process develops through the generation of the granulation tissue, followed by a phase of reorganisation, contraction and eventual remodelling of the tissue.

The reparative process is managed by fibroblasts that are subject to a series of changes making them the main contributors to the healing process.

Different sources report that in the blood serum there are several growth factors able to bring changes in fibroblast populations, transforming them in cells capable of producing specific extracellular matrixes, reach the area to regenerate and diversify themselves into myofibroblasts (29). The contraction generated by the myofibroblasts cause the closing of the wound. The diversification of the myofibroblasts in cells capable of contraction takes place between the sixth and fifteenth day after the wound (30, 31).

In the healing phase, saliva and the crevicular fluid play a fundamental role, due to the specific PH, ions like calcium, magnesium and the capacity of humidifying the cells which could dehydrate (32).

The saliva also contains important growth elements produced by the salivary glands, such as the VEGF, involved in several aspects of the angiogenesis and the inflammatory process, the endothelial growth, the permeability and adhesion of leucocytes (33).

In addition there are bacteria in the saliva that, if present in not too high levels, attract macrophages and induce the release of cytochines; this causes an increase of blood around the wounded region and the generation of granulation tissue, thus reducing healing times.

For the correct healing some precaution avoid unpleasant scars in the area surgically treated:

The haematic flux of the flap should not be altered; the wound must be irrigated with saline solution to keep the tissue humid, trying to remove the fibrous parts which would impede the first intention healing.

Press the flap with a humid gauze to avoid an excessive coagulation between the margins of the flap and the cortical bone, which could cause the creation of a too thick fibrous layer (3, 11, 34). Eventually the flap must be repositioned so that it remains in the desired position passively, without being exposed to any tension, particularly at the level of its margins (35).

Conclusion

The objective of this study is to demonstrate how flap surgery to preserve the inter-dental papilla is an important operating tool to avoid unpleasant post-surgery gingival recessions (Figs 11, 12).

The improvement of incision techniques made the development of this technique focused on the preservation of soft tissues possible, guaranteeing a final result very similar to the physiological situation preceding surgery. Such a procedure is of simple execution assuming the operator is prepared on the physiology and the consistency of the tissues to cut into and works with specific microsurgery tools as 2.5mm blades. Eventually a correct healing always needs to take into account the suture wire and the time of removal of the suture from the wound. The residual scar post-surgery will be successively removed with gingival plastic surgery.

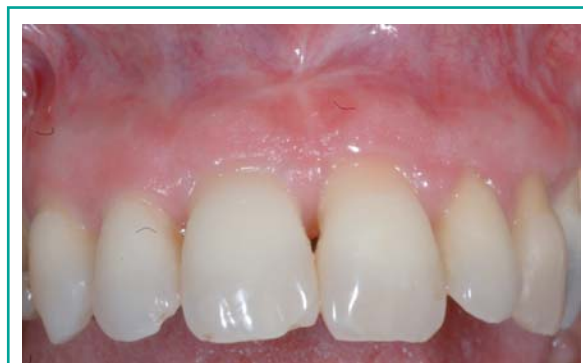

Figure 11
Healing after 1 year.

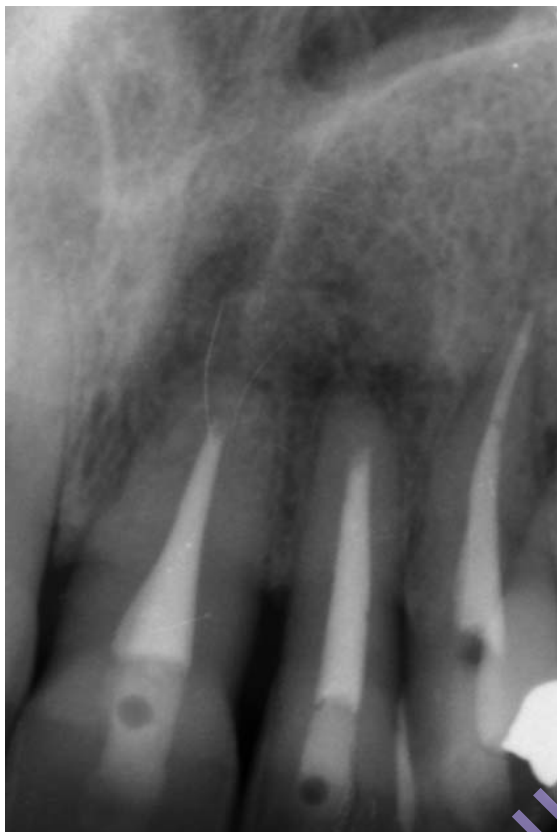

Figure 12
X-Ray control after 1 year. Aureoseal material (OGNA).

References

1. Tarnow D, Magner APF. The effect of the distance from the contact point to the crest of bone on the presence or absence of the interproximal dental papilla. *J Periodontol* 1992; 63: 995-996.
2. Gutmann JL, Harrison JW. Flap design and incisions. In: *Surgical Endodontics*. Boston: Blackwell 1991; 162-175.
3. Peters LB, Wesselink PR. Soft tissue management in endodontic surgery. *Dent Clin North Am* 1997; 41: 513-528.
4. Mörmann W, Meier C, Firestone A. Gingival blood circulation after experimental wounds in man. *J Clin Periodontol* 1979; 6: 417-424.
5. Gutmann JL, Harrison JW. Soft tissue management. In: *Surgical Endodontics*. Boston: Blackwell, 1991; 153-182.
6. Zimmermann U, Ebner J, Velvart P. Papilla healing following sulcular full thickness flap in endodontic surgery. *J Endod* 2001; 27: 219.
7. Caton J. Periodontal diagnosis and diagnostic aids. In: Nevins M, Becker W, Kornman KS, eds. *Proceedings of the World Workshop on Clinical Periodontology*. Chicago: The American Academy of Periodontology, 1989; 11-122.
8. Blatz MB, Hürzeler MB, Strub JR. Reconstruction of the lost interproximal papilla-presentation of surgical and nonsurgical approaches. *Int J Periodontics Restorative Dent* 1999; 19: 395-406.
9. Velvart P. Papilla base incision: a new approach to recession-free healing of the interdental papilla after endodontic surgery. *Int Endod J* 2002; 35: 453-460.
10. Harrison J, Jurosky K. Wound healing in the tissues of the periodontium following periradicular surgery. I. The incisional wound. *J Endod* 1991; 17: 425-435.
11. Mömann W, Ciancio SG. Blood supply of human gingiva following periodontal surgery. A fluorescein angiographic study. *J Periodontol* 1977; 48: 681-692.
12. Tibbetts LS, Shanelec D. Current status of periodontal microsurgery. *Curr Opin Periodontol* 1996; 3: 118-125.
13. Bathat O, Handelsman M. Periodontal reconstructive flaps – classification and surgical considerations. *Int J Periodontics Restorative Dent* 1991; 11: 480-487.
14. Selvig KA, Biagiotti GR, Leknes KN, Wikesjo UM. Oral tissue reactions to suture materials. *Int J Periodontics Restorative Dent* 1998; 18: 474-487.
15. Lilly GE, Armstrong JH, Salem JE, Cutcher JL. Reaction of oral tissues to suture materials. 2. *Oral Surg Oral Med Oral Pathol* 1968; 26: 592-599.
16. Selvig K, Torabinejad M. Wound healing after mucoperiosteal surgery in the cat. *J Endod* 1996; 22: 507-515.
17. Wirthlin MR, Hancock EB, Gaugler RW. The healing of atraumatic and traumatic incisions in the gingivae of monkeys. *J Periodontol* 1984; 55: 103-113.
18. Velvart P, Ebner-Zimmermann U, Ebner JP. Comparison of papilla healing following sulcularfull-thickness flap in endodontic surgery. *Int Endod J* 2003; 36: 653-659.
19. Scibba J, Waterhouse J, Meyer J. A fine structural comparison of the healing of incisional wounds of mucosa and skin. *J Oral Pathos* 1978; 7: 214-227.
20. Yang J et al. Salivary EGF regulates eosinophil-derived TGF alfa expression in hamster oral wounds. *Am J Physiol* 1996; 270: 191-202.
21. Szpaderska A, Walsh C, Steimberg M, DiPietro L. Distinct patterns of angiogenesis in oral and skin wounds. *J Dent Res* 2005; 84: 309-314.
22. Kon S, Caffesse RG, Castelli WA, Nasjleti CE. Revascularization following a combined gingival

- flap-split thickness flap procedure in monkeys. *J Periodontol* 1984; 55: 345- 351.
23. Clark RAF. Overview and general considerations . In: Clark RAF, ed. *The molecular and Cellular Biology of Wound Repair*. New York: Plenum Press, 1996; 3-50.
 24. Stenn K, De Palma L. Re-epithelization. In: Clark RAF, Hensen P, eds. *The Molecular and Cellular Biology of Wound Repair*. New York: Plenum Press, 1988.
 25. Aplin A, Howe A, Alamari S, Juliano R. Signal transduction and signal modulation by cell adhesion receptors: the role of integrins, cadherins immunoglobulin-cell adhesion molecules, and selectins. *Pharmacol Rev* 1998; 50: 197-263.
 26. Miyamoto S, Katz B, Lafrenie R, Yamada K. Fibronectin and integrins in cell adhesion, signalling, and morphogenesis. *Ann NY Acad Sci* 1998; 119-129.
 27. Green R, Usui M, Hart C, Ammons W, Narayanan A. Immunolocalization of platelet-derived growth factor alfa and beta chains and PDGF-a and b receptors in human gingival wounds. *J Periodontal Res* 1997; 32: 209-215.
 28. Woodley D. Reepithelialization. In: Clark RAF, ed. *The Molecular and Cellular Biology of Wound Repair*. New York: Plenum Press, 1996; 339-354.
 29. Hakkinen L, Uitto V-J, Larjava H. Cell biology of gingival wound healing. *Periodontol* 2000; 24: 127-152.
 30. Iyer V, Eisen MB, Ross DT, Schular G, Moore T, Lee JC, Trent JM, Hudson J Jr, Bogaski MS, Lashkari D, Shalon D, Botstein D, Brown PO. The transcriptional program in the response of human fibroblasts to serum. *Science* 1999; 283: 83-87.
 31. Darby I, Skalli O, Gabbiani G. alfa-smooth muscle actin is transiently expressed by myofibroblasts during experimental wound healing. *Lab Invest* 1990; 63: 21-29.
 32. Edgar W. Saliva: its secretion, composition and functions *Br Dent J* 1992; 172: 305-312.
 33. Dvorak H, Nagy J, Feng D, Brown L, Dvorak A. Vascular permeability factors/vascular endothelial growth factor and the significance of microvascular hyperpermeability in angiogenesis. *Curr Opin Microbiol Immunol* 1999; 237: 97-132.
 34. Gutmann JL, Harrison JW. Flap designs and incisions. In: *Surgical Endodontics*. St Louis: Ishijaku Euro-America, 1994; 162-175.
 35. Hurzeler MB, Weng D. Functional and esthetic outcome enhancement of periodontal surgery by application of plastic surgery principles. *Int J Periodontics Restorative Dent* 1999; 19: 36-43.

Correspondence to:

Dott. Francesco Cecchetti

Tel. +39 3392519800

E-mail: francesco.cecchetti@tin.it