

# MINI-INVASIVE IMPRESSION TECHNIQUES IN FIXED PROTHESIS: AN ALTERNATIVE TO TRADITIONAL PROCEDURES

M. BONINO\*, G. DE VICO\*\*, D. SPINELLI\*, I. CONTI\*\*\*,  
L. OTTRIA\*\*, A. BARLATTANI \*\*\*\*

\* Research Doctorate in Odontostomatologic Division, University of Study in Rome "Tor Vergata"

\*\* Sciences Odontostomatologic Department, University of Study in Rome "Tor Vergata"

\*\*\* Professional man, Rome

\*\*\*\* President of Degree Course in Dentistry, University of Study in Rome "Tor Vergata"

## SUMMARY

**Mini-invasive impression techniques in fixed prothesis: an alternative to traditional procedures.**

The object of our work is the illustration of an alternative technique in the impress survey in fixed prosthesis. This method conceived from Doctor Casartelli, allowed us to utilize this technology in the day-to-day activity eliminating also the anaesthetic use, so give the possibility to operate patients with anticoagulant therapy. Moreover the mini-invasive techniques allow a lowering recessions, best tolerability from the patients, less pain and postoperative inflammation, "restitutio ad integrum" of tissue without morphological modifications.

**Key words:** bridge guide, precision impression, provisional restoration.

## RIASSUNTO

**Tecnica di impronta mininvasiva in protesi fissa: un'alternativa alle procedure tradizionali.**

Lo scopo di questo lavoro è l'illustrazione di una tecnica alternativa nel rilevamento dell'impronta in protesi fissa. Una metodica mininvasiva e particolarmente rispettosa del parodonto che garantisce ugualmente un'affidabile precisione.

Tale procedura ideata dal Dott. Casartelli, ci ha permesso l'utilizzo di questa tecnologia nella pratica quotidiana eliminando anche l'impiego dell'anestetico, potendo così operare su pazienti trattati con terapie anticoagulanti. Inoltre l'atraumaticità della tecnica consente una diminuzione delle recessioni, migliore tollerabilità da parte del paziente, minor dolore e flogosi post-operatoria, "restitutio ad integrum" dei tessuti senza alterazioni morfologiche.

**Parole chiave:** ponte guida, impronte di precisione, temporizzazione.

## Introduction

The relief of anatomical information is a procedure of extreme importance in each prosthetic rehabilitation. In fact, besides representing the adjoining ring between orthodontic efficacy and medical efficacy, the relief taken influences in a complete way the creation of a congruent prosthetic product from both functional and aesthetic points of view. An incorrect dental impression in the product analysis treatment of material and the technical execution

thwarts the success of the on-going prosthetic rehabilitation. Naturally, there exists various types of material to relieve dental imprints and various techniques for their execution.

There are no universally superior techniques or just one type of material that allows the obtaining of always excellent results: besides personal preference, the various clinical situations will once in a while indicate what methods to use.

The indispensable condition that proceeds the relief of the dental impression, regardless of choice of material and technique, is an ideal paradontal situation, where there should be a preventive and accurate sea-

ting for oral hygiene, which will guarantee the maintenance of the obtained rehabilitative result in due course.

Beyond this, whatever the choice in the impression technique is represented by an adequate timing that, with respect to the margin of preparation and being produced with emergent profiles and correct contours, it will begin to condition the tissues and greatly facilitate the work at the moment of dental impression.

The objectives that are followed in the relief of anatomical information in the prosthetic procedure are essentially:

- Reproduce in a precise manner the entire dental surface prepared
- Clearly highlight the margin of final preparation, indispensable for the creation of a
- manufactured prosthetic
- Relief of a more or less extensive part of the preparation with the aim to favour the creation of a correct emergent profile
- Reproduce in negative form all other teeth present in the arch, gaps, and surrounding tissues of all teeth, pre-prepared or not.

A good reading of cervical and apical zone limits in the preparation provides a particular importance for a congruous preparation of the work model, to a degree that it allows the technician to execute a manufactured prosthetic with quality, both in the marginal closure and the emergent contour. All this determines the success of the restoration with respect to the paradontal health.

The possibility to read the cervical limits of a iuxta or under-the-gum preparation in work models depends exclusively on the accurate creation of an imprint, that extends to an apical level of such limits.

The obtaining of an over-extended impression is the fundamental principle for the respect of the emergent anatomy and contour during the creation of prosthetic products. To obtain this, it is necessary to add imprint material in the gum groove and it is indispensable that there exists a physical gap necessary for such material. If this gap is non-existent microscopically, it must be created through the technique of the retraction of paradontal tissues.

There exist diverse techniques of execution in books and dental medicine magazines that allow the addition of impression material beyond the apical limit of the preparation.

The methods actually in use for the vertical and horizontal retraction of the groove are:

- Techniques with retraction string (or elastic) (medicated or not)
- Techniques using copper rings (no longer in use)
- Mechanical dilation of the gum groove
- Gum courettage
- Techniques by means of electrical scalpel
- Techniques with bridge guides and modification of the same.

Unfortunately, the larger part of this is based on an approach that is rather aggressive and often determines paradontal suffering, that although slight, can jeopardize the success of the imprint itself, or of our rehabilitative therapy.

Every dental operator must in fact daily face the risk of gum recession that can occur during the preparation phase of the manufactured prosthetic, or successively of the positioning of the definite or final prosthesis in the oral cave with evident waste in time, economics and trust on the part of the patient.

Among the most frequent causes that come into play in this complication is having relieved anatomical information with aggressive and often times destructive techniques in the retraction of gum tissues.

Precisely for the demands of minimally invasive therapy, whether in the approach of a patient or for the paradontal tissues, diverse impression techniques have been developed, among which is the Ponti Guida Technique (Bridge Guide technique) created by Dr. Casartelli which has been modified in successive years. Such technique places itself in a different position with respect to other largely known techniques like the use of electrosurgery, the use of the copper ring, the use of retraction string (or elastic), the use of gum cutters; differently from such procedures in fact the Ponte Guida technique is placed as a primary objective, apart from the classic techniques described above, with the elimination of all traumatic techniques at the gum groove level without the provocation of gum-bleeding. In this technique for the relief of anatomical information, crowns or bridges

in autopolymerizing resin are used, called, in fact ponti guida or bridge guides.

The scope of this work is the presentation of a clinical case in a traditional fixed prosthesis in which the above mentioned technique of ponti guida or bridge guide was used, the analysis and the description of the various phases of such procedure, and the critical comparison with other techniques used in the daily practice described previously.

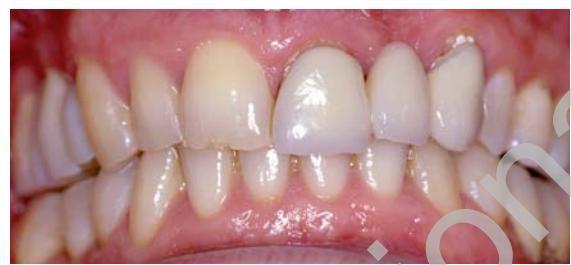## Clinical case

The patient, male, 40 years old presented himself to us with symptoms of gum inflammation and scarce aesthetics because of a fixed prosthesis rehabilitation done 10 years before, in the anterior seat, including elements 2.1 and 2.3, pillars of a traditional bridge bearing the missing 2.2 element (Fig. 1).

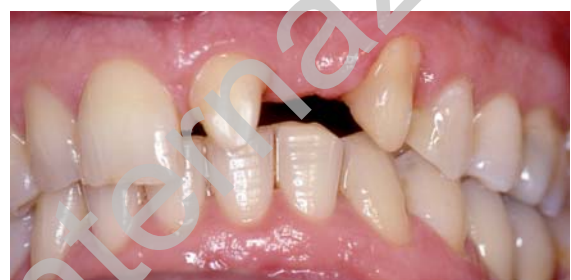In the clinical investigation, the patient did not declare any systematic or pathological symptoms, and in fact declared to be of good general oral health. The analysis of the fixed rehabilitation highlighted a grave imprecision both in terms of marginal closure and anatomic contour. Such a situation had determined the non-integration in the oral cavity the manufactured prosthesis, both in the functional and the aesthetic point of view. Besides that, the colour appeared to be incongruous, with questionable aesthetic results. The marginal imprecision had determined, throughout the years, the accumulation of dental plaque and the suffering of parodontal tissue, with significant inflammation and gum recession.

The ortopantomograph did not reveal any periapical tissue suffering of pillars 2.1 and 2.3, and showed a good state of health in the bone tissue support. In relation to the clinical information collected, in the data obtained from the clinical and instrumental exams and with the consent of the patient, it had been decided to remove the former fixed prosthesis, substituting it with one that would respect the anatomic limits and the aesthetic requests of the patient that guarantees the health of marginal parodontal tissues.

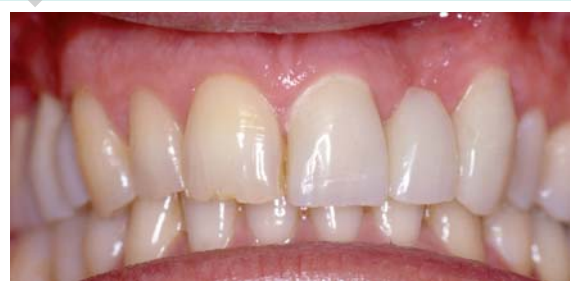After the removal of the old prosthesis, the first step was the preparation of the pillar elements, done with



**Figure 1**  
Evaluation of clinic case.



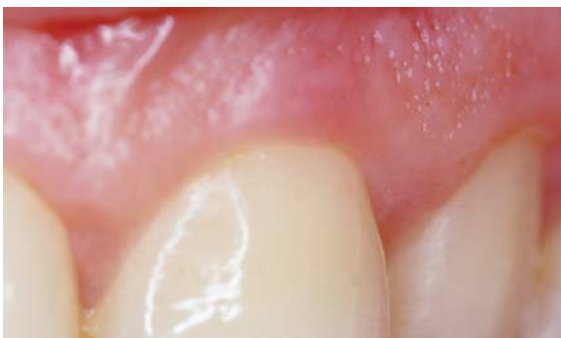**Figure 2**  
Preparation of elements ready to receive prosthesis.



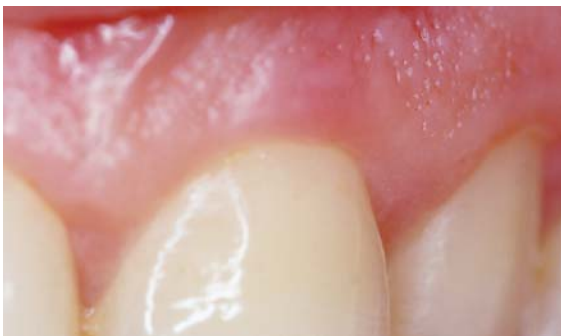**Figure 3**  
Immediate provisional restoration.

respect to marginal parodontal tissues and under a lens, with great care and careful precision in the margin of surface finishing of our preparation, and placing the same in the iuxtagengivale or under-the-gum location (Fig. 2). The next step was the timing through a temporary bridge in resin, obtained from the lab. Great attention and care were given to this step, scrupulously careful with the margin of closure and the emergent contour, because it was now acquired knowledge how this phase determines the conditioning and the maturation of marginal parodontal tissue, hence in the simplification and success of the successive rehabilitation phases (Fig. 3).

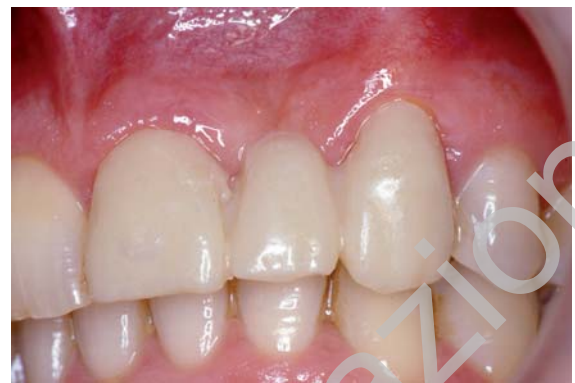After 21 days, with the healing and maturation of the



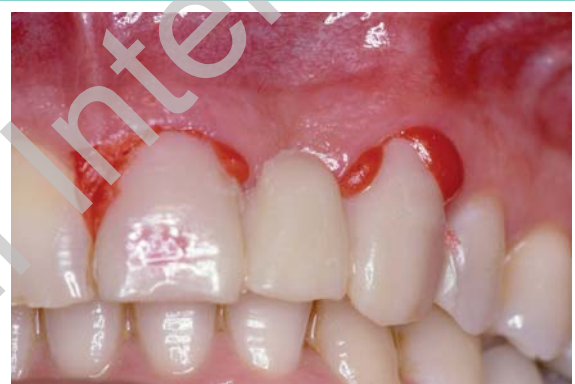**Figure 4**



**Figure 5**  
**Figures 4, 5**  
Tissue healing happened.



**Figure 6**  
Try of transfer execute in laboratory.



**Figure 7**  
Adaptation of bridge guide in Dura-Lay.

tissues, the patient returned to the clinic for the relief of anatomical information to be submitted to the orthodontic technician for the production of the final or definitive dental product (Figs. 4, 5).

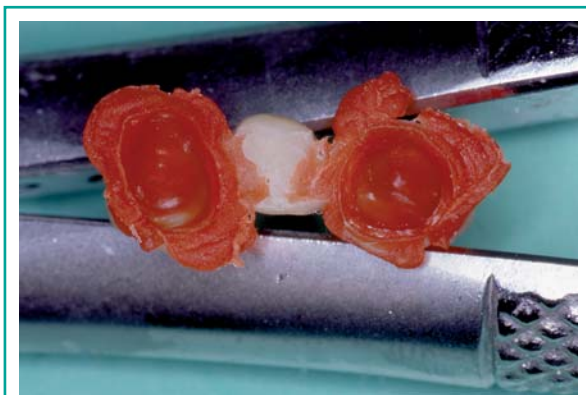
Precisely for the inflamed gum condition previously presented by the patient was a non-traumatic and mini-invasive impression technique chosen, known as the Ponti Guida or bridge guide. The transfer created in the laboratory was tried in the oral cavity, which was necessary for the execution of this particular technique (Fig. 6).

This transfer represents the bridge guide, that, adequately modified as explained later, has made it possible for the movement of marginal tissues and the relief of an imprint that respects all the necessary parameters.

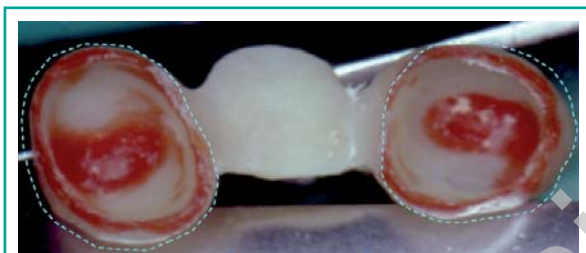The bridge guide obtained in the lab was lowered and adapted to the pillars present in the arch through the Pattern Ls resin (G:C:) The first step of this procedure was the internal surface boring of the transfer to create the space necessary for the resin. Next, the

internal surface of the bridge guide was wet with the monomer of the resin. At this point, the same material was injected inside the crowns of the bridge guide and then the bridge guide was inserted in the preparations, while asking the patient to close his mouth in PIM (Fig. 7). After 2 minutes, the bridge was removed, and after having injected more prepared resin way above the cervical margins, in the meantime the bridge was repositioned on the preparations for a minute.

The lowered bridge guide was then analyzed to highlight the presence and a good reading of all margins of our preparations (Fig. 8). The transfer was refinished and suitably emptied of the resin inside it to finally create the space or void necessary for the imprint material. This phase was executed without violating the marginal limits obtained with the red



**Figure 8**  
Bridge guide with new resin base.

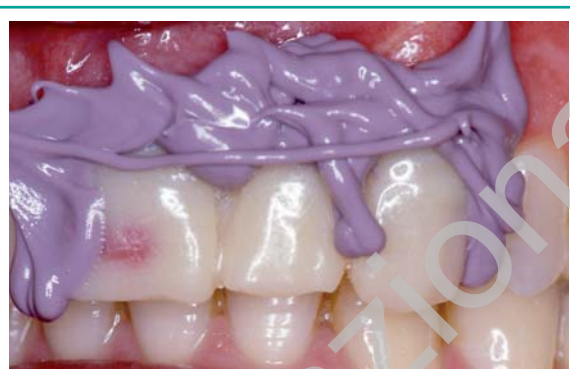

**Figure 9**  
The broken line indicate the reduction internal and the discard trim between the papillas space.

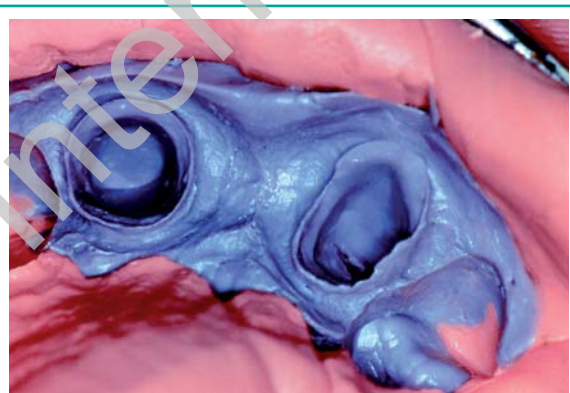
resin and leaving a slight horizontal and vertical over-contour, useful to obtain a light compression of marginal tissues, guaranteeing their movement at the moment of the relief of information.

An amount of the same resin was also left on the occlusal surfaces of the bridge guide, to obtain a back-push for the imprint material and to give stability in the highest intercuspid position. Such internal reduction of the bridge guide was also done, leaving some scrap at the level of the juncture of the pillar elements with that of the intermediate one to avoid having a compression of parodontal tissue right next to the papilla (Fig. 9). At this point, the internal surface was dampened with a silicone adhesive (VPS Tray Adhesive, 3M ESPE) and the bridge guide was repositioned on the elements with a silicone-type impression material of medium viscosity (Express Regular Body) inside it.

The patient was once again asked to close his mouth in PIM (Fig. 10). Next, the definitive or final imprint



**Figure 10**  
Positioning of transfer with medium viscose silicone.



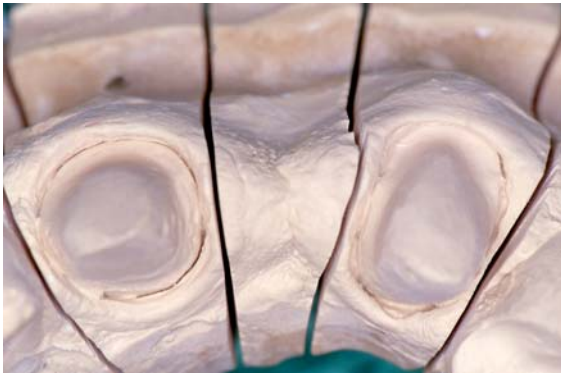
**Figure 11**  
Definitive impress where we point out preparation margin.

was taken of all the elements in the arch with the monofase technique without removing the bridge guide which still has the medium viscose material inside it (Fig. 11).

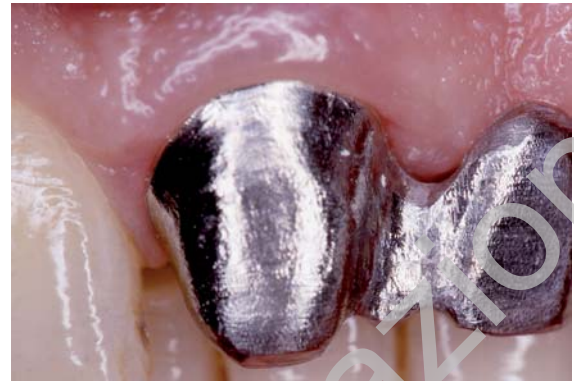
The definitive impression obtained with this technique demonstrates a very precise reading of the margins and an important over-extension beyond the apical limit of the margin of finishing of our preparations, without a single trauma for the marginal parodontal tissues, and without any gum-bleeding nor symptoms of pain during and after surgery.

With this technique, in fact, it had been possible to move (for compression) the marginal tissues, guaranteeing thus the accessibility to imprint material at the apical zone of the finishing margins.

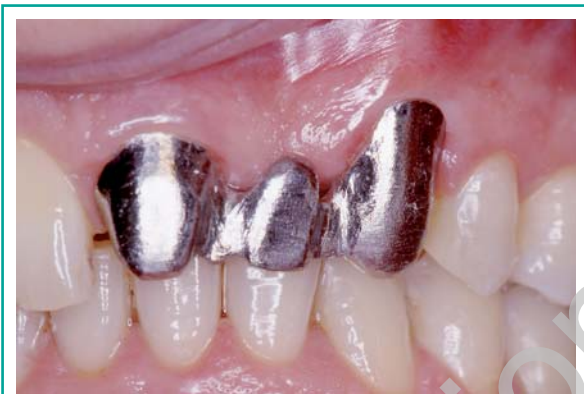To confirm the thesis that has just been exposed about the capacity of this technique to relieve information



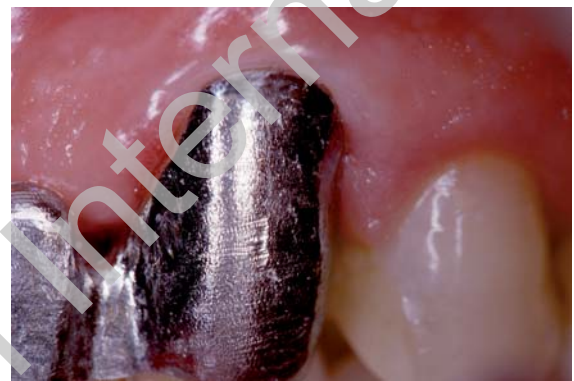**Figure 12**  
Just developed master model.



**Figure 14**



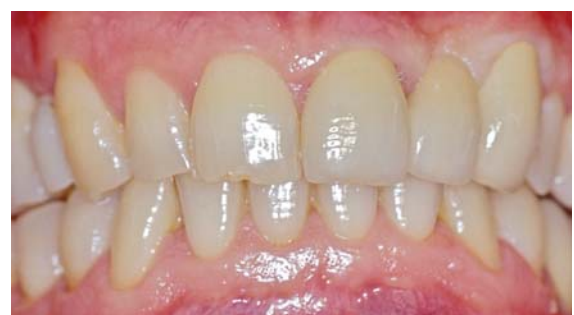**Figure 13**  
Structural trial.



**Figure 15**  
**Figures 14, 15**  
Particulars of marginal precision.

beyond the limits of preparations, one can observe the Figure (Fig. 12). That demonstrates how, as soon as the working model without any marginal finishing is developed, it is readily capable of observing contours and surplus preparations of margins in an excellent manner.

With this information, and with the relief of the right colour, the technician was able to create a hand-manufactured prosthetic of high precision and quality. Following the structural trial (Fig. 13), executed clinically a week after the relief of the imprint with the help of relief paste, Rx Endorale and the inspection of margins with a probe, it was possible to evaluate the efficacy of the marginal closure and the surrounding of the metallic structure (Figs. 14, 15), and so the work with the cementing of the definitive or final work in gold ceramic had been successively finished with great satisfaction on the parts of both pa-



**Figure 16**  
Definitive cementation of bridge.

tient and orthodontists.

The photographs after a month (Fig. 16) show the perfect integration of the hand-manufactured prosthetic in the oral cavity, with excellent aesthetics and functionality with a healthy margin of parodontal tissue obtained.

## Discussion

The most important problems which a dentist and/or orthodontist is confronted with during rehabilitation of fixed prostheses are represented by the precision of the margin of closure and the emergent contour of the crown. Only by respecting with great care and precision such determining anatomicals can one be guaranteed of excellent results in the long-term, and in this context the scrupulous care in the transfer of information represents the crucial moment, whether for the clinical work or the orthodontic technical work.

The possibility of reading in an excellent way, on the model of the preparations, the cervical margin and some millimetres of the over-preparations is a basic criteria in obtaining success in fixed prosthesis. All this represents the only way to transmit to the orthodontic technician the anatomical information necessary to guarantee a precise marginal adaptation and a correct contour of an emergent profile of each hand-manufactured prosthetic.

In the past, it was scientifically demonstrated how the most superficial part of the marginal gums, if found in a parodontal health condition, can easily be moved even by just the pressure done by a parodontal probe.

Thus, an ulterior consideration on the clinical plan is that it is possible to have a deformation and a non-traumatic movement in the marginal gums, and that such deformation can be obtained by compressing these tissues.

The operative procedure illustrated by us takes advantage of this precise concept: using the bridge guide properly lowered with imprint material inside it, it is possible to produce a compressive push against marginal gum tissue, distancing them from the zone of the cervical limit of our own preparation and rendering accessible the imprint material in that area and the apical area of the same. Preparing the technique that we have presented in this article, that renders the possibility of obtaining the information in a completely bloodless way, is of notable importance in various clinical situations, like for example in cases in which it is necessary to do mini-invasive clinical approaches without the need of localized anaesthesia,

or situations in which it is of prime importance the absolute respect for the parodontal zone, as in the case of patients with thin parodontal biotype or patients who have undergone previous parodontal surgery. In fact, the temporary distancing of the gingival margin in the horizontal or vertical sense in a non-traumatic manner is reflected on the certainty of not having successive consequential parodontal damages, because of fending off connective attacks and consequent recession.

The use of this technique does not necessarily need the use of any type of anaesthesia since during the operative procedure no pain is provoked, neither before nor after the surgery.

Another advantage of this technique is represented by the possibility to simultaneously relieve the imprint of intermaxillary ratios adapted in a fisiological manner in its stay in the oral cavity, eliminating an unpleasant step, otherwise imprecise, like that of the relief of the intermaxillary ratio through wax.

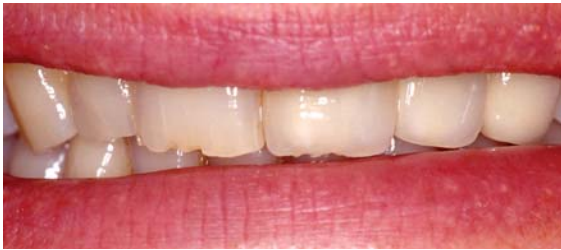## Conclusion

The objectives proposed by the Ponte Guida or Bridge Guide technique are essentially 3:

- Relieve the under-gum limits of the preparation without procuring damage, even minimum, to the parodontal support tissue.
- Register the PIM without the use of wax for occlusal recording
- Furnish the technician with the indications of the occlusal morphology to be conferred on the definite or final prosthesis.

Regardless of the fact that this technique can be used in any given situation not presenting contraindications and representing an elegant and less aggressive approach towards the patient, we find particular clinical indications in:

- Mini-invasive procedure in anxious patients
- Procedures that do not need localized anaesthesia
- Absolute respect for parodontal tissue in case of thin parodontal biotype
- Patients who have undergone previous parodontal surgery
- Patients with systemic problems (in particular, pa-



**Figure 17**  
Ultimate case.

tients with the risk of endocardiac heartbeats). Believing that the principle form-function is a biological reality and that there exists no function outside of the anatomy, we think that only the knowledge, the respect, the perfect transmission of information and the reproduction of a mechanically correct anatomy can assure a function that is biologically and fisiologically exact. Being able to propose in this field ways and techniques that are minimally invasive, we think it is the duty of every doctor to know them and apply them in all situations when they are needed (Fig. 17).

## References

- Gherlone E. L' impronta in protesi dentaria. Elsevier – Masson, II Edizione, 2005.
- Martignoni M, Schöenberger A. Precisione e contorno nella ricostruzione protesica. Edizione Quintessenza Biblioteca, 1993.
- Lindhe J, Karring T, Lang NP. Parodontologia clinica e odontoiatria implantare. Edi-ermes IV edizione, 2006.
- Silness J. Periodontal conditions in patients treated with dental bridges. Journal of Periodontal Research 1970;5:60–8.
- Azzi R, Tsao TP, Carranza Jr FA, Kenney EB. Comparative study of gingival retraction methods. The Journal of Prosthetic Dentistry 1983;50:561–5.
- Bennani V, Schwass D, Chandler N. Gingival Retraction Techniques for Implants Versus Teeth: current status. J Am Dent Assoc, 2008 Vol 139, No 10, 1354-1363.
- Wöstmann B, Rehmann P, Trost D and Balkenhol M. Effect of different retraction and impression techniques on the marginal fit of crowns. J Dent 2008 Jul;36(7):508-12. Epub 2008 May 13.
- Baharav H, Kupersmidt I, Laufer BZ, Cardash HS. The effect of sulcular width on the linear accuracy of impression materials in the presence of an undercut. Int J Prosthodont 2004;17(5):585–589.
- Laufer BZ, Baharav H, Langer Y, Cardash HS. The closure of the gingival crevice following gingival retraction for impression making. J Oral Rehabil 1997;24(9):629–635.
- Donovan TE, Chee WW. Current concepts in gingival displacement. Dent Clin North Am 2004;48(2): 433–444.
- Shimono M, Ishikawa T, Enokiya Y, et al. Biological characteristics of the junctional epithelium. J Electron Microsc (Tokyo) 2003;52(6): 627–639.
- Armand S. Access to the cervical margin in fixed prosthetics. Les Cahiers de l'ADF 2000;3(7):18–23.
- Wassell RW, Barker D, Walls AW. Crowns and other extra-coronal restorations: impression materials and technique. Br Dent J 2002;192(12):679–684, 687–690.
- Livaditis GJ. Comparison of the new matrix system with traditional fixed prosthodontic impression procedures. J Prosthet Dent 1998;79(2): 200–207.
- Cloyd S, Puri S. Using the double-cord packing technique of tissue retraction for making crown impressions. Dent Today 1999;18(1):54–59.
- Hansen PA, Tira DE, Barlow J. Current methods of finish-line exposure by practicing prosthodontists. J Prosthodont 1999;8(3): 163–170.
- Parker S. The use of lasers in fixed prosthodontics. Dent Clin North Am 2004;48(4):971–998.
- Gherlone EF, Maiorana C, Grassi RF, Ciancaglini R, Cattoni F. The use of 980-nm diode and 1064-nm Nd:YAG laser for gingival retraction in fixed prostheses. J Oral Laser Applications 2004;4(3): 183–190.
- Wilhelmsen NR, Ramfjord SP, Blankenship JR. Effects of electrosurgery on the gingival attachment in rhesus monkeys. J Periodontol 1976;47(3):160–170.
- Brady WF. Periodontal and restorative considerations in rotary gingival curettage. JADA 1982;105(2):231–236.
- Kamansky FW, Tempel TR, Post AC. Gingival tissue response to rotary curettage. J Prosthet Dent 1984; 52(3):380–383.
- Polat NT, Ozdemir AK, Turgut M. Effects of gingival retraction materials on gingival blood flow. Int J Prosthodont 2007;20(1):57–62.
- Donovan TE, Gandara BK, Nemetz H. Review and survey of medicaments used with gingival retraction cords. J Prosthet Dent 1985;53(4):525–531.
- Csillag M, Nyiri G, Vag J, Fazekas A. Dose-related effects of epinephrine on human gingival blood flow and crevicular fluid production used as a soaking solution for chemo-mechanical tissue retraction. J Prosthet Dent 2007;97(1):6–11.
- Jokstad A. Clinical trial of gingival retraction cords. J Prosthet Dent 1999;81(3):258–261.
- Abrano JC, Spatakis S. Impression techniques for preparations with shoulders. J Prosthet Dent 1984 Jan; 51(1):42-5.
- Casartelli I. Modified fixed denture impression technique. Attual Dent. 1988 May 15;4(19):12-5, 17-9, 21-4.



28. Dragoo MR, Williams GB. Periodontal tissue reactions to restorative procedures. *Int J Periodontics Restorative Dent* 1981 Apr;1(1):8-23.
29. Dragoo MR, Williams GB. Periodontal tissue reactions to restorative procedures, part II. *Int J Periodontics Restorative Dent* 1982;2(2):34-45.
30. Lehmann KM. Impression materials, impression technique, and model preparation for crowns and bridges—a literature review. *ZWR* 1987 Oct;96(10):914, 916-7.
31. Purton DG. Impression materials and gingival retraction techniques for crowns and bridges. *N Z Dent J.* 1988 Jul;84(377):80-3.
32. Pelzner RB, Kempler D, Stark MM, Lum LB, Nicholson RJ, Soelberg KB. Human blood pressure and pulse rate response to racemic epinephrine retraction cord. *J Prosthet Dent* 1978;39(3):287-292.
33. Harrison JD. Effect of retraction materials on the gingival sulcus epithelium. *J Prosthet Dent* 1961;11(3):514-521.
34. Bonino M, De Vico G, Bonino F, Barlattani A. Implant therapy in esthetic zone: temporary solution with custom impression transfert. *Implantology* 2007; 4: 17-23, Quintessenza Edizioni.

---

*Correspondence to:*

Dott. Mario Bonino

Tel. 06/86214508

E mail: mariobonino@libero.it