

Relapsing-remitting behavioural variant of frontotemporal dementia in a bipolar patient

Florence Vorspan, MD, PhD^a

Maxime Bertoux, PhD^b

Clara Brichant-Petitjean, MD^a

Bruno Dubois, MD, PhD^b

Jean-Pierre Lépine, MD, PhD^a

^a Psychiatry Department, Fernand Widal Hospital, Assistance Publique - Hôpitaux de Paris, France

^b Neurology Federation, Pitié-Salpêtrière Hospital, Assistance Publique - Hôpitaux de Paris, France

Corresponding author: Florence Vorspan
Assistance Publique - Hôpitaux de Paris
Hôpital Fernand Widal, Service de Psychiatrie
200 rue du Faubourg Saint Denis
75010 Paris, France
E-mail: florence.vorspan@lrb.aphp.fr

Summary

We report the case of a bipolar I patient who was diagnosed with frontotemporal dementia at the age of 54 during a manic episode. Her neurological state improved when this episode ended. Each subsequent thymic relapse was associated with cognitive deficits which subsided when the patient became euthymic, even though SPECT continued to show the same frontal hypoperfusion. We here discuss the hypothesis that the cognitive reserve of this patient, a former journalist, may, except during her mood episodes, have provided her with sufficient resources to meet her life demands despite her underlying neurological disorder.

KEY WORDS: bipolar disorder, cognitive impairment, cognitive reserve, dementia, frontotemporal lobar degeneration, neuropsychological assessment

Introduction

Frontotemporal lobar degeneration (FTLD) shows highly heterogeneous phenotypic presentations; three main variants have been described: a behavioural variant (bvFTD), progressive non-fluent aphasia, and semantic dementia (1).

The behavioural variant is a clinical syndrome resulting from neuronal dysfunction that predominates in the frontal and temporal lobes. The symptoms are mainly characterised by behavioural and personality changes that include disinhibition, impaired social interaction, apathy, loss of empathy, stereotyped behaviours, hyperorality and dietary changes (2).

Although brain imaging and neuropsychological assessment may not be diagnostically suggestive in the early stages of the disease, patients rapidly present frontotemporal atrophy or hypoperfusion, with concomitant impairments in social and emotional cognition and exec-

utive functioning. The diagnosis can be difficult since the onset is quite insidious. It has been shown that cognitive reserve is linked to better cognitive performance (3) and to brain perfusion in bvFTD (4). What, in clinical terms, we call age of onset of FTLT corresponds to the intersection of two lines: an ascending line representing cognitive impairment due to the underlying molecular disease processes, and a horizontal line representing the cognitive reserve accumulated through lifetime educational, occupational and leisure activities. We advocate the possibility that cognitive reserve may account for a part of the variability in age of onset of FTLT dementia, even in young-onset cases in whom the genetic burden is high and the underlying pathological process aggressive. To illustrate this, we report the case of a highly educated woman diagnosed with FTLT at the age of 54 during an agitated manic episode. This patient displayed a relapsing-remitting disease course: indeed, her cognitive deficits subsided during her euthymic phases.

Case report

The patient had no previous neurological history and no family history of dementia or psychiatric disorders. She was admitted to the emergency ward at the age of 54 during an agitated manic episode. Her history was irrelevant except for two major depressive episodes. The patient presented behavioural symptoms that were unexpected in a manic episode. Apart from behavioural disinhibition, she displayed perseverative behaviours, distractibility, press of speech, echolalia, echopraxia, amnesia and hyperorality, with both hyperphagia and potomania. She thus fulfilled the Lund and Manchester criteria for a diagnosis of bvFTD (5,6), presenting three of the core diagnostic features (impairment in regulation of personal conduct, emotional blunting, loss of insight) as well as supportive diagnostic features (behavioural traits such as distractibility, hyperorality, perseverative behaviours, press of speech, and echolalia). CT scan confirmed the presence of cortical atrophy. Over the next two months, full neuropsychological testing was performed – general cognitive efficiency, inhibition, planning, concept generation and working memory functions remained impaired after the psychiatric symptoms improved –, showing a dysexecutive profile. SPECT imaging showed an anterior temporal and frontal lobe hypoperfusion (Fig. 1, over), and T1 MRI showed frontal atrophy, confirming the diagnosis (Fig. 2, over). The patient was diagnosed during a multidisciplinary clinical meeting by FTD experts. According to the recently revised international guidelines (7), the patient presented “probable” bvFTD, since she presented most of the clinically discriminating features (behavioural disinhibition, perseverative behaviours, hyperorality, executive deficits on neuropsychological testing) and also exhibited signifi-

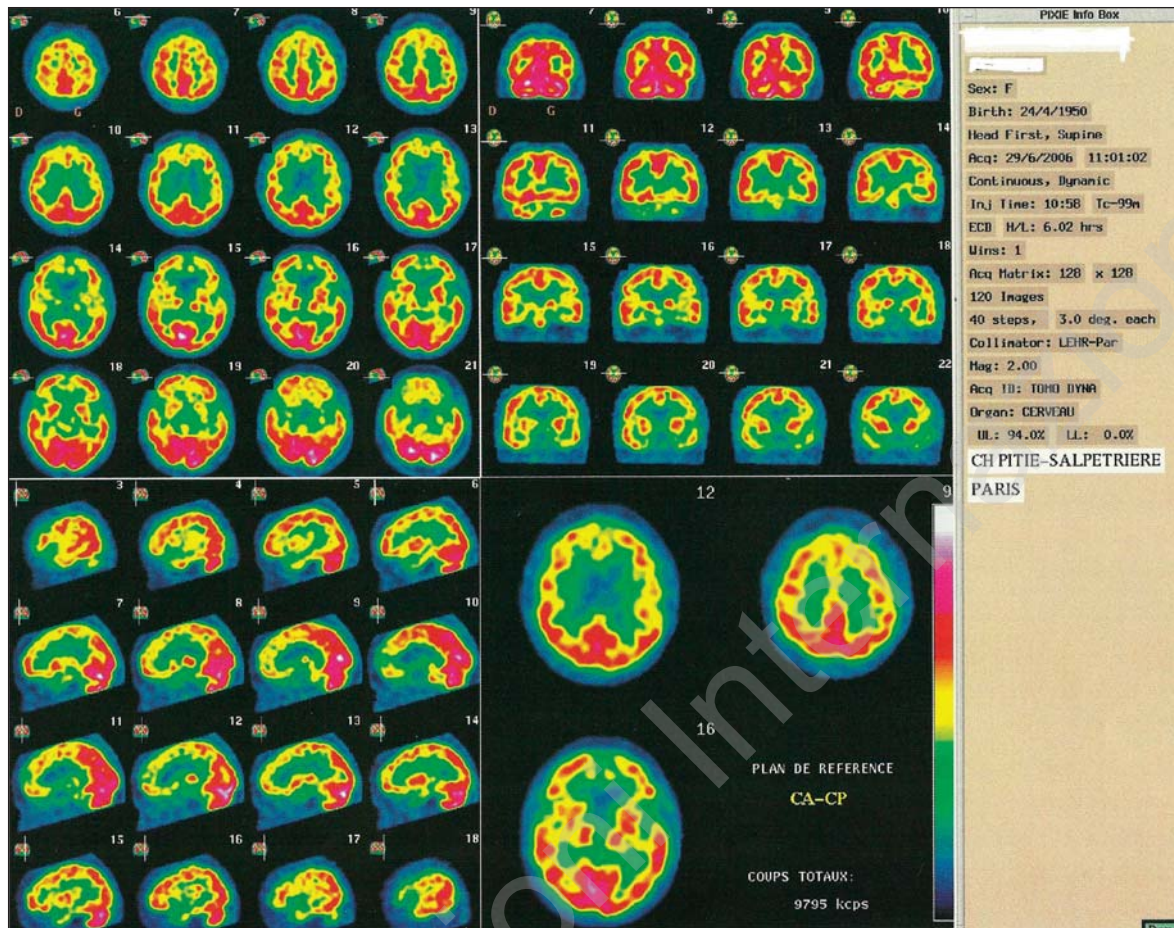


Figure 1 - SPECT images.

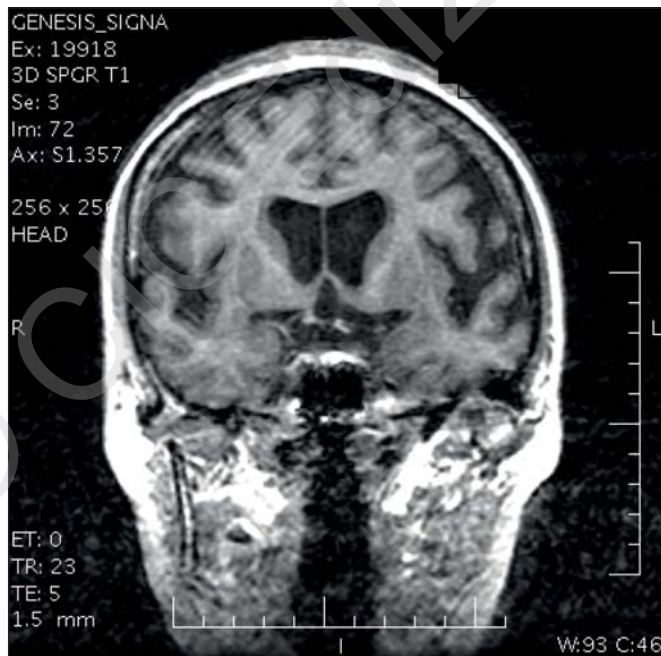


Figure 2 - MRI performed in 2006 showing mild frontal and temporal cortical atrophy.

cant functional decline and characteristic neuroimaging. Blood and cerebrospinal fluid tests were not contributive: all other causes of dementia were thus eliminated.

Pharmacological treatment of manic symptoms (valproate and cyamemazine) was started and the patient showed improvements in some cognitive symptoms. Within three months, her mood had stabilised but the cognitive symptoms failed to normalise completely: she improved only on some of the neuropsychological tests, whereas her performance on others remained below normal values (Table 1, last column). The following year, she had a severe depressive episode (Table 1, fourth column) characterised by non-typical symptoms mixed with neurological symptoms (absence of sadness, apathy, mutism without negativism or other catatonic features, and complete anosognosia). Despite pharmacological interventions (including clomipramine) and psychiatric hospitalisation, her state worsened. The severity of her mutism, apathy and psychomotor retardation was such that she required the help of caregivers for eating, washing and moving from the bed to the couch. After three months in this declined state, which we thought would remain

permanent, we felt that the patient needed to be institutionalised. However, four months after this, she experienced a sudden mood switch: in her words, she “woke up”. Her state progressively improved and for the next six months she required caregivers for only some of the time during the day.

It is now seven years since this patient was diagnosed with bvFTD. She is no longer treated with mood stabilisers and for most of the time since 2007 she has remained euthymic and free of neurological clinical symptoms, reporting only two transient mood episodes, one manic and the other depressive, and one isolated confusional state associated with fever during a bout of flu. The thymic episodes, which were both associated with confusion and cognitive deficits (one of them documented in Table 1, column 3), lasted only a few days, subsiding without any changes to her medication. She has now been living alone for seven years, travelling on her own to see her family, looking after her grandchildren during summer holidays, and managing her money by herself. At the most recent evaluation, neuropsychological tests showed subtle executive symptoms, with impaired working memory and attention, as well as mild impulsivity and reduced mental flexibility (Table 1, columns 1 and 2). Brain imaging still shows the same frontal dysfunctions, with no progression of the atrophy.

Discussion

This atypical case shows an association of probable bvFTD and bipolar disorder. The link between the two conditions has rarely been investigated, although some authors have reported cases of bvFTD diagnosed in pa-

tients with a premorbid history of bipolar disorder (8-10). Although the final diagnosis requires post-mortem examination, the psychiatric symptoms in this patient were always atypical and mixed with neurological symptoms. This patient’s bvFTD was diagnosed during a multidisciplinary clinical meeting by FTD experts.

Here, we hypothesise that the cognitive reserve of this patient, a former journalist with a high level of education, is, except during mood episodes, sufficient for her to meet her life demands despite her underlying neurological disorder. Clinically, bipolar patients usually display mild cognitive symptoms during manic or depressive episodes and show attentional, memory and executive deficits on neuropsychological testing (11). These symptoms may express acute functional changes in the brain, although the precise pathophysiology is unknown. In this particular patient with bvFTD, the transient cognitive symptoms associated with mood episodes were of particular severity and unmasked the neurological symptoms, explaining the “remitting-relapsing” course of the bvFTD. Brain imaging, the best reflection of the underlying pathological process (12), showed stable lesions, and confirmed the diagnosis. This patient has already survived longer than expected, given that the median survival in bvFTD is around 4 to 5 years after diagnosis (13). Her only current treatment is mirtazapine as a relapse prevention treatment.

Recent findings suggest that patients with bvFTD differ in their disease progression (14): a non-progressive form of bvFTD, or phenocopy, has recently been described (15). bvFTD phenocopy patients follow a more benign course than other bvFTD patients, with less neuropsychological impairment (sometimes a normal or sub-normal cognitive profile), greater daily-living auton-

Table 1 - Neuropsychological assessments.

	Euthymia 2012	Euthymia Nov 2009	Depression Dec 2008	Depression June 2006	Euthymia Feb 2006	Manic episode June 2005
MMSE	28	30	30	20*	29	
MATTIS		143/144	136/144			
Digit span forward	5*	7	7	5*	8	6*
Digit span backward	4	2*	4	2*	7	5
FCSR-IR	16	16	16	16	16	16
Encoding	16	14	16	14	15	14
Free recall	38	25	39	8*	31	30
Cued recall	46	48	48	38	44	45
VF Phonological	13	17	14	8*	8*	15
VF Semantic	26	20	21	3*	26	16
Praxis	50/50	50/50	49/50	41/50	50/50	
FAB	18	18	16	11*	17	
Rey figure	27/36	31/36	34/36		20/36*	25.5/36*
WCST		20/20	20/20			
VP & Palm Tree Test		40/40	40/40			
Arithmetic		11/12	12/12			
Deno100	80/80	93/100	93/100	78/100		

Symbols and abbreviations: *=Values below age- and education-corrected normative data; MMSE=Mini Mental State Examination; MATTIS=Mattis Dementia Rating Scale; FCSR-IR=Free and Cued Selective Reminding Test with Immediate Recall; VF=verbal fluency; FAB=Frontal Assessment Battery; WCST=Wisconsin Card Sorting Test; VP=Verbal Pyramid; Deno100=picture naming test.

omy, and a normal profile or mild atrophy on MRI. These patients also have a longer life expectancy (13). It is probable that the case we discussed here is a non-progressive form of bvFTD. We can hypothesize that the diagnosis would have been made later in the absence of the co-occurring mood disorder.

References

1. Mioshi E, Hodges JR. Rate of change of functional abilities in frontotemporal dementia. *Dement Geriatr Cogn Disord* 2009;28:419-426
2. Piguet O, Hornberger M, Mioshi E, Hodges JR. Behavioural-variant frontotemporal dementia: diagnosis, clinical staging, and management. *Lancet Neurol* 2011;10:162-172
3. Fairjones SE, Vuletic EJ, Pestell C, Panegyres PK. Exploring the role of cognitive reserve in early-onset dementia. *Am J Alzheimers Dis Other Demen* 2011;26:139-144
4. Borroni B, Premi E, Agosti, C et al. Revisiting brain reserve hypothesis in frontotemporal dementia: evidence from a brain perfusion study. *Dement Geriatr Cogn Disord* 2009; 28:130-135
5. The Lund and Manchester Groups. Clinical and neuropathological criteria for frontotemporal dementia. *J Neurol Neurosurg Psychiatry* 1994;57:416-418
6. Neary D, Snowden JS, Gustafson L et al. Frontotemporal lobar degeneration: a consensus on clinical diagnostic criteria. *Neurology* 1998;51:1546-1554
7. Rascovsky K, Hodges JR, Knopman D et al. Sensitivity of revised diagnostic criteria for the behavioural variant of frontotemporal dementia. *Brain* 2011;134:2456-2477
8. Cerami C, Marcone A, Galimberti D, Villa C, Scarpini E, Cappa SF. From genotype to phenotype: two cases of genetic frontotemporal lobar degeneration with premorbid bipolar disorder. *J Alzheimers Dis*. 2011;27:791-797
9. Liu A, Werner K, Roy S et al. A case study of an emerging visual artist with frontotemporal lobar degeneration and amyotrophic lateral sclerosis. *Neurocase* 2009;15:235-247
10. Masouy A, Chopard G, Vandel P et al. Bipolar disorder and dementia: where is the link? *Psychogeriatrics* 2011; 11:60-67
11. Quraishi S, Frangou S. Neuropsychology of bipolar disorder: a review. *J Affect Disord* 2002;72:209-226
12. Whitwell JL, Josephs KA. Neuroimaging in frontotemporal lobar degeneration-predicting molecular pathology. *Nat Rev Neurol* 2012;8:131-142
13. Garcin B, Lillo P, Hornberger M et al. Determinants of survival in behavioral variant frontotemporal dementia. *Neurology* 2009;73:1656-1661
14. Hornberger M, Shelley BP, Kipps CM, Piguet O, Hodges JR. Can progressive and non-progressive behavioural variant frontotemporal dementia be distinguished at presentation? *J Neurol Neurosurg Psychiatry* 2009;80:591-593
15. Davies RR, Kipps CM, Mitchell J, Kril JJ, Halliday GM, Hodges JR. Progression in frontotemporal dementia: identifying a benign behavioral variant by magnetic resonance imaging. *Arch Neurol*. 2006;63:1627-1631