

Chronic transverse sternal fracture. Role of CT scan and repair by an alternative use of the Synthes-Titanium Sternal Fixation System®

F. MONACO, S. LENTINI, F. TANCREDI, M. SAVASTA, O. PERRONE¹, M. MONACO¹,
R. GAETA, B. MONDELLO¹, M. BARONE¹

SUMMARY: Chronic transverse sternum fracture. Role of CT scan and repair by an alternative use of the Synthes-Titanium Sternal Fixation System®.

F. MONACO, S. LENTINI, F. TANCREDI, M. SAVASTA, O. PERRONE, M. MONACO, R. GAETA, B. MONDELLO, M. BARONE

Chest wall fractures, including injuries of the sternum, usually heal spontaneously without specific treatment. However sometimes, they need surgical treatment. To treat these patients the selection criteria often are subjective in spite of many surgical devices for sternal osteosynthesis are available nowadays. One of the most recent device is the Synthes-Titanium Sternal Fixing System®, usually used to treat post-sternotomy dehiscence.

We describe the case of a 67-year-old man with previous history of chest trauma presenting to our institution with chronic transverse sternal fracture. We describe the pre-operative study, stressing the particular role of the CT scan and a surgical approach by an alternative use of the Synthes®.

RIASSUNTO: Frattura cronica sternale. Utilità della TC e riparazione mediante un uso alternativo del sistema Synthes®.

F. MONACO, S. LENTINI, F. TANCREDI, M. SAVASTA, O. PERRONE, M. MONACO, R. GAETA, B. MONDELLO, M. BARONE

Le fratture della parete toracica, anche quelle coinvolgenti lo sterno, in genere guariscono spontaneamente senza un trattamento specifico. Tuttavia, a volte è necessario un trattamento chirurgico diversificato secondo le preferenze dell'operatore, nonostante la disponibilità attuale di alcuni dispositivi di sintesi sternale, tra cui il recente sistema di fissaggio sternale al titanio Synthes®, usato prevalentemente per trattare le deiscenze sternali post-sternotomia.

Descriviamo il caso di un paziente di 67 anni con pregresso trauma toracico che si presentava alla nostra osservazione con una frattura cronica traversa dello sterno. Nello studio pre-operatorio, un ruolo importante ha avuto la ricostruzione tridimensionale con TC multistrato. Descriviamo, infine, l'approccio chirurgico mediante un uso alternativo del dispositivo di fissaggio.

KEY WORDS: Sternum - CT scan - Fracture fixation.
Sterno - TC - Fissazione di frattura.

Introduction

Chest wall fractures, including injuries of the sternum, usually heal spontaneously without specific treatment (1, 2).

To treat these patients the selection criteria can be subjective, in spite of many surgical devices for sternal osteosynthesis available nowadays. One of the most recent devices is the Synthes-Titanium Sternal Fixing System®, usually used to treat post-sternotomy dehiscence.

In a patient with chronic transversal sternal fracture

we used this new system, but in a different way than proposed by the manufacturer and usually performed.

Case report

We present the case of a 67-year-old man with previous history of chest trauma due to car accident four months before. The patient complains of chest pain and dyspnoea. Chest X-ray and CT scan (Siemens Somatom Definition Dual Source CT Scan®) showed a complete transverse sternal fracture with pseudo arthrosis of the stumps (Fig. 1). The patient was therefore scheduled for surgery.

Under general anaesthesia a 12 cm incision was done along on the middle sternal line and the bone was exposed (Fig. 2). A complete chronic transverse sternal fracture was identified in the upper part of the sternum body. After curettage of the two stumps, at the beginning we thought to perform a middle sternotomy of the lower part of the sternum up to the fracture line, and then to fix the bone with sternal wires. We decided instead to use the Synthes®. With the help of CT scan, we calculated the thickness of the sternum (12

Università degli Studi di Messina, Italy
Policlinico "G. Martino", Messina
UOC Cardiocirurgia

¹ UOC di Chirurgia Toracica

© Copyright 2009, CIC Edizioni Internazionali, Roma

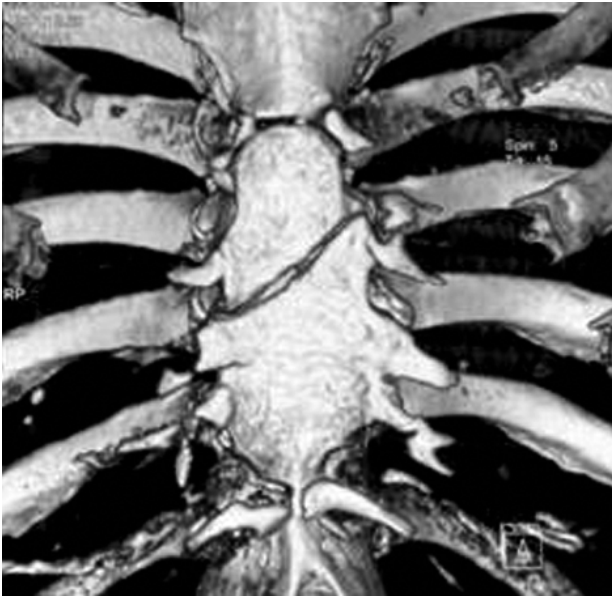


Fig. 1 - CT scan. Dual source image shows complete transverse sternal fracture with two lines of pseudoarthrosis of the stumps.

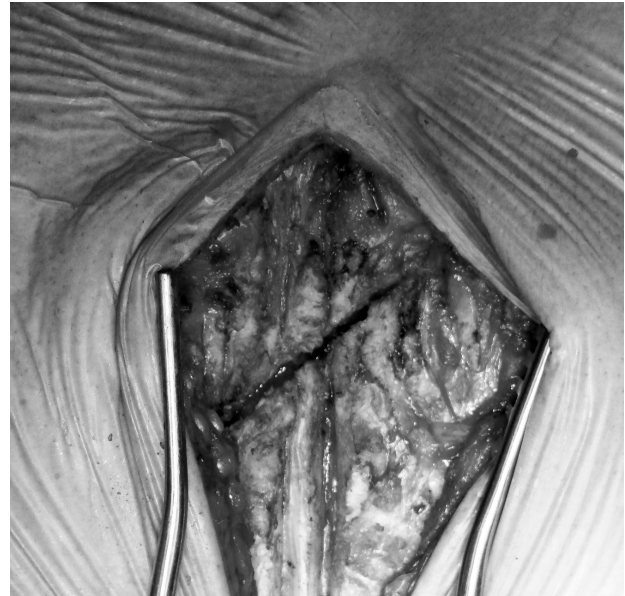


Fig. 2 - Intraoperative finding of complete transverse sternal fracture.

mm), then we inserted two fourteen-hole plaques by the mean of six 12 mm screws on each side (Fig. 3). The plaques were inserted in a longitudinal fashion, and not transversally as suggested by the manufacturer and as usual in sternal reconstruction. A 1,5 cm space was left between two plaques. The titanium plaques were modelled using a particular instrument supplied by the manufacturer, in the way to follow exactly the angle between the manubrium and the body of the sternum.

The patient was discharged on the third postoperative day. A one month and three months later follow-up, the sternum has healed completely, with chest stability during breathing. The patient remains asymptomatic.

Discussion

Chest wall fractures, including injuries of the sternum, usually heal spontaneously without specific treatment (1-3). Sternal fractures represent a major risk of pulmonary stasis and respiratory infections caused by impaired thoracic cage motion. Chronic sternal fracture (non-union) is usually reported after median sternotomy, but rarely after blunt chest trauma. An accurate diagnosis through imaging is important, to provide the better treatment in patients with sternal lesions (4, 5).

We used Siemens Somatom Definition Dual Source CT Scan® to study this patient with cronic transverse sternal fracture. Sternal volume-rendering shows fracture details and guide the surgical procedure oriented to the sternum morphology. In our patient CT was useful to determine the thickness of the bone. The morphological data, detected by “volume-rendering” imaging scans, allow to choose the proper surgical procedure to perform full sternal morphallaxis.

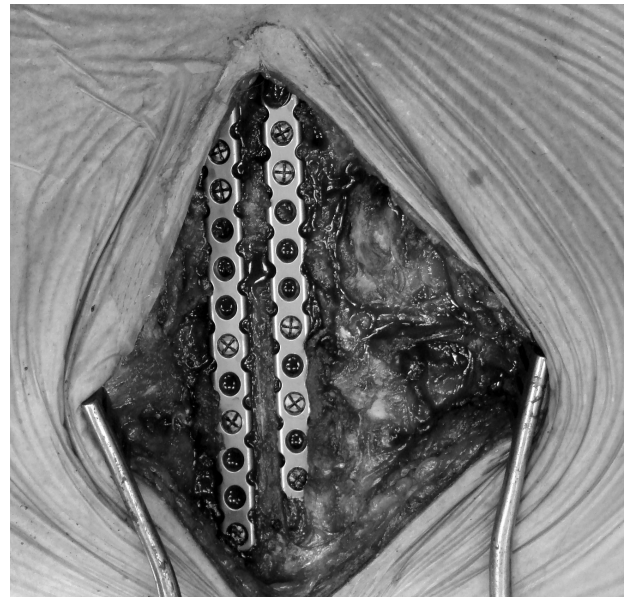


Fig. 3 - Surgical treatment with two titanium plaques vertically fixed and modeled on the sternum to obtain sternal osteosynthesis and simultaneously to preserve the middle line for possible future sternotomy.

Different surgical approaches may be used for sternal repair (6-8). Selection criteria can be subjective, and many surgical devices for sternal osteosynthesis are available nowadays (9-11). The Synthes® provides stable internal fixation of the sternum for primary or secondary closure and repair, and is particularly useful following debridement of the sternum, or when sternal bone qua-

lity is insufficient for titanium flexible plaques and screws. Titanium plating system device is preferred to achieve better results in terms of stability and modeling.

The titanium plaques of the Synthes® are usually used for dehiscence after median sternotomy for cardiac surgery. They are usually positioned transversally and screwed on the costal cartilages to approximate the two sides of the chest wall. Instead of the conventional use, in our patient the two plaques were adapted in a vertical position (Fig. 3), and a 1,5 cm free space was left between. Then, this free space can be used to perform a possible future sternotomy. The advantage of the titanium plaques is also the possibility to model them on the chest anatomy. In our patient, we modelled the shape of the two plaques on the morphology of the angle between sternum body and manubrium, giving adherence of the plaques to the bone.

Conclusion

We think that in sternal fractures it is important a correct diagnosis for the choice of the proper the surgical procedure. The multi-slide CT scan with three-dimensional reconstruction is very useful to determine the exact line of fracture or pseudoarthrosis. CT scan will also measure the thickness of the sternal bone, important as to define the length of the screw. If the bone thickness is known, is possible to treat the sternal lesion without cutting the bone in the middle line to reach the area of the "transverse fracture". This can be done in an appropriate and secure fashion using those flexible titanium plaques modelled on the morphology of the sternum, implanting them vertically in the case of transverse fracture and keeping in mind to leave a free space between them a possible future sternotomy. Further use of this new device will help to better define its real advantages.

References

1. Vodicka J, Spidlen V, Safránek J, Simánek V, Altmann P. Severe injury to the chest wall—experience with surgical therapy. *Zentralbl Chir* 2007;132(6):542-6.
2. Knobloch K, Wagner S, Haasper C, Probst C, Krettek C, Vogt PM, Otte D, Richter M. Sternal fractures are frequent among polytraumatised patients following high deceleration velocities in a severe vehicle crash. *Injury* 2008;39(1):36-43.
3. Richardson JD, Franklin GA, Heffley S, Seligson D. Operative fixation of chest wall fractures: an underused procedure? *Am Surg* 2007;73(6):591-6; discussion.
4. Kehdy F, Richardson JD. The utility of 3-D CT scan in the diagnosis and evaluation of sternal fractures. *J Trauma* 2006;60(3):635-6.
5. Sangster GP, González-Beicos A, Carbo AI, Heldmann MG, Ibrahim H, Carrascosa P, Nazar M, D'Agostino HB. Blunt traumatic injuries of the lung parenchyma, pleura, thoracic wall, and intrathoracic airways: multidetector computer tomography imaging findings. *Emerg Radiol* 2007;14(5):297-310.
6. Böcker W, Euler E, Schieker M, Kettler M, Mutschler W. A novel surgical technique for transverse sternal bone defects using flexible intramedullary nailing. *Thorac Cardiovasc Surg* 2006;54(8):564-6.
7. Zeitani J, Penta de Peppo A, Bianco A, Nanni F, Scafuri A, Bertoldo F, Salvati A, Nardella S, Chiariello L. Performance of a novel sternal synthesis device after median and faulty sternotomy: mechanical test and early clinical experience. *Ann Thorac Surg* 2008;85(1):287-93.
8. Gallo DR, Lett ED, Conner WC. Surgical repair of a chronic traumatic sternal fracture. *Ann Thorac Surg* 2006;81.
9. Molina JE. Evaluation and operative technique to repair isolated sternal fractures. *J Thorac Cardiovasc Surg* 2005;130.
10. Wu LC, Renucci J, Song DH. Rigid-plate fixation for the treatment of sternal nonunion. *J Thorac Cardiovasc Surg* 2004;128(4):623-4.
11. Bertin KC, Rice RS, Doty DB, Jones KW. Repair of transverse sternal nonunions using metal plates and autogenous bone graft. *Ann Thorac Surg* 2002;73(5):1661.

M.G. Balzanelli

MANUALE DI MEDICINA DI EMERGENZA E PRONTO SOCCORSO

II edizione aggiornata
con le Linee Guida
ILCOR 2005-2006
per la Rianimazione
Cardiopulmonare

Volume brossurato
di 1.536 pagine
f.to cm 12x19
€ 80,00

per acquisti online
www.gruppocic.com



CIC Edizioni Internazionali

