

Primary mesenteric liposarcoma. Report of a case

P.G. CALÒ, S. FARRIS, A. TATTI, M. TUVERI¹, G. CATANI², A. NICOLOSI

SUMMARY: Primary mesenteric liposarcoma. Report of a case.

P. G. CALÒ, S. FARRIS, A. TATTI, M. TUVERI, G. CATANI, A. NICOLOSI

Primary mesenteric liposarcomas are very rare neoplasms. The authors report a case of mesenteric liposarcoma recently observed.

The patient presented with a history of dyspeptic syndrome, meteorism and abdominal pain associated with a change in bowel habit and constipation. On physical examination there was a large, well-circumscribed, abdominal mass. Computed tomography revealed an abdominal, dishomogeneous, low-density mass.

Surgical excision with a tumour-free margin was achieved. The histologic appearances were those of a well-differentiated liposarcoma (atypical lipomatous tumour). The patient is alive and disease-free 33 months after the surgery.

Primary mesenteric liposarcoma is often resectable and requires aggressive surgical management; in consideration of the high risk of tumour recurrence, the treatment of choice is a wide surgical excision.

RIASSUNTO: Liposarcoma primitivo del mesentere. Descrizione di un caso clinico.

P. G. CALÒ, S. FARRIS, A. TATTI, M. TUVERI, G. CATANI, A. NICOLOSI

I liposarcomi primitivi del mesentere sono neoplasie molto rare. Gli Autori riportano un caso di liposarcoma del mesentere osservato recentemente.

La paziente giunse all'osservazione con una storia di sindrome dispeptica, meteorismo e dolore addominale associati ad un cambiamento delle abitudini dell'alvo con stipsi. All'esame obiettivo era presente una voluminosa tumefazione addominale, a limiti netti. La tomografia computerizzata rivelò una massa addominale disomogenea, a bassa densità.

Fu effettuata una asportazione chirurgica con margini indenni. L'aspetto istologico era quello di un liposarcoma ben differenziato (tumore lipomatoso atipico). La paziente è vivente e libera da malattia a 33 mesi dall'intervento chirurgico.

Il liposarcoma primitivo del mesentere è spesso resecabile e richiede una condotta chirurgica aggressiva; in considerazione dell'alto rischio di recidiva locale, il trattamento di scelta è una escissione chirurgica ampia.

KEY WORDS: Liposarcoma - Mesentery - Surgery.
Liposarcoma - Mesentere - Chirurgia.

Introduction

Liposarcoma is one of the most common soft tissue sarcoma; it frequently occurs in limbs, retroperitoneum and abdominal cavity of adults.

Primary mesenteric liposarcomas are very rare neoplasms. The first case in the English literature was described by Manson in 1951 (1). Only 11 cases of this neoplasm are described in literature (2).

The Authors report a case of mesenteric liposarcoma recently observed.

Case report

A 43-yr-old woman presented at our University Hospital with a 4-month history of dyspeptic syndrome and meteorism and a 3-weeks history of abdominal pain associated with change in bowel habit and constipation. She had no urinary symptoms.

On physical examination there was a large, diffuse, well-circumscribed abdominal mass.

Policlinico Universitario, Monserrato (Cagliari)

Dipartimento di Chirurgia

(Direttore: Prof. A. Nicolosi)

¹ Casa di Cura "S. Elena", Quartu S. Elena (Cagliari)

Dipartimento di Chirurgia

(Direttore: Prof. A. C. Tuveri)

² Ospedale "G. Brotzu", Cagliari

S.C. Anatomia Patologica

(Direttore: Dott. G. Catani)

© Copyright 2007, CIC Edizioni Internazionali, Roma

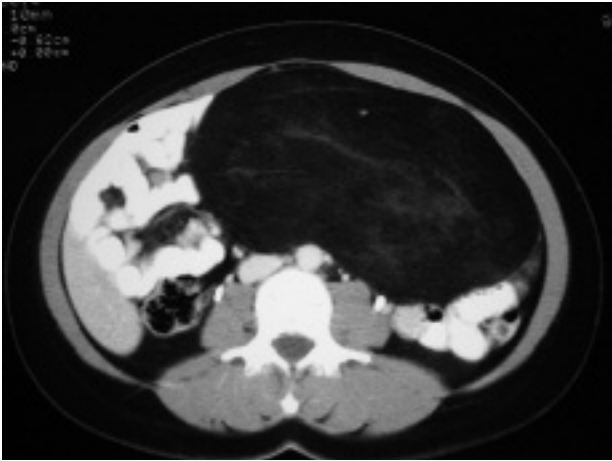


Fig. 1 - CT scan: abdominal, dishomogeneous, low-density mass with small bowel dislocation but without infiltration.

Laboratory investigations showed no abnormalities. Computed tomography revealed an abdominal, dishomogeneous, low-density mass with small bowel dislocation but without infiltration (Fig. 1). There was no evidence of lymphadenopathy nor distant metastasis.

A laparotomy was performed disclosing a large, well-circumscribed mass arising from the small intestine mesentery. The neoplasm was easily removed. Surgical excision with a tumour-free margin was achieved. Small bowel was not devascularized and no intestinal resection was necessary.

The gross specimen was lobulated and well-demarcated, weighed 2120 g and measured 20x16 cm (Fig. 2). The neoplasm had a greyish-yellow cut surface. The sections were stained with hematoxylin and eosin. The histologic appearances were those of a well-differentiated liposarcoma (atypical lipomatous tumour). The tumour was composed of a mature adipocytic cell proliferation showing significant variation in cellular size, scattered hyperchromatic stromal cells with irregularly shaped nuclei and rare monovacuolated lipoblasts (Figs. 3 and 4).

Adjuvant chemotherapy was administered with a combination regimen consisting of Cyclophosphamide, Vincristine, Adriamycin and Dacarbazine every 21 days (CYVADIC q21).

The patient is alive and disease-free 33 months after the surgery.

Discussion

Primary mesenteric liposarcomas are rare neoplasms which appear to be similar to liposarcomas in other body sites: these lesions mostly occur in middle-aged adults with a slight male preponderance (2-4). They are exceptional in children (5).

Liposarcomas are classified into 3 groups: well-differentiated liposarcomas with or without dedifferentiation, myxoid and round cell/cellular myxoid liposarcomas and pleomorphic liposarcomas. Myxoid liposarcoma is the most common type, found in approximately 50% of cases, followed by well-differentiated liposarcoma in 25%. Well-differentiated liposar-

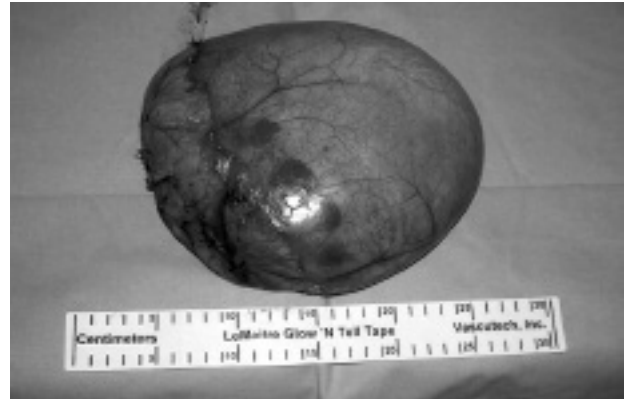

Fig. 2 - Lobulated well-circumscribed mass with a few areas of hemorrhage.

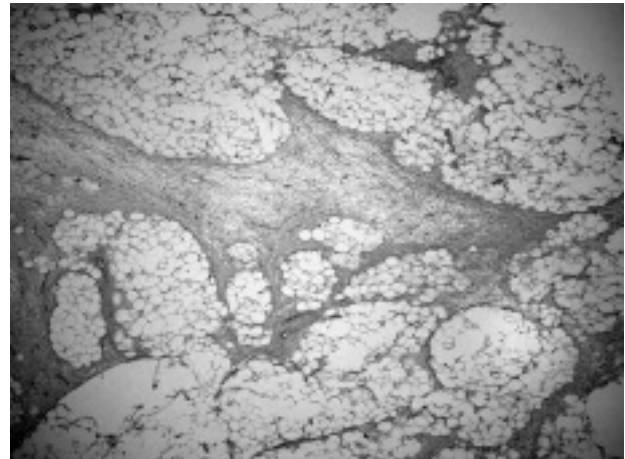


Fig. 3 - Mature, well-differentiated lipoblasts and fibrous and myxoid areas forming irregular stromal septa (Hematoxylin and Eosin, 48x).

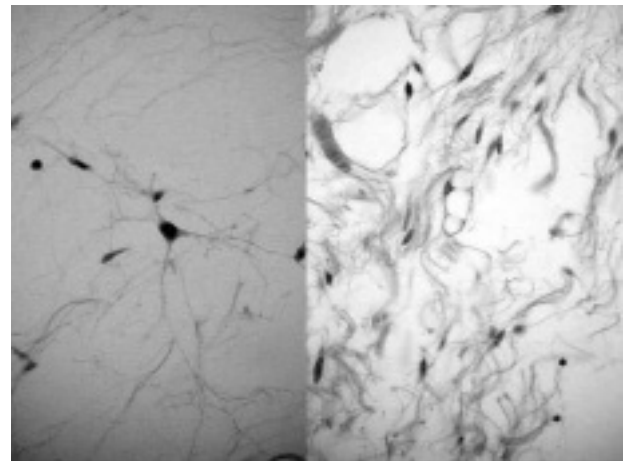


Fig. 4 - Fibroblast-like cells and spindle cells. The presence of atypical stromal cells with hyperchromatic and multilobulated nuclei represents a common finding (Hematoxylin and Eosin, 480x).

coma has the best prognosis. Dedifferentiated liposarcoma behaves more aggressively than pure well-differentiated liposarcoma with a local recurrence rate of

41%, a metastasis rate of 17%, and a disease-related mortality of 28% (6).

The mode of clinical presentation is dependent on the size and exact location of the tumour. The physical finding of a mass that is easily movable in all directions is frequent and has some diagnostic utility (2, 3).

Computed tomography is helpful for diagnosis and for planning therapy (7). Each histologic subtype of abdominal liposarcoma showed different CT attenuation or MR imaging signal intensity characteristics (8).

In our case symptoms were probably due to compression by the mass which revealed to be well-circumscribed on physical examination. Computed tomography revealed a low-density mass suggesting to be a lipoma or a well-differentiated liposarcoma. Surgical excision with tumour-free margins was possible

without devascularization of small bowel and intestinal resection was unnecessary. The patient is alive and well 33 months after surgery.

Conclusions

Identification of dedifferentiation areas, careful follow-up to detect early recurrence, and histological malignancy grading combined with proliferation indices are important in providing an accurate prognosis for all patients with mesenteric liposarcoma (6). On the contrary of the retroperitoneal liposarcoma, the primary mesenteric liposarcoma is often resectable and requires aggressive surgical management (2). In consideration of the high risk of tumor recurrence the treatment of choice is a wide surgical excision.

References

1. Manson JMS. Mesenteric liposarcoma. A rare case of intestinal obstruction. *Br J Surg* 1951; 38: 394-396.
2. Moyana TN. Primary mesenteric liposarcoma. *Am J Gastroenterol* 1988; 83: 89-92.
3. Baldi A, Ganio E, Rosato L. Considerazioni su un caso di liposarcoma primitivo del mesentere. *Arch Sci Med* 1982; 139: 523-529.
4. Calò PG, Congiu A, Ferrelì C, Nicolosi A, Tarquini A. I tumori retroperitoneali primitivi. *Nostra esperienza. Minerva Chir* 1994; 49: 43-49.
5. Pawel BR, de Chadarevian JP, Inniss S, Kalwinski P, Paul SR, Weintraub WH. Mesenteric pleomorphic liposarcoma in an adolescent. *Arch Pathol Lab Med* 1997; 121: 173-176.
6. Hasegawa T, Seki K, Hasegawa F, Matsuno Y, Shimodo T, Hirose T, et al. Dedifferentiated liposarcoma of retroperitoneum and mesentery: varied growth patterns and histological grades—a clinicopathologic study of 32 cases. *Hum Pathol* 2000; 31: 717-727.
7. Munk PL, Lee MJ, Poon PY, Goddard KJ, Knowling MA, Hassell PR. Computed tomography of retroperitoneal and mesenteric sarcomas: a pictorial essay. *Can Assoc Radiol J* 1996; 47: 335-341.
8. Kim T, Murakami T, Oi H, Tsuda K, Matsuhita M, Tomoda K, et al. CT and MR imaging of abdominal liposarcoma. *AJR Am J Roentgenol* 1996; 166: 829-833.