

## Mesenteric cystic lymphangioma treated with laparoscopic excision: case report and review of the literature

F. TALARICO, D. IUSCO, L. NEGRI, L. VALIERI

**SUMMARY:** Mesenteric cystic lymphangioma treated with laparoscopic excision: case report and review of the literature.

F. TALARICO, D. IUSCO, L. NEGRI, L. VALIERI

*Mesenteric cystic lymphangioma is a rare lesion.*

*We described a case of 20 years old patient with an asymptomatic cystic lymphangioma that was detected after ultrasound scan performed for a minor abdominal trauma. The patient was treated with laparoscopic exploration and an intestinal resection by mini-laparotomy.*

*Although very rare, cystic mesenteric lymphangiomas may cause complications; therefore, they should be always treated with surgical excision and should be included in the differential diagnosis of acute abdomen.*

**RIASSUNTO:** Linfangioma cistico mesenterico trattato con escissione laparoscopica: case report e revisione della letteratura.

F. TALARICO, D. IUSCO, L. NEGRI, L. VALIERI

*Il linfangioma cistico del mesentere è una patologia raramente descritta in letteratura.*

*Descriviamo il caso di una paziente di 20 anni, asintomatica, alla quale è stata diagnosticata un massa cistica intestinale durante un'ecografia eseguita per trauma addominale minore. La paziente è stata trattata con laparoscopia esplorativa e resezione intestinale mediante accesso minilaparotomico in fossa iliaca destra.*

*Anche se rari, i linfangiomi cistici del mesentere possono complicarsi; quindi, dovrebbero essere sempre trattati con l'escissione chirurgica e dovrebbero sempre essere inclusi nelle diagnosi differenziale di addome acuto.*

**KEY WORDS:** Small bowel mesentery - Cystic lymphangioma - Mesenteric lymphangioma - Surgery.  
Mesentere ileale - Linfangioma cistico - Linfangioma mesenterico - Chirurgia.

### Introduction

Lymphangiomas are rare benign tumors which occur mainly in paediatric patients; approximately 80-90%, in fact, are diagnosed within the first few years of life and adult cases are rare (1). They are usually found in the head, neck, and axillary region. Isolated occurrence in the mesentery of the small intestine is exceptional, comprising less than 1% of all lymphangiomas (2). Often preoperative studies, such as abdominal ultrasonography and magnetic resonance imaging, are not able to accurately determine the nature of the tumor.

We report a case of an adult patient with a large lymphangioma of the small bowel mesentery that was discovered incidentally. The diagnosis was possible only at pathology examination.

### Case report

D. F., a 20 years old male, was referred to our service for abdominal mass diagnosed during a routine abdomen ultrasound scan performed after a minor abdominal trauma. At physical examination the abdomen was soft, not tender; a 10 cm mass, whit not well defined margins, was palpable in the hypogastric area. Laboratory test were all within the range of normality.

Ultrasound scan examination showed 9 cm anaechogenic mass, with internal septa and a thick wall behind the bladder. The patient underwent CT scan that showed a large hypodense pelvic cystic lesion with trasverse diameter of 9 cm and longitudinal diameter of 13 cm, between the bladder and the rectum and above the seminal vesicles. The lesion had a liquid density and the cranial part have digitations in contact with some small bowel loops. Inside these digitations there were some septa with enhancement by contrast medium. Pelvic MRI scan confirmed the finding of CT scan and a fir-

Azienda Unità Sanitaria Locale, Bologna  
Ospedale "Santissimo Salvatore", San Giovanni in Persiceto (BO)  
Dipartimento Chirurgico  
Unità Operativa Chirurgia Generale  
(Direttore: Dott. F. Talarico)

© Copyright 2009, CIC Edizioni Internazionali, Roma

st radiological diagnostic hypothesis of sigmoid colon duplication was made (Figs. 1 and 2).

Considering the extent of the mass and the impossibility to have a precise diagnosis the patient underwent surgical operation.

Explorative laparoscopy showed a 8 cm cystic mass of the small bowel with dislocated ileo-cecal valve in the Douglas pouch. After laparoscopic mobilization, the mass was exteriorised by a right iliac mini-laparotomy. The segment of small bowel with the mass was resected and a side-to-side manual anastomosis was performed. Histological examination of the specimen showed a cystic lymphangioma of the mesentery.

The post-operative course was uneventful and the patient was discharged on sixth postoperative day.

## Discussion

Lymphangiomas are probably due to a congenital abnormality of the lymphatic system, causing sequestrations of lymphatic tissue during embryologic development (2). This theory would explain why lymphangiomas occur primarily in children. However, it is suggested that abdominal trauma, lymphatic obstruction, inflammatory process, surgery, or radiation therapy may lead to the secondary formation of such a tumor (3). The most common sites for lymphangiomas are the neck and axilla, while abdominal localization is rare, accounting for only about 9% of all cases. Among these, the most frequent site of occurrence is the mesentery of the small intestine (70.5%), followed by the mesocolon (26.2%) (5).

Lymphangiomas are classified by most authors as simple, cavernous, or cystic. The simple type is composed of small thin-walled lymphatic vessels. The cavernous type is composed of dilated lymphatic vessels and lymphoid stroma, and has a connection with spaces of various normal adjacent lymphatics (6). Lastly the cystic type, first described in 1828 by Radenbacker, consists of lymphatic spaces of various sizes that contains fascicles of smooth muscle and collagen bundles, but has no connection with adjacent normal lymphatics (7). However, according to Gester et al., cystic lymphangioma is not always clearly differentiated from cavernous type because the cystic type may also contain cavernous areas (8). Tsudaka et al. in a review stated that only cavernous and cystic lymphangiomas have been found intra-abdominally while the simple type is usually situated under the skin (5).

Mesenteric lymphangiomas are usually asymptomatic until they enlarge (9). The clinical picture of mesenteric lymphangiomas is not characteristic. Some patients may present with abdominal pain that is not localized, a palpable mass, and abdominal distension. However, other patients may have acute clinical symptoms. Infact, although benign in nature, mesenteric lymphangiomas may cause significant morbidity or mortality due to their large size and critical location, when they compress the




Fig. 1 - MRI scan showing the cystic mass between the rectum and the bladder.

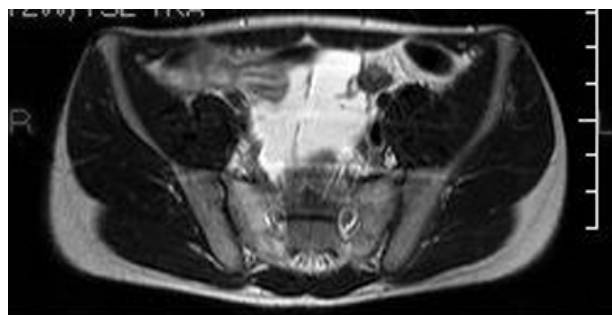

Fig. 2 - MRI scan showing the mass in contact with small bowel loops.

adjacent structures. In addition secondary infection, intestinal obstruction or volvulus, rupture with haemorrhage have all been reported as complications (10-13).

The preoperative diagnosis is now made easier by the widespread use of imaging diagnostic modalities such as US, CT, and MRI. The ultrasonographic presentation of a mesenteric lymphangioma is described as a cystic lesion with multiple thin septa. On CT imaging, mesenteric lymphangiomas appear as a uni- or multilocular mass with enhancement of the wall and septum by contrast medium (14). These studies help to determine if the tumor is cystic as well as its size and location. Several authors have reported that fine needle aspiration of a milky fluid containing cells is useful for confirming a preoperative diagnosis of lymphangioma (15). However, a correct preoperative diagnosis, especially in children, is frequently difficult because many mesenteric lymphangiomas present as an acute abdomen, necessitating emergency exploration (16).

Mesenteric lymphangiomas may be invasive and grow to an huge size. The optimal treatment is radical excision, even when asymptomatic, since incomplete resection may lead to recurrence (17). Lymphangiomas may

cause complications such as infiltration of the intestine, or involvement of the main branch of mesenteric arteries or adjacent organs that necessitate segmental resection of the intestine. Sometimes radical resection might be technically impossible (18). In these cases, injections of bleomycin or OK-432 into the tumor have been reported to be effective (19, 20).

## Conclusions

Our case describe an accidental finding of an asymptomatic mesenteric cystic lymphangioma mimicking a colonic duplication. It is reasonable to think

that this mass if left in place would have become symptomatic.

The laparoscopic approach helped to clarify the entity of the problem and minimize the operative trauma. In fact explorative laparoscopy helped to realize that the cystic mass belonged to the small bowel mesentery, and that the mass was excisable by means of a mini right laparotomy after its complete mobilization from the pelvic pouch.

Mesenteric lymphangiomas are very rare, but they can cause complications that may requires an emergent surgery. Therefore, they should be always treated with surgical excision and should be included in the differential diagnosis of acute abdomen.

## References

1. Hanagiri T, Baba M, Shimabukuro T, Hashimoto M, Takemoto, H, Inoue A, Sugitani A, Shirakusa T. Lymphangioma in the small intestine: Report of a case and review of the Japanese literature. *Surgery Today* 1992; 22: 363-367.
2. Roisman I, Manny J, Fields S, Shiloni E. Intra-abdominal lymphangioma. *Br J Surg* 1989; 76: 485-489.
3. Hardin WJ, Hardy JD. Mesenteric cysts. *Am J Surg* 1970; 119: 640-645.
4. Daniel S, Lazarevic B, Attia A. Lymphangioma of the mesentery of the jejunum: Report of a case and a brief review of the literature. *Am J Gastroenterol* 1983; 78: 726-729.
5. Tsukada H, Takaori K, Hshiguro S, Tsuda T, Ota S, Yamamoto T. Giant Cystic Lymphangioma of the small Bowel Mesentery: Report of a Case *Surg Today* 2002; 32:734-737.
6. Chen CW, Hsy SD, Lin CH, Cheng MF, Yu JC. Cystic lymphangioma of the jejunal mesentery in an adult: a case report. *World J Gastroenterol*. 2005; 11:5084-6.
7. Rieker RJ, Quentmeier A, Weiss C, Ktretschmar U, Amann K, Mechttersheimer G, Blaker H, Herwart OE. Cystic lymphangioma of the small-bowel mesentery: case report and a review of the literature. *Pathol Oncol Res*. 2000;6:146-8.
8. Gerster JCA. Retroperitoneal Chyle cysts:with a speceial reference to lymphangioma. *Ann Surg* 1939; 110:389-410.
9. Bliss DP, Coffin CM, Bower RJ, Stockmann PT, Ternberg JL. Mesenteric cysts in children. *Surgery* 1994; 115: 571-577.
10. Ricca RJ. Infected mesenteric lymphangioma. *NY State J Med* 1991; 91: 359-361.
11. Porras-Ramirez G, Hernandez-Herrera MH. Hemorrhage into mesenteric cyst following trauma as a cause of acute abdomen. *J Pediatr Surg* 1991; 26: 847-848.
12. Yoon HK, Han BK. Chronic midgut volvulus with mesenteric lymphangioma: a case report. *Pediatr Radiol* 1998; 28: 611.
13. Prabhakaran K, Patankar J Z, Loh D L S K, Ahamed Faiz Ali M A Singapore Med J. 2007;48:265-7.
14. Davidson AJ, Hartman DS. Lymphangioma of the retroperitoneum. CT and sonographic characteristics. *Radiology* 1990; 175: 507-510.
15. Sadola E. Cystic lymphangioma of the jejunal mesentery in an adult. *J Clin Ultrasound* 1987;15:542-3.
16. Seki H, Ueda T, Kasuya T, Kotanagi H, Tamura T. Lymphangioma of the jejunal and mesentery presenting with acute abdomen in an adult. *J Gastroenterol* 1998;33:107-11.
17. Raszkowski HJ, Rehbock DJ, Cooper FG. Mesenteric and retroperitoneal lymphangioma. *Am J Surg* 1959;97:363-7.
18. Melcher GA, Ruedi T, Allemann J. Cystic lymphangioma of the mesenterial root as a rare cause of acute abdomen. *Chirurg* 1995; 66: 229-231.
19. Orford J, Barker A, Thonell S, King P, Murphy J. Bleomycin therapy for cystic hygroma. *J Pediatr Surg* 1995;30:1282-7.
20. Jessner M, Lak FG, Rein CR. Angiosarcoma in postmastectomy. *Arch Dermatol* 1952;5:123.