

How to prevent intraoperative risks and complications in laparoscopic splenectomy

R. VECCHIO, V. GELARDI, E. INTAGLIATA, U. BARBAROS¹, R.R. CACCIOLA², E. CACCIOLA²

SUMMARY: How to prevent intraoperative risks and complications in laparoscopic splenectomy.

R. VECCHIO, V. GELARDI, E. INTAGLIATA, U. BARBAROS, R.R. CACCIOLA, E. CACCIOLA

Since its introduction in 1992 laparoscopic splenectomy (LS) has become the technique of choice for surgical removal of the spleen in several centres. The procedure, however, is associated with risks and complications, either during surgery or in the postoperative phase. Although the incidence of intraoperative complications is unknown, intraoperative risks in patients undergoing laparoscopic splenectomy are not uncommon. In this article, we reviewed the literature on risks and complications during LS, and we point out, based on our personal series and on the experiences reported by other Authors, how to prevent, whenever possible, these complications.

RIASSUNTO: Come prevenire i rischi e le complicanze intraoperatorie nella splenectomia laparoscopica.

R. VECCHIO, E. INTAGLIATA, V. GELARDI, U. BARBAROS, R.R. CACCIOLA, E. CACCIOLA

Dalla sua introduzione nel 1992, la splenectomia laparoscopica (LS) è diventata la tecnica di scelta per la rimozione chirurgica della milza in diversi centri. La procedura, tuttavia, è associata a rischi e complicanze, sia durante l'intervento chirurgico che in fase post-operatoria. Sebbene l'incidenza delle complicanze intra-operatorie non sia nota, i rischi intraoperatori in pazienti sottoposti a splenectomia laparoscopica non sono infrequenti. In questo articolo, abbiamo esaminato la letteratura sui rischi e le complicanze durante la splenectomia laparoscopica e ricordiamo, sulla base della nostra serie e dell'esperienza segnalata da altri autori, come prevenire, ove possibile, tali complicanze.

KEY WORDS: Splenectomy - Laparoscopy - Complications.
Splenectomia - Laparoscopia - Complicanze.

Introduction

After its introduction in 1992 laparoscopic splenectomy (LS) (1) has been increasingly accepted and has become the technique of choice for surgical removal of the spleen. Several studies have pointed out the advantages of the laparoscopic splenectomy when compared to the open approach.

In addition to reduced hospital stay, faster return to normal activities, less post-operative pain and better cosmetic results, the laparoscopic technique seems to be

associated to specific advantages and haematological benefits. Several clinical and experimental studies support the view that laparoscopic surgery is associated with better preservation of post-operative systemic immune function than open surgery (2).

Other clinical studies have shown that laparoscopic surgery may induce less haemostatic changes than traditional surgery (3). In patients with idiopathic thrombocytopenic purpura, laparoscopic approach allows also a complete visualization of accessory spleens, whose removal is essential for the curative effects of splenectomy. In addition, recent reports show that in these patients the need of platelet transfusions is reduced during laparoscopic procedure when compared to open approach (3).

Although laparoscopic splenectomy is becoming the gold standard in several haematological diseases where removal of the spleen is indicated, the procedure is associated with risks and complications, either during surgery or in the post-operative phase. The incidence of in-

University of Catania, Italy
Department of General Surgery

¹ Istanbul University
Istanbul Faculty of Medicine, Istanbul, Turkey
Department of General Surgery

² University of Catania, Italy
Department of Biomedical Science, Section of Haematology

© Copyright 2010, CIC Edizioni Internazionali, Roma

tra-operative complications is unknown, since it is not completely indicated in literature reports. A review of the Literature shows, however, that in several reported series the rate of conversion to open surgery during splenectomy, which reflects troubles and intra-operative complications, is not uncommon, ranging from 0 up to 19% (4, 5, 6, 7, 8). When the causes of these conversions are analyzed, it seems evident that the most common trouble during LS is intra-operative bleeding, reported as 80% of causes of conversion, followed by iatrogenic lesions, mainly in the pancreatic tail and in the diaphragm, and peritoneal adhesions (4-8).

Conversely, post-operative complications are well recognized and defined in almost every reported series. They are similar to those reported traditionally after open splenectomy, although some of them are at higher risk in patients operated on with the laparoscopic approach. Postoperative bleeding, pancreatitis and pancreatic fistula, sub-phrenic abscess, broncopneumonia and pleuritis, portal vein thrombosis and pulmonary embolism, overwhelming post-splenectomy sepsis are complications which can occur in the early or late post-operative phase after laparoscopic splenectomy and sometimes, like it has been observed by several Authors after the open approach, they can be life-threatening. Probably, patient operated on with the laparoscopic approach, however, are at higher risk of developing complications such as portal vein thrombosis and pulmonary embolism, since the mini-invasive approach with the use of pneumoperitoneum can predispose to vein stasis both in the abdominal cavity and in the legs.

In this article, we reviewed the literature on risks and complication following laparoscopic splenectomy, and we point out, based on our personal series and on the experiences reported by other Authors, how to prevent, whenever possible, these complications.

Intra-operative bleeding

Bleeding is the most common intra-operative complication during laparoscopic splenectomy, with an incidence varying from 1.9 to 20% in several series. It represents the 80% of causes for conversion to open splenectomy (9-14). In addition, it is the most common reason for a "second look" operation in the immediate post-operative phase. When open splenectomy is compared to LS, it seems that bleeding is more common during laparoscopy. In the meta-analysis study reported by Winslow et al (15), the rate of hemorrhagic complications, when conversion to open splenectomy was not considered, was not significantly different between the two groups (open splenectomy 2.4%; LS 1.6%; P not significant). However, when conversion for bleeding was included as hemorrhagic complication, the LS group

showed in the same study an higher incidence (4.8%), with a statistically significant difference with the open group ($p < 0.01$).

These data may mislead considering that a bleeding during LS, especially in the learning curve phase, may reflect not a major haemorrhage but instead a minor bleeding which is not even mentioned in the open series.

Usually, bleeding during splenectomy is secondary to splenic capsule tears and, more dangerously, to difficult haemostatic control of the short gastric vessels or of the splenic arteries or veins at the hilum.

Massive splenomegaly is an unfavorable factor for intra-operative bleeding. Laparoscopy for removal of enlarged spleen has been extensively debated (16-18). Massive splenomegaly is a challenging condition for laparoscopic splenectomy and it has often considered as a relative contraindication for removal of the spleen through a laparoscopic approach. With increasing experience of the surgical team, LS in splenomegaly is feasible and may offer the same advantages of LS in smaller spleen (16). Compared to open surgery LS in enlarged spleen seems to be associated with lower morbidity, transfusion rate and shorter hospital stay (17). However, the conversion rate for bleeding during LS in splenomegaly is significantly higher compared to LS performed in normalsize spleen (17). Preoperative splenic artery embolization has been proposed in patients with splenomegaly as a means to reduce the size of the spleen and to perform a safe, bloodless laparoscopic splenectomy. This approach, however, could be associated to an additional risk due to the invasiveness of preoperative embolization. In an attempt to lower the risk of bleeding during LS in splenomegaly we suggest (3), after the division of the short gastric vessels, to isolate and double clip the splenic artery in the superior aspect of the pancreatic tail (Fig. 1).

This step is essential to perform bloodless the following steps of LS and, on the meantime, it allows a partial reduction of the spleen volume during surgery. In addition, our suggested early occlusion of splenic artery during LS permits the recovery of blood components that, following splenic artery occlusion, are mobilized from the spleen to the bloodstream through the splenic vein.

"Difficult" splenic hilum is also an important cause of intra-operative bleeding; lymphatic oedema or lymphadenopathy at the splenic hilum might make difficult the control of the splenic vessels during splenectomy and might cause slippage of knots or clips around the main splenic arteries and veins, resulting in bleeding either intra-operatively or post-operatively. In the presence of lymphatic oedema or lymphadenopathy at the splenic hilum, endosurgical staplers may fail to tightly control the vessels since the approximation of the two branches of the stapler is inadequate if the splenic hi-

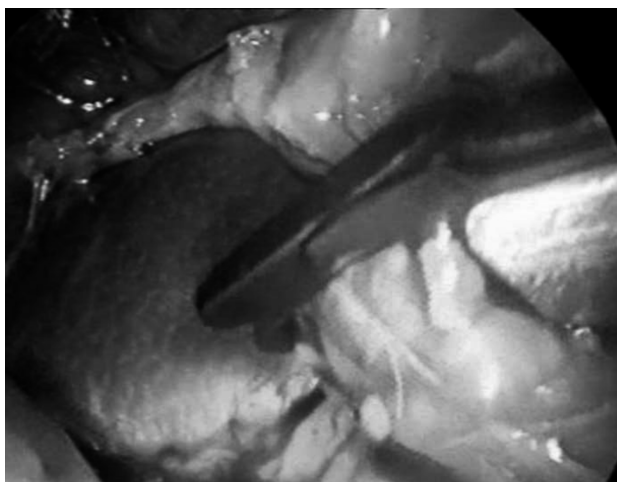


Fig. 1 - Clipping of the splenic artery.

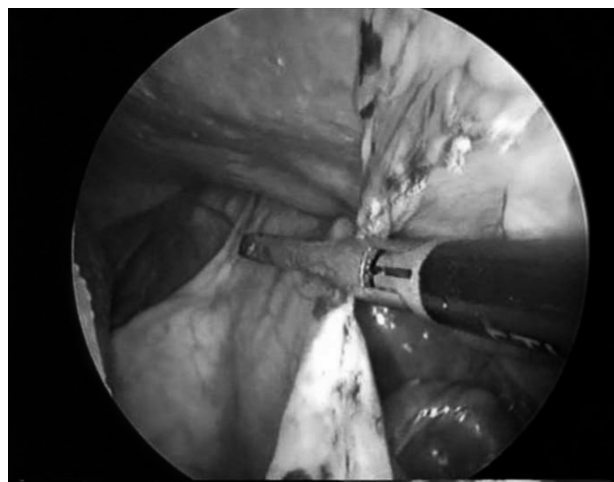


Fig. 2 - Dissection of short gastric vessels.

lum is not slim. In these cases in our opinion it is probably better to ligate with intracorporeal suture the hilum vessels or their branches.

The knowledge of all these factors is important to make the splenectomy safe, as it is the perfect knowledge of the anatomy of spleen and its vessels. When performing LS it is important to remember that the splenic vessels may show several anatomic patterns. In 70% of cases the artery splits itself at level of pancreatic tail into 2 or more branches; in the remaining cases the artery runs on the edge of the pancreas and approaches the hilum of the spleen without dividing. Various are also the relationships between the artery and the splenic vein. In 54% of cases the vein is behind and below the artery; in 44% of cases the vein surrounds the artery, and only in 2% of cases the vein is in front of the artery. It is also important not to forget that the gastro-splenic ligament is sometimes very short and therefore the short gastric vessels may be at risk of tearing and haemorrhage during their dissection while performing LS.

The occurrence of bleeding during LS is also related to the experience of the surgical team (15, 19). In meta-analysis study on 2119 LS, it has been noted a difference in the rate of bleeding during the initial experience of the reported series (15). Based on the date of study inception, in the first one third group the rate of conversion for bleeding was 6.1%, while in the second and last third groups it was respectively 3.6 and 2.4%, with a significant difference ($p < 0.0001$) comparing the groups (15).

An appropriate technique of LS, in our opinion, significantly reduces the incidence of bleeding during surgery. We perform LS with patients lying in the right lateral position (left flank elevated about 45° above the operating table).

An Hasson-trocar is inserted in the up-umbilical re-

gion and three other trocars are placed in the subxyphoid area (5 mm), lower left midclavicular line below the umbilical line (10-12 mm) and lower left axillary line (5 mm). With a 30° scope, after dissection of the spleno-colic ligament, division of the gastrosplenic ligament with the short gastric vessels is accomplished using the ultrasonic dissector (Ultracision Harmonic Scalpel, Ethicon Endosurgery, Inc. Cincinnati, OH USA) (Fig. 2).

The convex surface of the spleen is then accurately dissected from the lateral abdominal wall and from the diaphragm; at this point, the splenic hilum is approached from the anterior aspect and the splenic artery and veins are clipped and divided, either using a laparoscopic stapler or separated sutures. The spleen is then inserted in a plastic bag which is pulled through the abdominal umbilical access. The spleen is finally crushed and removed. Using this approach we have performed (64) with an incidence of intraoperative bleeding of approximately 6.7%. The lateral position of the patient is in our opinion essential for a good exposure of the short gastric vessels and of the splenic hilum, therefore helping prevent bleeding related to their accidental damage. In addition to the steps described above, in large spleen we prefer to clip the splenic artery above the pancreatic tail before reaching the splenic hilum and this approach in our opinion, as we already mentioned, may reduce perioperative bleeding.

Pancreatic injury (pancreatitis, subphrenic abscess)

Pancreatic injury is one the major and severe complications after splenectomy. In open surgery pancreatic injury incidence is as high as 16%. In laparoscopic splenectomy we have only few data on these complica-

tions. In reviews of laparoscopic splenectomy this incidence may be as low as 1-2%. Kathouda et al observed only 2 mild pancreatitis cases among 103 consecutive splenectomies (13).

Pancreatic injury may occur because of the anatomical relationship of splenic hilum with the tail of pancreas. Baronofsky et al demonstrated that the pancreatic tail lies within 1 cm away from the splenic hilum in 75% of the patients; it touches the splenic hilum in 30% of these patients (20). Besides the anatomic tight relationship, there are some certain difficulties during surgery that may induce pancreatic damage. Risk of pancreatic injuries may increase in patients with lymphedema in the splenic ilium, especially in patients with lymphoma and hilar lymphadenopathy where the dissection plan is not clear. Difficult control of the splenic hilum vessels with intraoperative bleeding may be another reason since in these cases pancreatic injuries can be caused by uncontrolled haemostasis techniques (21). Another reason hilum is the malpositioning of the linear stapler device for hilum control, since the insufficient dissection of the hilar vessels and lower placement of the hilum stapler may cause damage to the pancreatic tail. This usually may occur in large spleens due to large splenic hilum (22). Chand et al in their article discussing pancreatic complications after laparoscopic splenectomy, reported that splenomegaly seems to be the only associated risk factor for pancreatic injury. On the other hand, they also claim that pancreatic injury risk is not related to the learning curve of the surgical team.

Diagnosis of pancreatic injuries is sometimes underestimated. Chand et al advocated that if routine postoperative amylase level is measured in splenectomized patients minor asymptomatic pancreatic injuries may be defined (22). However, the significance of elevated serum amylases in asymptomatic splenectomized patients to determine pancreatic injuries is not well defined with comparative study. Common clinical findings of pancreatic injury are abdominal pain (more than expected and long-lasting), fever, incisional erythema. In addition to hyperamylasemia, lab tests will show leukocytosis. Any suspicion of pancreatic damage must lead the surgeon to perform an abdominal CT of the patient. In CT scan pancreatic edema or necrosis, peripancreatic fluid collection and subphrenic abscess caused by pancreatic leakage can be clearly identified. Depending on the grade of injury, the CT findings may show swelling of the tail of the pancreas, ill-defined fluid collections, or a well-encapsulated pancreatic pseudocyst. The diagnosis is confirmed by percutaneous aspiration with amylase determinations and the demonstration of a pancreatic fistula.

Failure to diagnose this complication promptly may lead to a protracted postoperative clinical course and the

development of a subphrenic abscess or a pancreatic pseudocyst (23).

The treatment of pancreatitis consist of IV fluid replacement and nasogastric decompression and sometimes percutaneous drainage. Mild pancreatitis with minimal peripancreatic collection can be treated with oral diet cessation and IV fluid replacement while diffuse peritoneal fluid or abscess formation should be percutaneously drained. Drain cultures may guide the surgeon to choose the appropriate antibiotic in patients with high fever and leucocytosis. Rarely, percutaneous drainage for multiloculated abscesses may not be satisfactory and require open or laparoscopic surgical drainage (24). Since all these patients are asplenic, physicians should never forget the risk overwhelming sepsis.

Park mentioned the importance of the technique in the prevention of pancreatic injury. In his review, he advocates that hilum dissection and the proper stapler position is the key points to minimize the risk of pancreatic tail injury.

Prevention of this complication is easier in lateral approach than anterior approach since the relationship between pancreatic tail and the splenic hilum is more evident in the former positioning of the patient. In laparoscopic surgery magnification of the anatomical view during surgery provides the surgeon a good exposure for dissection of the pancreatic tail away from hilum, avoiding its injury. In our series, with the technique we described above, we haven't observed any complication related to pancreatic injury. Key point in our technique not to have any problem with the pancreatic tail is a complete dissection of the splenic hilum and the use of a stapler just after a complete visualization of the pancreatic tail gland. To prevent unintentionally stapler damage we usually stop hanging up the spleen just before firing the device, in order to allow the fall of the pancreatic tail away from the stapler line (Fig. 3).

Intra-operative iatrogenic injuries

Besides pancreatic injuries, which have been already discussed in a previous paragraph of this review, other iatrogenic injuries related to the procedure can occur during the performance of laparoscopic splenectomy. Due to the anatomical vicinity of the spleen to the splenic flexura of the colon, stomach and diaphragm injuries of these structures are sometimes possible during laparoscopic splenectomies. Although there is no clear reported result about incidence of these iatrogenic injuries, extracted data from large splenectomy series show an incidence which is similar to that described in open surgery. It is the most common iatrogenic organ injury after pancreas and its incidence ranges between 0% and 14 % (13, 17, 25). In most of literature series, injuries

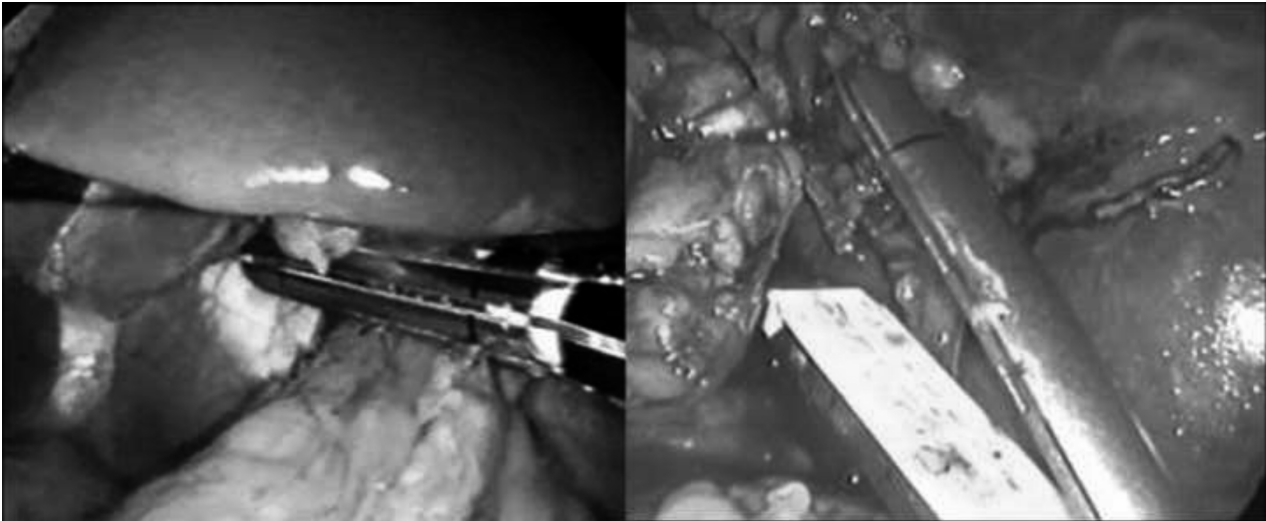


Fig. 3 - Ligation of the splenic vessels with an endo-vascular stapler.

to diaphragm are not mentioned (13,15). Possible aetiology of diaphragmatic injury is an inappropriate dissection of the superior pole of the spleen from the diaphragmatic attachments.

More commonly injury to diaphragm is the result of a dissection in cases with inflammatory or neoplastic peri-splenitis, like we observed in one of our series (Fig. 4) (26).

Lesions in the diaphragm need to be recognized intraoperatively, since immediate repair during the laparoscopic procedure responsible for them, is essential. Either laparoscopically or after conversion to open surgery, repair of the lesion must be accomplished with closure of the defect in the diaphragm. A thoracic drain must also be used to prevent postoperative pneumothorax and related complications, such as pleural effusion or empyema which can be a serious problem in asplenic patients.

Gastric perforation is a rare complication during open splenectomies and it accounts for less than 1% (27). This injury may occur mainly during the dissection of gastro-splenic ligament and ligation of short gastric vessels over the great curvature of the stomach. Risk of gastric perforation exists also in laparoscopic splenectomy especially in patients with very short gastric vessels. In our opinion and experience, however, in laparoscopic surgery the risk is probably less than in open surgery, since the mini-invasive procedure allows excellent exposure and magnification of the vision in these deep and dark areas of the operative field when compared to traditional operations.

Prevention of iatrogenic lesions in the stomach requires attention in the dissection particularly near the upper pole of the spleen where occasionally stomach wall and spleen look like adhered. Gentle and careful dis-

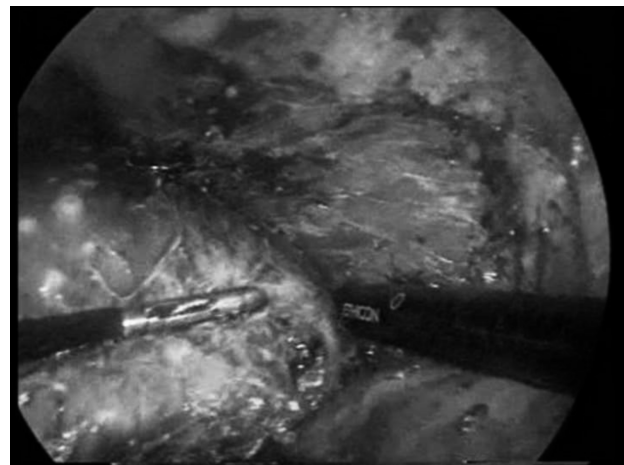


Fig. 4 - A perisplenitis view of a laparoscopic splenectomy case.

section of the gastro-splenic ligament depends on well balanced traction forces on stomach and spleen, and this is also to prevent laceration of the splenic capsule. The appropriate use of haemostatic equipment is also important. High energy bipolar systems or ultrasonic dissectors are very useful but they should be used cautiously in order not to harm gastric wall. Like for other iatrogenic surgical injuries, intraoperative detection of the lesions is essential. Gastric iatrogenic injuries can be repaired safely laparoscopically (28). Missed gastric injuries are responsible of severe post-operative peritonitis, which need to be recognized and treated with re-operation of the-patient as soon as possible. Boddy et al reported a missed gastric injury that was re-operated on the 8th postoperative day (29). Although these are very rare cases, surgeons should always be aware of the risk of these severe injuries.

In English literature, there are no reported perioperative splenic flexura injuries during laparoscopic splenectomies. In spite of its close relationship through splenocolic ligament, colonic injuries are not reported in any of the large laparoscopic splenectomy series. These data may be debatable since the authors may not mention their perioperative injuries which are repaired at the time of operation.

Another not well recognized intraoperative iatrogenic injury is laceration of the spleen with occurrence of splenosis. Splenosis is the accidental *heterotopic* auto-transplantation of splenic tissue generally following traumatic rupture of the spleen or the splenic capsula. Implantation of splenic tissue may occur anywhere in the abdomen, rarely intrathoracic, intrahepatic, or in the inguinal ring and subcutaneous spaces (30).

Splenosis can occur any time during either open or laparoscopic removal of the spleen.

Tears of the spleen can happen during the initial steps of the procedure or after splenectomy when the surgeon is removing from the abdomen the organ. Although this entity is rare after open splenectomy (16%-17%) it can be encountered after laparoscopic surgery (30). No data still exist on the long term risk of splenosis in laparoscopic splenectomy. Some Authors (Espert et al.) argue that the laparoscopic approach may increase splenosis because of pneumoperitoneum. This is reported by Espert et al in rat model of splenosis. They claimed that after capsular tear in laparoscopic splenectomy the risk of splenosis is much more than open surgery (31).

Symptoms related to splenosis may appear soon after surgery or even 29 to 31 years after the initial splenectomy. In patients who have undergone splenectomy for haematological diseases, recurrence of the disease may be an indicator of splenosis, when the presence of residual accessory spleen can be rule out. Besides these mentioned signs, pain or unexplained intraluminal or peritoneal bleeding in patients previously splenectomized could be clinical signs of splenosis.

Diagnosis can be made with MRI and CT scan (30,

31). However, technetium scanning is the best method to detect the splenosis foci (32).

Surgical treatment for splenosis is indicated in case of recurrence of the hematologic disorder, for which splenectomy was first performed, or in symptomatic patients. The surgical treatment consists of the clearance of the splenic residual tissue. However, since splenosis is the result of spilled splenocytes after the operation, there will always be a risk of new splenosis foci after the surgical treatment. The miniminvasiveness of laparoscopic surgery may be responsible of less post-operative adhesion and, therefore, this approach is to prefer to open surgery for removal of splenosis tissue. Besides it must to be considered that a recurrence risk of new splenosis foci may occur in patient-life and further operations may be predicted (33).

The gentle manipulation during procedure without capsular tear and the removal of the specimen with a durable and impermeable bag are the mandatory steps for the prevention of splenosis during laparoscopic splenectomy. The morcellation process could be potential risk factor for splenosis since perforation of the removal bag can occur. For this reason we prefer not to use this device, but instead we usually fragmentise the spleen with surgical forceps inside the removal bag. In conclusion the above mentioned risks and intra- or post-operative complications should not discourage the minimal invasive surgeons who are willing to perform laparoscopic splenectomy.

Conclusion

Knowledge of anatomical details, associated with appropriate surgical training and skills, the use of proper equipment are the sine-qua-non conditions of this specific procedure. Although limits in laparoscopic splenectomy changes everyday, beginners should never ignore the possibility of complications and they had better known preventions and their treatments.

References

1. Delaitre B, Maignien B, Icard P. Laparoscopic splenectomy. *Br J Surg*. 1992;79(12):1334.
2. Wichmann MW, Hurtl TP, Winter H, Spelsberg F, Angele MK, Heiss MM, Jauch KW. Immunological effects of laparoscopic vs open colorectal surgery: a prospective clinical study. *Arch Surg* 2005;140(7): 692-7.
3. Vecchio R, Cacciola E, Lipari G, Privitera V, Polino C, Cacciola R. Laparoscopic splenectomy reduces the need for platelet transfusion in patients with idiopathic thrombocytopenic purpura. *JLS* 2005;9(4): 415-8.
4. Friedman RL, Hiatt JR, Korman JL, Facklis K, Cymerman J, Phillips EH. Laparoscopic or open splenectomy for hematologic disease: which approach is superior? *J Am Coll Surg* 1997;185(1): 49-54.
5. Brunt LM, Langer JC, Quasebarth MA, Whitman ED. Comparative analysis of laparoscopic versus open splenectomy. *Am J Surg* 1996;172(5):596-9; discussion 599-601.
6. Stanton CJ. Laparoscopic splenectomy for idiopathic thrombocytopenic purpura (ITP). A five-year experience. *Surg Endosc* 1999;13(11): 1083-6.
7. Flowers JL, Lefor AT, Steers J, Heyman M, Graham SM, Imbembo AL. Laparoscopic splenectomy in patients with hema-

- tologic diseases. *Ann Surg* 1996;224(1):19–28.
8. Smith CD, Meyer TA, Goretsky MJ, Hyams D, Luchette FA, Fegelman EJ, Nussbaum MS. Laparoscopic splenectomy by the lateral approach: a safe and effective alternative to open splenectomy for hematologic diseases. *Surgery* 1996;120(5):789–94.
 9. Glasgow RE, Yee LF, Mulvihill SJ. Laparoscopic splenectomy. The emerging standard. *Surg Endosc* 1997;11(2): 108–12.
 10. Brody FJ, Chekan EG, Pappas TN, Eubanks WS. Conversion factors for laparoscopic splenectomy for immune thrombocytopenic purpura. *Surg Endosc* 1999;13(8):789–91.
 11. Schlachta CM, Poulin EC, Mamazza J. Laparoscopic splenectomy for hematologic malignancies. *Surg Endosc* 1999;13(9):865–8.
 12. Bresler L, Guerci A, Brunaud L, Ayav A, Sebbag H, Tortuyaux JM, Lederlin P, Boissel P. Laparoscopic splenectomy for idiopathic thrombocytopenic purpura: outcome and long-term results. *World J Surg* 2002;26(1): 111–4. Epub 2001 Nov 26.
 13. Katkhouda N, Hurwitz MB, Rivera RT, Chandra M, Waldrep DJ, Gugenheim J, Mouiel J. Laparoscopic splenectomy: outcome and efficacy in 103 consecutive patients. *Ann Surg* 1998;228(4): 568–78. Review.
 14. Caprotti R, Porta G, Franciosi C, Codecasa G, Romano F, Musco F, Uggeri F. Laparoscopic splenectomy for hematological disorders. Our experience in adult and pediatric patients. *Int Surg* 1998;83(4): 303–7.
 15. Winslow ER, Brunt LM, Drebin JA, Soper NJ, Klingensmith ME. Portal vein thrombosis after splenectomy. *Am J Surg* 2002 Dec;184(6): 631–5; discussion 635–6.
 16. Targarona EM, Espert JJ, Balague C, Piulachs J, Artigas V, Trias M. Splenomegaly should not be considered a contraindication for laparoscopic splenectomy. *Ann Surg* 1998;228(1):35–9.
 17. Targarona EM, Espert JJ, Cerdan G, Balague C, Piulachs J, Sugranes G, Artigas V, Trias M. Effect of spleen size on splenectomy outcome. A comparison of open and laparoscopic surgery. *Surg Endosc* 1999;13(6):559–62.
 18. Hebra A, Walker JD, Tagge EP, Johnson JT, Hardee E, Otherson HB Jr. A new technique for laparoscopic splenectomy with massively enlarged spleens. *Am Surg* 1998;64(12):1161–4.
 19. Gigot JF, Jamar F, Ferrant A, van Beers BE, Lengele B, Pauwels S, Pringot J, Kestens PJ, Gianello P, Detry R. Inadequate detection of accessory spleens and splenosis with laparoscopic splenectomy. A shortcoming of the laparoscopic approach in hematologic diseases. *Surg Endosc* 1998;12(2):101–6.
 20. Baronofsky ID, Walton W, Noble JF. Occult injury to the pancreas following splenectomy. *Surgery* 1951;29(6):852–7.
 21. Barbaros U, Dincag A, Deveci U, Akyuz M, Tukenmez M, Erbil Y, Mercan S. ‘Use of electrothermal vessel sealing with LigaSure device during laparoscopic splenectomy’. *Acta Chir Belg* 2007;107(2):162–5.
 22. Chand B, Walsh RM, Ponsky J, Brody F. Pancreatic complications following laparoscopic splenectomy. *Surg Endosc* 2001;15(11):1273–6. Epub 2001 Sep 4.
 23. Balthazar EJ, Hilton S, Naidich D, Megibow A, Levine R. CT of splenic and perisplenic abnormalities in septic patients. *AJR Am J Roentgenol* 1985;144(1):53–6.
 24. Donini A, Baccarani U, Terrosu G, Corno V, Ermacora A, Pasqualucci A, Bresadola F. Laparoscopic vs open splenectomy in the management of hematologic diseases. *Surg Endosc* 1999;13(12):1220–5.
 25. Shimomatsuya T, Horiuchi T. Laparoscopic splenectomy for treatment of patients with idiopathic thrombocytopenic purpura. Comparison with open splenectomy. *Surg Endosc* 1999;13(6):563–6.
 26. Vecchio R, Cacciola E, di Martino M, Cacciola RR, MacFadyen BV. A cause for conversion of laparoscopic splenectomy: splenic candidiasis. *J Laparoendosc Adv Surg Tech A*. 2002;12(6):441–4.
 27. Martinez CA, Waisberg J, Palma RT, Bromberg SH, Castro MA, Santos PA. Gastric necrosis and perforation as a complication of splenectomy. Case report and related references. *Arq Gastroenterol* 2000;37(4): 227–30. Epub 2001 Dec 5.
 28. Rosen M, Brody F, Walsh RM, Tarnoff M, Malm J, Ponsky J. Outcome of laparoscopic splenectomy based on hematologic indication. *Surg Endosc*. 2002 ;16(2):272–9. Epub 2001 Nov 12.
 29. Boddy AP, Mahon D, Rhodes M. Does open surgery continue to have a role in elective splenectomy? *Surg Endosc* 2006;20(7):1094–8. Epub 2006 May 13.
 30. Barbaros U, Dincag A, Kabul E. Minimally invasive surgery in the treatment of splenosis. *Surg Laparosc Endosc Percutan Tech*. 2006;16(3):187–9.
 31. Espert JJ, Targarona EM, Bombuy E, Setoain J, Visa J, Trias M. Evaluation of risk of splenosis during laparoscopic splenectomy in rat model. *World J Surg*. 2001;25(7):882–5.
 32. Ribeiro JC, Silva CM, Santos AR. Splenosis. A diagnosis to be considered. *Int Braz J Urol* 2006;32(6):678–80.
 33. Barbaros U, Dincag A, Erbil Y, Mercan S, Sanli Y, Adalet I, Kucukkaya R. Handheld gamma probe used to detect accessory spleens during initial laparoscopic splenectomies. *Surg Endosc* 2007;21(1):115–9. Epub 2006 Sep 6.