

The use of *pectoralis major* myocutaneous flap as “salvage procedure” following intraoral and oropharyngeal cancer excision

S. CHIUMMARIELLO, M. IERA, A. DOMATSOGLU, C. ALFANO

SUMMARY: The use of *pectoralis major* myocutaneous flap as “salvage procedure” following intraoral and oropharyngeal cancer excision.

S. CHIUMMARIELLO, M. IERA, A. DOMATSOGLU, C. ALFANO

Background. *The benefits and superiority of free flaps for head and neck reconstruction are well recognized. However, in some instances, especially in elderly and critical patients with advanced intraoral and oropharyngeal cancers or in patients with underlying systemic syndromes (i.e. uncontrolled diabetes, cardio-pulmonary failure, renal insufficiency), the use of pectoralis major myocutaneous flap may be a preferable option with fewer risks for the patient.*

Patients and methods. *We present a series of 12 pectoralis major myocutaneous flaps, performed from January 2007 to June 2008, in 12 critical patients who presented with advanced carcinomas of the oral cavity and oropharynx. In all cases, histology showed (T3-T4)-(N0-N3)-M0 squamous cell carcinomas. Tumors were: 4 intraoral (33%), 2 in the oropharynx (16%), 5 in the hypopharynx (41%) and 1 of the skin left auricle (8%).*

Results. *There were no flap loss. Partial skin necrosis (<10%) occurred in 1 case (8%); one patient (8%) developed wound infection treated successfully with systemic antibiotic therapy. Minor orocutaneous fistulas developed in 2 patients (16%). At the follow-up 4 patients (34%) died after 4 months, 2 patients (16%) had recurrence of disease, 6 patients (50%) showed no evidence of disease.*

Conclusion. *The use of pectoralis major myocutaneous flap as a salvage procedure in immediate reconstruction following ablative surgery of head and neck cancers is still a valid alternative procedure to free tissue transfer. Because of reduced operative times, reduced anaesthetic risk, reduced risk of total flap necrosis and reduced costs, it could be considered as a preferable choice in selected cases.*

RIASSUNTO: Utilizzo del lembo miocutaneo di gran pettorale come “procedura di salvataggio” dopo escissione di carcinoma del cavo orale dell’ipofaringe.

S. CHIUMMARIELLO, M. IERA, A. DOMATSOGLU, C. ALFANO

Introduzione. *I vantaggi e la superiorità dei lembi liberi nella ricostruzione di cavo orale ed ipofaringe sono ben riconosciuti. Anche se, in alcune circostanze, come nel caso di pazienti anziani, defedati, con carcinomi in stadio avanzato e affetti da malattie sistemiche, si preferisce l’uso del lembo peduncolato muscolocutaneo di gran pettorale poiché si espone a minori rischi il paziente.*

Pazienti e metodi. *Presentiamo 12 casi di ricostruzioni con lembo di gran pettorale eseguite, da gennaio 2007 fino a giugno 2008, in 12 pazienti che risultavano affetti da carcinoma avanzato del cavo orale ed orofaringe. Dall’istologia è emerso che tutti i tumori erano squamocellulari (T3-T4)-(N0-N3)-M0. I tumori erano localizzati: 4 nel cavo orale (33%), 2 nell’orofaringe (16%), 5 in ipofaringe (41%) e solo 1 era cutaneo a livello dell’orecchio sinistro (8%).*

Risultati. *Non ci sono state necrosi totali del lembo. Una necrosi parziale del lembo si è verificata in un solo caso (8%); in un solo paziente (8%) si è verificata infezione della ferita che è stata trattata con terapia antibiotica locale. Fistole orocutanee minori si sono sviluppate in 2 pazienti (16%). Per quanto riguarda il follow-up, 4 pazienti (34%) sono morti a distanza di 4 mesi, 2 (16%) hanno avuto una recidiva, 6 (50%) non mostrano nessun segno di malattia.*

Conclusione. *L’uso del lembo miocutaneo di gran pettorale nella ricostruzione del cavo orale come metodica di salvataggio dopo chirurgia ablattiva è ancora una valida alternativa al lembo libero. In casi selezionati tale lembo di gran pettorale diventa un lembo di prima scelta perché ha tempi operatori, rischio anestesiológico, costi e rischio di necrosi totale ridotti.*

KEY WORDS: Pectoralis major myocutaneous flap - Elderly and critical patients - Head and neck - Squamous cell carcinomas.
Lembo muscolo-cutaneo di gran pettorale - Pazienti anziani e defedati - Capo e collo - Carcinoma cellulare squamoso.

Introduction

Since the 1980s, several authors have supported the usefulness and superiority of free tissue transfer for head and neck reconstruction (1-5). Surgeons who prefer the free flap underline that, amongst other advantages, they

achieve better functional and cosmetic results and have less donor-site morbidity and complications (7-8).

In some instance, though, especially in elderly and critically ill patients with infiltrating intraoral and oropharyngeal cancers or in patients with underlying systemic syndromes (for example diabetes, artery hypertension, etc.), the use of the pectoralis major flap not only represents an alternative to free tissue transfer, but a preferable option, with fewer risks for the patient.

For such patients we routinely prefer to utilize the pectoralis major flap for salvage and immediate reconstruction after ablation of cancer in the oral cavity or oropharynx for many reasons: the mean operative time of the reconstruction with the pectoralis major musculo-cutaneous flap is markedly shorter than that of a free flap, the pectoralis flap technique implies less surgical burden for the patient. In addition, the pectoralis major myocutaneous flap is fast, reliable and has a dependable axial vascularization provided by the thoracoacromial artery and it yields sufficient tissue for most oropharyngeal reconstructive procedures (6-7-13-18).

At the Department of Plastic and Reconstructive Surgery of University of Perugia, Italy, in cooperation with the Ear, Nose and Throat Department of Santa Maria Hospital, Terni, head and neck surgeons and plastic surgeons are engaged in a team approach for the resection and reconstruction of patients with head and neck carcinomas. From January 2007 to June 2008 pectoralis major flaps were used for salvage in 12 patients with intraoral or oropharyngeal cancer to reconstruct their defects.

The purpose of this study is to analyse the reliability of the pectoralis major myocutaneous flap in the immediate post-oncology head and neck reconstruction for salvage.

Patients and methods

We present a review of our experience with 12 pectoralis major myocutaneous flaps, which we performed over a period of 17 months, in 12 critically ill patients who presented with carcinomas of the oral cavity and oropharynx (Table 1). All the pectoralis major flaps were performed with the same technique and by the same team of surgeons. Eight patients were male and 4 were female and their age ranged between 56 and 85 years (median age 67 years).

In all cases histology showed squamous cell carcinomas. Tumors were intraoral in 4 cases (33%); 3 of these tumors were on the floor of the mouth, in the region of the right gum (stage T3 N2c M0, and were treated by anterior pelvic-glossectomy, marginal mandibulectomy and bilateral laterocervical lymphadenectomy, level I-V); one of the intraoral tumors rose from the right hemimandible, (stage T4 N2b M0, and was treated by a segmentary pelvic-mandibulectomy with radical modified right laterocervical lymphadenectomy). In 2 cases (16%) the tumors were located in oropharynx (retromolar trigon and right tonsillar loggia, stage T4 N2c M0, and were treated by right hemimandibulectomy and radical bilateral laterocervical lymphadenectomy of third type) (Figs. 1-2).

TABLE 1 - LOCALIZATION OF TUMORS.

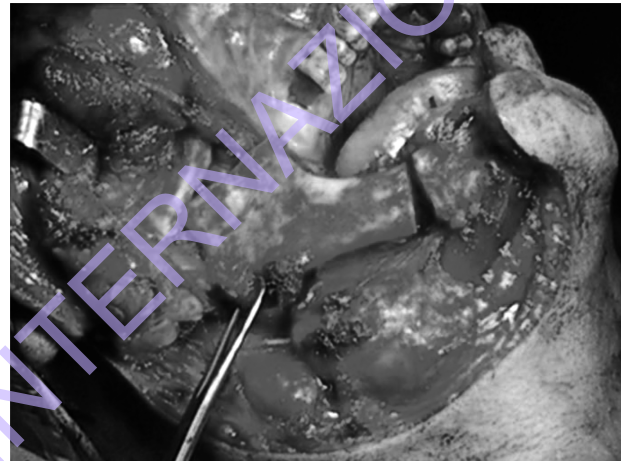
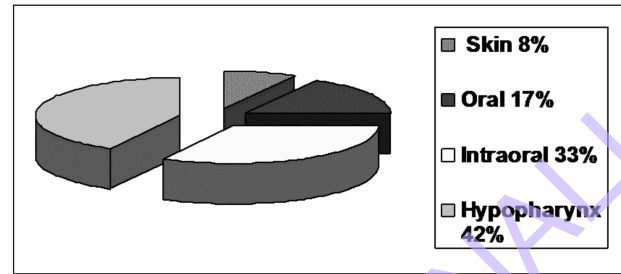


Fig 1 - Right hemimandibulectomy and radical bilateral laterocervical lymphadenectomy (of third type) in patient with squamous cell carcinoma of the oropharynx (retromolar trigon and right tonsillar loggia, stage T4 N2c M0).

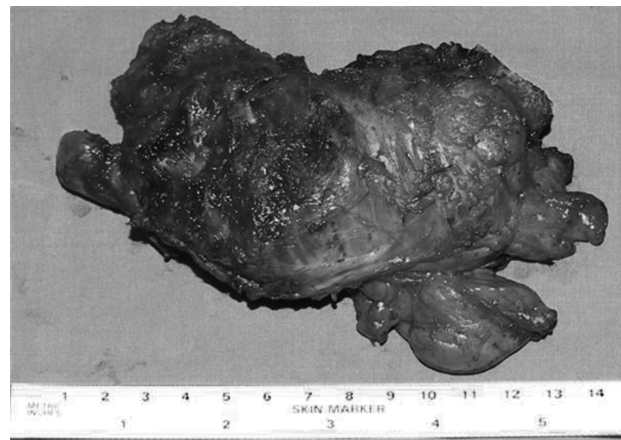


Fig 2 - Case in fig. 1 - Operative specimen.

In 5 cases (41%) the tumors were located in the hypopharynx, in 3 patients the tumors occurred in the left hemilarynx and circular hypopharynx (stage T4 N0 M0, and were treated by total pharyngolaryngectomy and hypopharyngeal circular resection); in 2 patients the tumors occurred in the right piriform sinus and in the right lateral wall of hypopharynx (stage T4 N3 M0, and were treated by total pharyngolaryngectomy and radical laterocervical lymphadenectomy, level II-V). Skin tumors occurred in only 1 case (8%), ari-

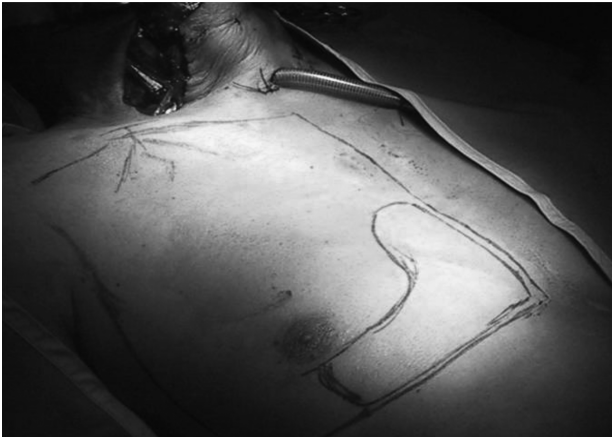

Fig 3 - Preoperative design of "invert L" skin paddle.

sing from the left auricle (stage T3 N0 M0, this case was treated by resection of auricle and of the left mastoid region, external face parotidectomy and modified selective laterocervical lymphadenectomy of third type).

Eleven patients (91%) had a history of extensive tobacco use (at least two packets of cigarettes daily); 5 patients (5%) were chronic drinkers (about 1 litre of wine every day). Only 1 patient (8%) was a non-smoker and non-drinker (Table 2).

In 5 cases (41%), the surgical resection and reconstruction was performed in patients who had already undergone a previous surgical excision and a course of radiotherapy.

Mean hospital stay for these patients was in line with our expectations and ranged between 7 to 9 days for 11 patients (91%). In 1 case only the patient had to be hospitalized for a longer period of time (18 days). All the pectoralis major myocutaneous flaps reconstructions were performed with the same technique and by the same team of surgeons. A thorough pre-operative evaluation of all patients was performed. It has been demonstrated that extremely meticulous surgical techniques and refined strategies for flap design the survival rate of the flap to close to 100%.

The patient is positioned supine on the operating table with his shoulders abducted to 90° and his arms stretched out. The skin is incised deeply, along the previously marked pectoral skin paddle, through subcutaneous fat, down to pectoral fascia (Fig. 3).

The incision down to the fascia is oblique, so to include more perforators from the muscle. The skin island is tightened to the muscle with absorbable sutures to protect it during operative handling. The flap is initially sculptured distally, proceeding in a cephalad direction up to the origin of the pectoral branch of the thoracoacromial artery. To reach the defect to be reconstructed the flap is mobilized, elevated and rotated 180° on its pedicle (Fig. 4). It may pass over the clavicle subcutaneously or it may transit under the clavicle through a previously obtained tunnel. The flap was placed into the defect and sutured in two layers (Fig. 5).

For the circular reconstruction of the hypopharynx a myocutaneous flap of considerable dimensions has to be used, long enough to be rolled on itself on to a catheter to form a neo-lumen (16-25).

When small flaps are used, primary closure of the donor site is possible, in other cases closure is obtained either by means of a skin graft or with a local flap (Fig. 6).

Results

The analysis of these 12 cases shows that a total ne-

TABLE 2 - RISK FACTORS.

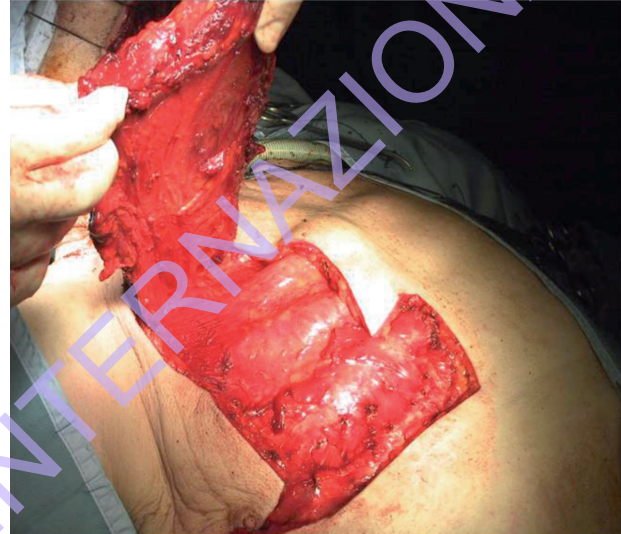
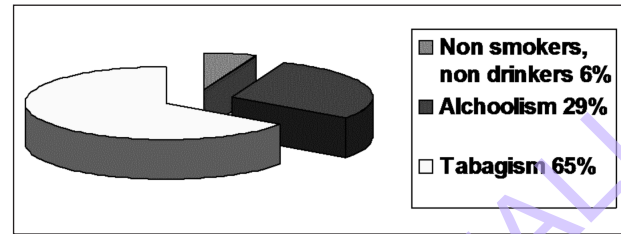


Fig 4 - Pectoralis major myocutaneous flap is elevated on its pedicle.

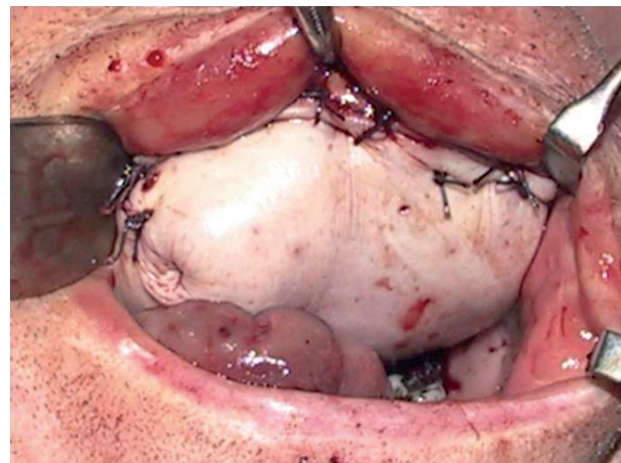


Fig 5 - Immediate postoperative result after ablation of squamous cell carcinoma located on the floor of the mouth, right gingival region (stage T3 N2c M0, treated by anterior pelvy-glossectomy, marginal mandibulectomy and bilateral laterocervical lymphadenectomy, level I-V).

crosis of the flap did not occur in any of the patients, and in no instances was a second operation necessary for complications related to the flap.

A partial skin necrosis occurred in 1 case (8%); the

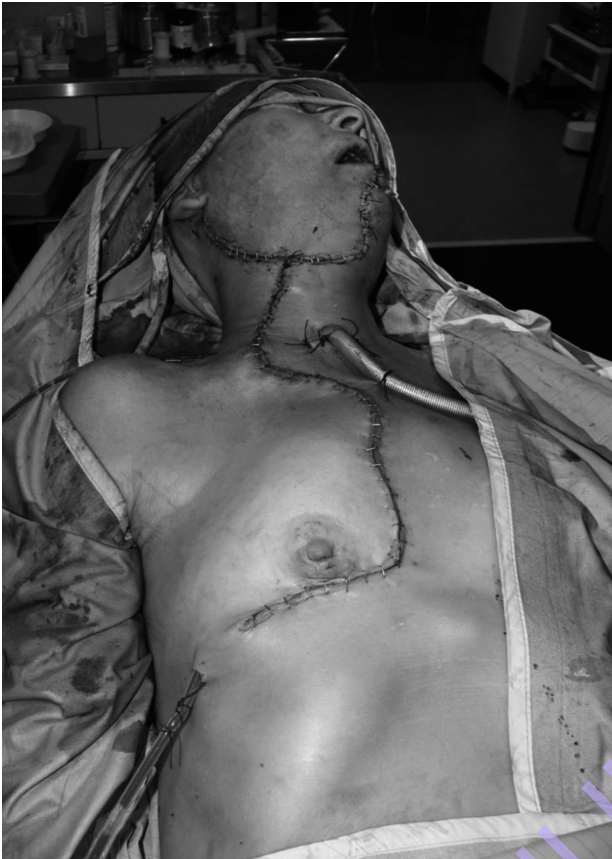

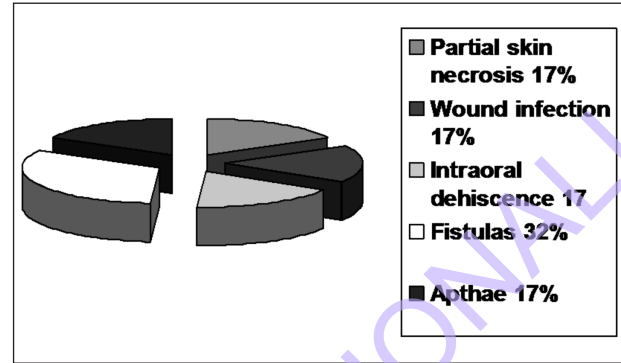
Fig. 6 - Immediate postoperative result after ablation of squamous cell carcinoma of the oropharynx (retromolar trigon and right tonsillar loggia, stage T4 N2c M0, treated by right hemimandibulectomy and radical bilateral laterocervical lymphadenectomy of third type). Reconstruction with pectoralis flap and primary closure of donor defects.

area of necrosis was relatively small and was managed conservatively. One patients (8%) developed an infection of the wound that was treated with antibiotic therapy. An intraoral dehiscence occurred in one case (8%); it healed without a secondary procedure. Minor oro-cutaneous fistulas were developed in 2 patients (16%), both of which healed spontaneously. One patient (8%) developed an aphthous lesion of the margin of the tongue whose biopsy was negative. The lesion regressed spontaneously (Table 3). In 8 patients (66%) no complications were registered.

For what the donor site is concerned, no significant complications occurred following the normal clinical course. The occurrence of complications can be correlated to various risk factors including:

- age (older than 65);
- gender (male have a higher risk than females);
- tabagism and alcoholism;
- primary site of the tumor (more frequent rate of complications in the hypopharynx);

TABLE 3 - COMPLICATIONS.

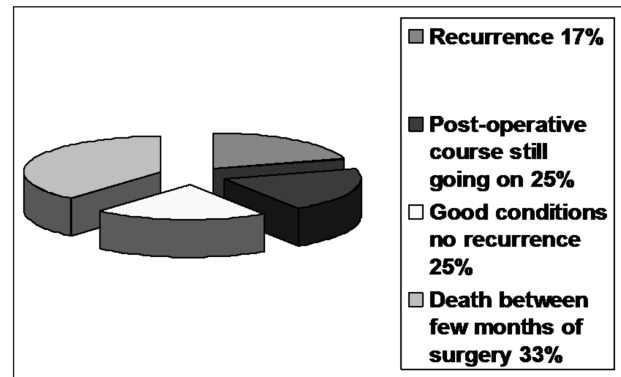


- stage of the tumor;
- location of cancer (bigger complications in ipopharynx);
- coexistence of the underlying systemic disorders (diabetes, hypertension and atherosclerotic cardiovascular pathologies);
- low albumin and haemoglobin levels;
- prolonged hospital stay (>15 days)
- previous radiotherapy of the interested area;

Operative time for the pectoralis major musculocutaneous flap ranged from 60 to 110 minutes, with a mean operative time of 85 minutes.

At follow-up (Table 4), 4 patients (33%) died within few months of the operation (between 2 and 4 months-2 for local and systemic diffusion of the cancer and 2 for causes that were independent of the primary pathology). Two patients (16%) had a recurrence of the disease and, at the time of this writing are still receiving treatment. Three patients (25%), at months 9, 10, and 15 respectively after surgery, are in good conditions and have not shown signs of recurrence of the primary disease. In three other cases (25%) the normal post-operative treatment course is still going on.

TABLE 4 - FOLLOW-UP.



Discussion

Reconstruction of the oral cavity and oropharyngeal defects is a challenging task for the variety of anatomic structures and complexity of functions involved. Free tissue transfer with microsurgical anastomosis has become the procedure of choice for most patients and in most situations (9, 10, 12, 15, 17, 22). However, free tissue transfer deserves some consideration with regard to the condition of the patient, the operative time required to perform the procedure and technique being used. The operation is complex and lengthy and requires sophisticated equipment: it is therefore located at the top of the so called "reconstructive ladder"- the algorithm for tissue reconstruction that suggests that defects should be reconstructed with the least invasive option available that will produce successful results. This implies that in considering options for reconstruction, it is important to be mindful of the global health status of the patient, as well as of the overall defect, and there are conditions in which the benefits of a complex and lengthy procedure may not markedly outweigh the disadvantages.

In elderly and critically ill patients with infiltrating intraoral and oropharyngeal cancers or in patients with underlying systemic syndromes (for example diabetes, artery hypertension, etc.), the use of a pedicle pectoralis major flap may not only represent an alternative to free tissue transfer, but a preferable option, with fewer risks for the patient.

The 12 patients on which we have conducted the present study failed to meet the appropriate criteria to undergo a complex microsurgical procedure and presented most of the underlying conditions that predispose a patient to complications. These adverse findings are in accordance with the observation that carcinomas of the oral cavity tend to occur more frequently in patients with other medical problems. The patients presented in this paper were going to undergo vast ablative procedures for tumors stage III-IV or recurrent disease, and were going to be left with extensive and profound defects following the surgical resection.

We believe that, under these circumstances, the pedicled pectoralis major myocutaneous flap still represents a good alternative to microvascular reconstruction. In fact the mean operative time of the surgical procedure is markedly shorter, the recovery time from anaesthesia is reduced, there is less exposure to the risk of an infection and there is an overall reduced surgical burden for the patient (19). All these factors may have a significant impact on the post-operative course of similar patients, who are already worn out by the consequences of the primary disease and whose cardiopulmonary, renal and nutritional status is less than optimal.

The operation is performed as a one-stage reconstruc-

tion and there is no need to change the patient's position. A paddle large enough to cover most defects can be harvested and can be used for defects involving two epithelial surfaces. The axial vascularization of the flap is excellent and the donor site morbidity is acceptable. The pectoralis major myocutaneous flap, with its muscular belly, provides adequate soft tissue bulk to safely cover the delicate anatomical structures of the neck, especially in irradiated patients (14). Another advantages of the pedicled pectoralis major myocutaneous flap may be represented by its reduced cost, an aspect worth consideration in times when financial resources become increasingly constrained in medical care and more emphasis is placed on carefully weighing the benefits of performing costly procedures, particularly for patients whose life expectancy is severely limited. In fact, the microvascular reconstruction requires operative room free to 24 hours from 24 hours, specialize staff, specific microsurgical instrument (3, 4, 23, 24).

One of the main disadvantages of the pectoral flap is perhaps represented by the fact that it tends to distort the intraoral reconstruction and leave unsightly external bulges. In the intraoral and oropharyngeal area follow-up is more difficult because the flap can mask recurrence. Higher rate of fistula formation, lack of arc rotation, and alteration of symmetry of the breast region are other disadvantages that have been described (20, 21).

The intraoral transfer of hair-bearing chest skin with the pectoral flap is occasionally possible, but the hair is usually away, within a few weeks by the action of saliva (5, 6, 11, 15). The defect to be reconstructed in these type of patients are frequently large and exposed to unfavourable factors like salivary secretion and bacterial contamination. It is therefore difficult to determinate whether any complications, such as infection, wound dehiscence, fistula formation, are related to the type of reconstruction technique used or to other factors, and whether they are related to the flap itself or to the recipient-site.

Conclusion

When the options are considered for immediate reconstruction after ablative surgery for cancer of the oral cavity or oropharynx in elderly and critically ill patients, with infiltrating intraoral and oropharyngeal lesions, or in patients with underlying systemic syndromes, the use of the pectoralis major flap still represents a good alternative to free tissue transfer, and sometimes a preferable choice with fewer risks for the patient. In fact, this type of patients with multiple preoperative morbidities requires this kind of management necessarily.

We reviewed our experience with 12 pectoralis major myocutaneous flaps, which we performed over a period of 17 months, in 12 critically ill patients who had infiltrating intraoral and oropharyngeal cancers.

References

1. Schusterman MA, Miller MJ, Reece G P, et al. A single center's experience with 308 free flaps for repair of head and neck cancer defects. *Plast Reconstr Surg* 1994; 93: 472.
2. Urken ML, Weinberg H, Buchbinder D, et al. Microvascular free flaps in head and neck reconstruction. *Arch Otolaryngol Head Neck Surg* 1994; 120: 633.
3. Kroll SS, Evans GRD, Goldberg D, et al. A comparison of resource costs for head and neck reconstruction with free and pectoralis major flaps. *Plast. Reconstr. Surg* 1997; 99: 1282.
4. Tsue TT, Desyatnikova SS., Deleyiannis FWB., et al. Comparison of cost and function in reconstruction of the posterior oral cavity and oropharynx: Free vs pedicled soft tissue transfer. *Arch. Otolaryngol. Head Neck Surg* 1997; 123: 731.
5. Rosenthal E, Carroll W, Dobbs , et al. Simplifying head and neck microvascular reconstruction. *Head Neck* 2004; 26: 930.
6. Ariyan, S. The pectoralis major myocutaneous flap: A versatile flap for reconstruction in the head and neck. *Plast. Reconstr Surg* 1979; 63: 73.
7. Blackwell KE. Unsurpassed reliability of free flaps for head and neck. *Arch Otolaryngol Head Neck Surg* 1999; 125: 295.
8. Chepeha DB, Annich G, Pynnonen MA, et al. Pectoralis major myocutaneous flap vs revascularized free tissue transfer: Complications, gastrostomy tube dependence, and hospitalization. *Arch Otolaryngol Head Neck Surg* 2004; 130: 181.
9. Ijsselstein CB, Hovius SE, ten Have B L, et al. Is the pectoralis myocutaneous flap in intraoral and oropharyngeal reconstruction outdated? *Am. J. Surg* 1996; 172: 259.
10. Metha S, Sarkar S, Kavarana N, et al. Complications of the pectoralis major myocutaneous flap in the oral cavity: A prospective evaluation of 220 cases. *Plast. Reconstr. Surg* 1996; 98: 31.
11. Zbar RIS, Funk, GF, McCulloch TM, et al. Pectoralis major myofascial flap: A valuable tool in contemporary head and neck reconstruction. *Head Neck* 1997; 19: 412.
12. Liu R, Gullane P, Brown D, et al. Pectoralis major myocutaneous pedicled flap in head and neck reconstruction: Retrospective review of indications and results in 244 consecutive cases at the Toronto General Hospital. *J. Otolaryngol* 2001; 30: 34.
13. Ariyan S. Further experience with the pectoralis major myocutaneous flaps for the immediate repair or defects from excisions of head and neck cancers. *Plast. Reconstr. Surg* 1979; 64: 605.
14. Azevedo JF. Modified pectoralis major myocutaneous flap with partial preservation of the muscle: A study of 55 cases. *Head Neck Surg* 1986; 8: 327.
15. Wilson JSP, Yiacoumettis AM., and O'Neil T. Some observations on 112 pectoralis major myocutaneous flaps. *Am. J. Surg* 1984; 147: 273.
16. Chu PY, Chang SY. Reconstruction of circumferential pharyngoesophageal defects with laryngotracheal flap and pectoralis major myocutaneous flap. *Hand Neck.* 2002; 24 (10): 933-9.
17. Ossoff RH, Wurster CF, Berkold RE, et al. Complications after pectoralis major myocutaneous flap reconstruction of head and neck defects. *Arch. Otolaryngol* 1983; 109: 812.
18. Koh KS, Eom, JS, Kirk I, Kim SY, Nam S. Pectoralis major musculocutaneous flap in oropharyngeal reconstruction: revisited. 2006 Oct;118(5):1145-9; discussion 1150
19. Schuller DE. Pectoralis myocutaneous flap in head and neck cancer reconstruction. *Arch. Otolaryngol* 1990; 109: 185.
20. Kroll SS, Goepfert H, Jones M, et al. Analysis of complications in 168 pectoralis major myocutaneous flaps used for head and neck reconstruction. *Ann. Plast. Surg* 1990; 25: 93.
21. Shah JP, Haribhakti V, Loree TR, et al. Complications of the pectoralis major myocutaneous flap in head and neck reconstruction. *Am. J. Surg* 1990; 160: 352.
22. Dedivitis RA, and Guimarães AV. Pectoralis major musculocutaneous flap in head and neck cancer reconstruction. *World J. Surg* 2002; 26: 67.
23. McCrory AL, and Magnuson S. Free tissue transfer versus pedicled flap in head and neck reconstruction. *Laryngoscope* 2002; 112: 2161.
24. Funk G F, Karnell LH, Whitehead S, et al. Free tissue transfer versus pedicled flap cost in head and neck cancer. *Otolaryngol* 2002; *Head Neck Surg.* 127: 205.
25. Spriano G, Pellini R, Rosselli R. Pectoralis major myocutaneous flap for Hypopharyngeal reconstruction. *Plast Reconstr Surg.* 2002; 110 (6): 1408-13; discussion 1414-6.