

## Endoscopic therapy for type B surgical biliary injury in a patient with short cystic duct

F. SELVAGGI, G. CAPPELLO, A. ASTOLFI, P. DI SEBASTIANO, N. DEL CIOTTO, N. DI BARTOLOMEO, P. INNOCENTI

**SUMMARY:** Endoscopic therapy for type B surgical biliary injury in patient with short cystic duct.

F. SELVAGGI, G. CAPPELLO, A. ASTOLFI, P. DI SEBASTIANO, N. DEL CIOTTO, N. DI BARTOLOMEO, P. INNOCENTI

*Anatomical variations of the cystic duct are well-defined. The presence of short or absent cystic duct is unusual and represents a co-factor of biliary injury especially during laparoscopic cholecystectomy. Thus, its knowledge is important to avoid ductal injury in hepato-biliary surgery.*

*We experienced the case of a 40-year-old woman with symptomatic cholelithiasis, who underwent to laparoscopic cholecystectomy. At surgery, an accidental bile duct lesion was carried, during Calot's triangle dissection, due the particular difficulties in dissecting an extremely short cystic duct found at the junction of the common hepatic duct and common bile duct. No vascular anomalies were present. The biliary leakage from the common bile duct was intraoperative identified and subsequently treated by the endoscopic method. Laparoscopic cholecystectomy with sequential biliary endoprosthesis insertion was completed without conversion to open surgery. The endoscopic stenting was the definitive treatment for the leakage. No evidence of biliary stent complication was observed during the follow-up.*

*This report documents a case of short cystic duct with particular emphasis to the biliary injury risk during the laparoscopic dissection of "unusual" Calot's triangle, and examines our mini-invasive therapeutic strategies in the management of bile leakage after laparoscopic cholecystectomy.*

**RIASSUNTO:** Terapia endoscopica per lesione biliare chirurgica di tipo B in paziente con dotto cistico corto.

F. SELVAGGI, G. CAPPELLO, A. ASTOLFI, P. DI SEBASTIANO, N. DEL CIOTTO, N. DI BARTOLOMEO, P. INNOCENTI

*Il dotto cistico può presentare varianti anatomiche ben definite. Il riscontro di un dotto cistico corto o assente è una rara condizione e costituisce un fattore di rischio di lesione biliare soprattutto durante procedure laparoscopiche. Per questo, il suo riconoscimento è importante al fine di evitare gravi danni in particolare in chirurgia epato-biliare.*

*Presentiamo il caso di una donna quarantenne con litiasi della colecisti sintomatica sottoposta a colecistectomia laparoscopica. Durante la dissezione del triangolo di Calot si determinava una lesione accidentale della via biliare anche per la particolare difficoltà di isolare un dotto cistico estremamente corto alla congiunzione del dotto epatico comune e del dotto biliare comune. Nessuna alterazione anatomica vascolare è stata osservata. La filtrazione di bile dal dotto biliare comune è identificata durante l'intervento. La colecistectomia viene conclusa per via laparoscopica e la lesione biliare è stata trattata con successo con procedure endoscopiche sequenziali. Il posizionamento di stenting ha consentito la chiusura della fistola biliare. Nessuna complicanza da posizionamento delle endoprotesi è stata osservata nel follow-up.*

*Questo lavoro documenta un caso di dotto cistico corto, con particolare enfasi al rischio di danno biliare in presenza di un triangolo di Calot anomalo, ed esamina le strategie terapeutiche mini-invasive da noi realizzate nel trattamento delle fistole biliari dopo colecistectomia laparoscopica.*

**KEY WORDS:** Cholecystectomy - Laparoscopy - Endoscopy - Biliary endoprosthesis. Colecistectomia - Laparoscopia - Endoscopia - Endoprotesi biliare.

### Introduction

Short or absent cystic duct is an unusual anatomical anomaly of biliary tree and its misidentification is

associated to increased view of bile duct injuries (BDI) (1, 2). In presence of a short cystic duct, the possibilities of total section of the common bile duct, wrongly identified as cystic duct, or thermal lesion of an "unusual" Calot's triangle are potentially increased (3). Results of an Italian survey on 56.591 cholecystectomies confirm that anatomical anomalies of biliary system are responsible of BDI during laparoscopic surgery in 12,9% of observed cases, and misidentification of the common bile duct for the cystic duct is reported most commonly

"G. d'Annunzio" University, Chieti, Italy  
Surgical Sciences Department  
Unit of General and Laparoscopic Surgery

© Copyright 2010, CIC Edizioni Internazionali, Roma

as the cause of BDI with an incidence of 36.8% (4).

Early recognition of BDI and adequate multidisciplinary approaches (endoscopic stenting, percutaneous transhepatic dilatation and surgical reconstruction) are key points for the optimal final outcome of patients (6,7). Retrospective studies have suggested that in the presence of bile duct leakage or stricture, endoscopic stent treatment should be regarded as the first choice treatment according to the favourable long term outcomes demonstrated (6).

The aim of this report is to outline our strategies and techniques for the management of bile duct leakage sustained by the unusual anatomy as a short cystic duct, early recognized during laparoscopy in our case and successfully controlled by sequential biliary endoprosthesis insertion.

The multidisciplinary approach in the management of BDI, the careful operative technique to prevent BDI, the experience in laparoscopic surgery, are emphasized together with a revision of the concerning scientific literature.

## Case report

A 40-year-old woman with a history of recurrent right upper quadrant postprandial pain was referred to our department. Physical examination reveals no abdominal signs and blood cell count, liver function and serum amylase levels were normal. Her past history included only a cystic mass of the uterus surgically treated. Abdominal ultrasonography (US) revealed cholelithiasis and gallbladder with radiographic signs of chronic inflammation.

A laparoscopic cholecystectomy was performed. At surgery, the gallbladder was dissected free from the liver bed by sharp and blunt dissection according to the infundibular-cystic technique. During the dissection, an unusual arrangement of biliary tract anatomy was diagnosed. No visceral adhesions were observed and gallbladder wall appeared not fibrotic. Intraoperatively, we were able to recognize the anomaly of a very short cystic duct at the junction of the common hepatic duct and the common bile duct (Fig. 1) confirmed by radiological imaging. During gallbladder dissection, a bile duct laceration was led at the common bile duct level due the difficulties in isolating main bile duct from the infundibulum wall. The injury caused by the thermal dissection of "unusual" Calot's triangle structures was recognized during laparoscopy. The laparoscopic approach was not converted to open surgery and the cystic artery and the anomalous duct, together with a portion of infundibulum, were clipped in the normal fashion. Cholangiography confirmed the intraoperative diagnosis of biliary leakage at the common bile duct level without revealing associated lesions. At the end of laparoscopy the bile leakage was evaluated by endoscopic retrograde cholangio-pancreatography (ERCP). Sphincterotomy of Oddi papilla was performed and 11 cm -10 French (Fr) size stent (COOK Medical, Cotton-Leung® -Amsterdam- Biliary Stent) was inserted by-passing the bile leakage site localized to the common bile duct.

In 2nd postoperative day, a moderate fluid collection containing bile was detected in drainage left on the gallbladder bed. Clinical symptoms were aspecific and the abdomen was normal.

Additional cholangiography was proposed and radiological imaging revealed the persistence of biliary leakage coming from the reported duct damage suggesting that 10 Fr endoprosthesis was not

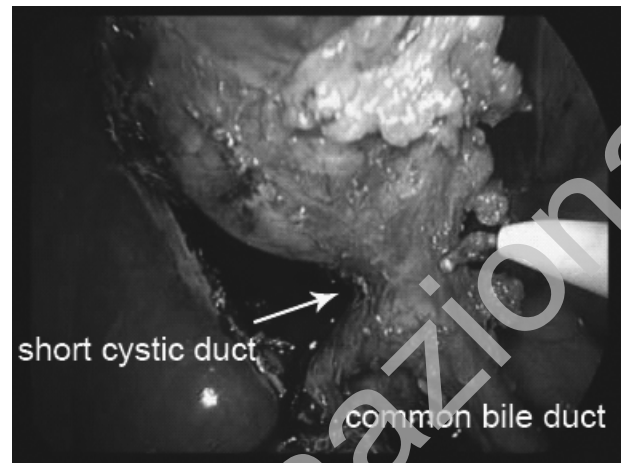

Fig. 1 - Laparoscopic cholecystectomy: an extremely short cystic duct connects the infundibulum to the common bile duct.

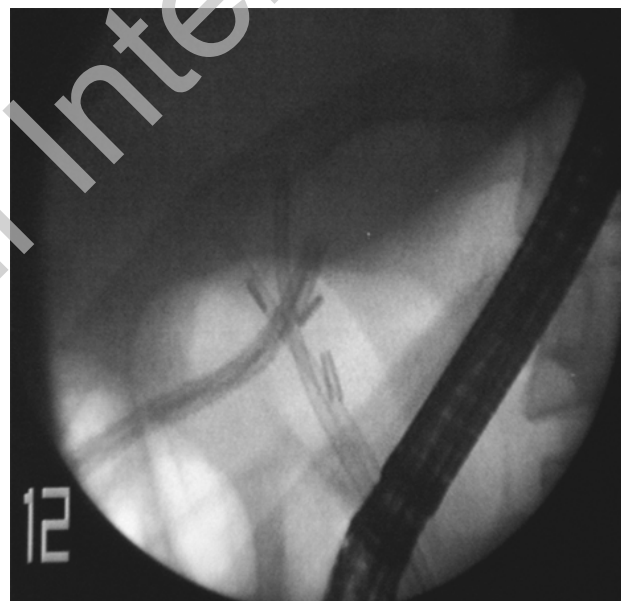


Fig. 2 - Biliary stenting: for a definitive bile leakage control, two selective 8,5 Fr biliary stents were placed for each liver hemisystem by-passing the confluence. Drainage of the gallbladder bed was left in situ.

effective in controlling bile secretion. Bile filtration coming through the external wall of the stent and the duct epithelium was the cause of fluid collection detected from the abdomen drainage.

For the differences in the bile duct and stent calibre, two 8,5 Fr stents (COOK Medical, Cotton-Leung® -Amsterdam- Biliary Stent) were placed and left in situ for each liver biliary hemisystem with the aim to ensure a selective biliary drainage (Fig. 2). Nasobiliary catheter was advocated to monitor the status of the leakage during hospitalization by cholangiography and to ensure a more effective biliary drainage. The sequential endoscopic procedures were finally successful. Any additional laparoscopy was required. Convalescence was uneventful with complete resolution of symptoms. The histological findings showed chronic mild cholecystitis with cholelithiasis.

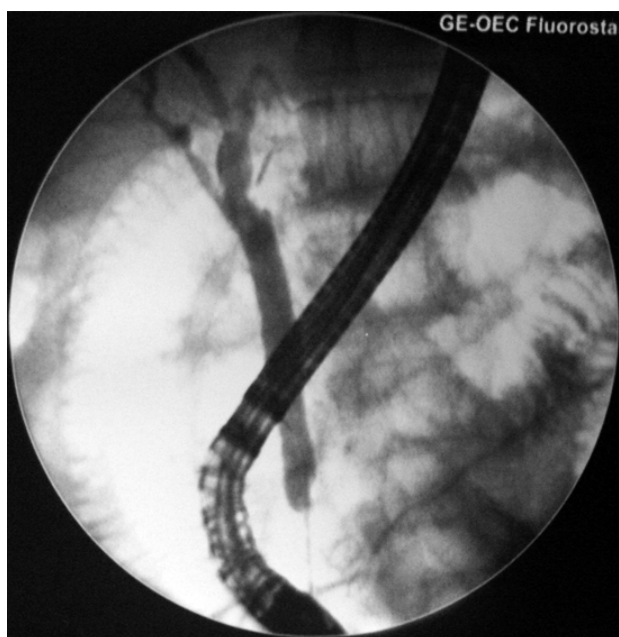

Fig. 3 - After 12 weeks, 8,5 Fr stents were endoscopically removed. No evidence of bile filtration or endoscopic stenting complication were reported.

After 12 weeks from the hospital discharge, the selective biliary stents were radiologically evaluated and then endoscopically removed (Fig. 3). At 12 months from endoscopic procedure, no evidence of complication was reported. The patient was remained in good health without any further problem.

## Discussion and conclusions

Despite consolidated experiences in laparoscopic cholecystectomy, the frequency of BDI is not decreased and represents a current surgical problem. BDI occurs in 0,5 % after laparoscopic cholecystectomy resulting in increased morbidity and poor long-term quality of life (4-7). Operative risk variables potentially related to biliary damage are represented by the learning curve phase in laparoscopic surgery, coexisting inflammatory process, presence of impacted stones and unusual biliary anatomy (4, 7).

A short or absent cystic duct is a uncommon contributing factor (5, 8). One of the earlier descriptions of a short or absent cystic duct dates 40 years ago (5). Its misidentification, together with other anatomic variants, happens much more frequently in laparoscopic surgery compared to conventional approach (7, 9). A short cystic duct, defined as a structure less than 5 mm in length, or an absent cystic duct may be draining into right hepatic duct or common hepatic duct. In 5% of cases, it connects the infundibulum with the common bile duct by only few millimetres in length (10).

Our experience refers a case of BDI during laparoscopic cholecystectomy, type B according to Amsterdam classification (8). Recently, the incidence of type B injury was demonstrated to be around 17% of cases (7).

In our case, the lesion was sustained by cauthery dissection of the gallbladder strongly connected to the common bile duct by an extremely short cystic duct. The experience of the surgeon who performed laparoscopic cholecystectomy was relevant in the immediate identification of the biliary anomaly finally confirmed by cholangiography. The expertise of the surgeon in BDI repair is a critical point because the decision to continue the laparoscopic surgery depends on the balance between surgeon ability and anatomical complexity of the biliary injury. In our case, the trained operator has contributed to minimize the severity of the biliary damage preventing an additional laparotomy with the related consequences.

To minimize the risk of BDI, an accurate assessment of the biliary tree has to be advocated intraoperatively by cholangiography together with particular surgical technique arrangements (4, 10, 11). Results on the advantages of routine *vs* selective use of intraoperative cholangiography in preventing BDI are diverging and the incorrect execution or individual interpretation of cholangiography often are responsible of wronged diagnosis (4). In our case, intraoperative cholangiography was particularly helpful in confirming the site of bile leakage and the absence of additional lesions.

The basic surgical principles have to respect the dissection of gallbladder that should be performed close to its wall, especially in the region of the infundibulum, showing any structure before ligation or section. A critical point is the good exposure of the cystic duct together with the hepatic pedicle; only after the correct identification and preparation of these anatomical structures the surgeon can proceed with dissection (4).

The dissection of soft structures by thermal coagulation, such as the common bile in our situation, may be a critical phase during laparoscopic exposure, also when all the anatomical structural changes have been well recognized at surgery.

In the management of a short cystic duct some authors have underlined the need of EndoGIA ligation to avoid a subsequent stricture (10). In our situation, no transfixed suture was applied and the short cystic duct was adequate closed by clips respecting common bile duct lumen.

We have advocated the use of endoscopic sphincterotomy and biliary stents to by-pass the bile leakage. Several reports have confirmed that insertion of endoprosthesis proved successful in 71% of major bile ducts cases after cholecystectomy in expert centres of biliary surgery (7). The 10 Fr endoscopic stent used failed in controlling bile leakage due the differences of the bile

duct as regards endoprosthesis calibre. The definitive strategy has consisted in the use of two selective 8,5 Fr biliary stents left *in situ* for each liver biliary hemi-system together with the use of naso-biliary drain in aspiration.

The follow up was programmed according to the therapeutic algorithms proposed by Gouma and colleagues (8). Traditionally, bile leakage is treated by surgery with an elective hepatojejunostomy. We have preferred to attempt sequential endoscopies and the rationale was to selectively remove fluid coming from each biliary hemi-system before resorting secondary reconstructive surgery.

The efficacy of multidisciplinary approach of radiologists, gastroenterologists and surgeons in BDI cases

has been clearly discussed and extensively confirmed by clinical results (7).

The impact of a multidisciplinary team in BDI patient on survival, underling the importance of a standard algorithms in repairing procedures, has been well analyzed (6). Leakage from the main bile duct can be successfully controlled by endoscopical stenting and retrospective studies have concluded that surgery and endoscopy were equally successful in BDI management (7, 9).

Since any cholecystectomy has to be considered a simple routine surgical procedure without BDI risk, the clinicians should every time suspect uncommon situations, establish the correct timing of interventional procedures for each case and respect therapeutic algorithms for the management of BDI patients.

## References

1. Ota A, Kano N, Kusanagi H, Yamada S, Garg A. Techniques for difficult cases of laparoscopic cholecystectomy. *J Hepatobiliary Pancreat Surg* 2003; 10: 172-175.
2. Davidoff AW, Pappas TN, Murray EA, Hilleren DJ, Johnson RD, Baker ME, Newman GE, Cotton PB, Meyers WC. Mechanisms of major biliary injury during laparoscopic cholecystectomy. *Ann Surg* 1992; 215 (3): 196-202.
3. Strasberg SM, Eagon CJ, Drebin JA. The "Hidden Cystic Duct" syndrome and the infundibular techniques of laparoscopic cholecystectomy- the danger of the false infundibulum. *J Am Coll Surg* 2000; 191: 661-667.
4. Nuzzo G, Giuliani F, Giovannini I, Ardito F, D'Acapito F, Velone M, Murazio M, Capelli G. Bile duct injury during laparoscopic cholecystectomy: results of an Italian national survey on 56591 cholecystectomies. *Arch Surg* 2005; 140 (10): 986-992.
5. Bogardus GM, Lundmark VO. The short or absent cystic duct. *Surgery* 1969; 65 (2): 274-275.
6. De Reuver PR. Endoscopic treatment of post-surgical bile duct injuries: long term outcome and predictors of success. *GUT* 2007; 56: 1599-1605.
7. De Reuver PR, Rauws EA, Bruno MJ, Lameris JS, Busch OR, Van Gulik TM, Gouma DJ. Survival in bile duct injury patients after laparoscopic cholecystectomy: a multidisciplinary approach of gastroenterologists, radiologists, and surgeons. *Surgery* 2007; 142: 1-9.
8. Bergman JJGHM, Van den Brink GR, Rauws EAJ, de Wit L, Obertop H, Huibregtse K, Tytgat GNJ, Gouma DJ. Treatment of bile duct lesions after laparoscopic cholecistectomy. *GUT* 1996; 38: 141-147.
9. Rauws EAJ, Gouma DJ. Endoscopic and surgical management of bile duct injury after laparoscopic cholecystectomy. *Best Practice & Reseach Clinical Gastroenterology* 2004;18 (5): 829-846.
10. Barkun AN, Rezieg M, Metha SN, Pavone E, Landry S, Barkun JS, Fried GM, Bret P, Cohen A. Postcholecystectomy biliary leaks in the laparoscopic era: risk factors, presentation, and management. *Gastrointestinal Endoscopy* 1997; 45: 277-282.
11. Strasberg SM, Hertl M, Soper NJ. An analysis of the problem of biliary injury during laparoscopic cholecystectomy. *J Am Coll Surg* 1995; 180(1): 101-25.