

Open mini-invasive cholecystectomy in high risk elderly. A review of 121 consecutive procedures

G. AMATO, G. SALAMONE, G. ROMANO, A. AGRUSA, V. SALADINO, G. GULOTTA

SUMMARY: Open mini-invasive cholecystectomy in high risk elderly. A review of 121 consecutive procedures.

G. AMATO, G. SALAMONE, G. ROMANO, A. AGRUSA, V. SALADINO, G. GULOTTA

Introduction. *The report describes the features of a low cost, open mini-invasive procedure for cholecystectomy in a sample of 121 consecutive high risk elderly (ASA score 3 to 5).*

Patients and methods. *The surgery is performed through a 3 – 4 cm right subcostal skin incision. An optimal exposition of the operating field was achieved thanks to an innovative three valve retractor.*

Results. *A mean hospital stay of 3,02 days, low complication rate and 2,4% mortality are the results of the described procedure.*

Conclusions. *In high risk elderly the results are extremely encouraging, particularly in comparison with both laparoscopic and traditional open cholecystectomy. The open minisurgical cholecystectomy could be considered a cost-effective alternative to laparoscopy, with excellent results in this subset of patients. The described mini-surgical procedure can also integrate the laparoscopic in case of conversion.*

RIASSUNTO: Colecistectomia mini-invasiva open in soggetti anziani ad alto rischio. Risultati in 121 pazienti consecutivi.

G. AMATO, G. SALAMONE, G. ROMANO, A. AGRUSA, V. SALADINO, G. GULOTTA

Introduzione. *Vengono discussi i risultati di una metodica mini-invasiva open per la colecistectomia in 121 pazienti ad alto rischio (ASA da 3 a 5).*

Pazienti e metodi. *L'intervento viene eseguito attraverso un'incisione sottocostale destra di 3-4 cm. Uno specifico divaricatore autostatico a tre valve consente una ottimale esposizione del campo operatorio.*

Risultati. *Grazie soprattutto ad una bassissima percentuale di complicanze intra- e postoperatorie, la degenza media è stata di 3,02 giorni, con mortalità del 2,4%.*

Conclusioni. *I risultati ottenuti in questi pazienti anziani ad alto rischio con la metodica minichirurgica sono estremamente incoraggianti, in particolare se confrontati con quelli della colecistectomia laparoscopica e della open tradizionale. Inoltre, nei pazienti ad alto rischio, la colecistectomia minichirurgica può essere considerata una valida alternativa "low cost" alla metodica laparoscopica. La tecnica minichirurgica, infine, può integrarsi alla metodica laparoscopica nel caso sia necessario convertire l'intervento.*

KEY WORDS: Minimally invasive surgical procedures - Cholecystectomy - Elderly.
Tecniche chirurgiche mini-invasive - Colecistectomia - Anziano.

Introduction

Laparoscopic cholecystectomy, nowadays, is considered the gold standard for the surgical treatment of cholelithiasis. However, due to relative or absolute contraindications, in high risk patients open cholecystectomy is preferred to laparoscopic approach. In fact, the conversion rate from laparoscopic to open traditional cholecystectomy, in case of inflammatory

changes (acute, adherential or suppurative), is exceptionally high, with huge additional risks and costs (1-4). In high risk elderly this occurrence increases furthermore the length of intervention and, consequently, amplifies the rate of complications, hospital stay and mortality (5, 6). Also for this kind of patients, the traditional open cholecystectomy often leads to a high incidence of morbidity and mortality.

The reports on minicholecystectomy in comparison with laparoscopic cholecystectomy are steadily increasing in the medical literature (7-12). This kind of open mini-invasive surgical procedure is however not well defined. Our opinion is that an undersized incision is not sufficient to classify a surgical procedure as mini-invasive. To reach a decrease in operative trau-

University of Palermo, Italy
Department of General Surgery, Urgency
and Organ Transplantation
(Head: Prof. G. Gulotta)

© Copyright 2010, CIC Edizioni Internazionali, Roma

ma, length of operating time, postoperative complications, hospital stay and costs, a particular tactical and technical approach in planning an open mini-invasive procedure is needed. Starting from these observations, since 1989 we began to develop an open mini-invasive, low cost procedure for cholecystectomy. Thanks to atraumatic methods, we routinely performed cholecystectomies through a 3 – 4 cm skin incision, with a technically well defined, standardized procedure. We called this practice “minisurgical cholecystectomy”. A few, new simple instruments, specially developed for this purpose, have been very helpful for a sure surgical procedure. Obtaining, in the case of high risk elderly, similar or often shorter time length of intervention and hospital stay in comparison with laparoscopic procedure. It has the added benefit of potentially saving costs. With this minisurgical open technique the number of complications, including mortality rate, was seen to be extremely low for this patient subset.

This study reports the postoperative outcome on 121 high risk patients, with ASA score from 3 to 5, who underwent a cholecystectomy with the open minisurgical procedure.

Patients and methods

From January 2002 to July 2009 a total of 121 high risk elderly patients (37 male, 84 female), with an age between 64 and 91 years (mean 71 years), underwent an open minisurgical cholecystectomy. All patients were previously submitted to a preoperative diagnostic and medical treatment to reach a satisfactory condition for the operative procedure. Most frequently the pathological findings were concerning, above all, the cardio-pulmonary and cerebral areas (Tab. 1).

The degree of risk was evaluated according to the classification of the American Association of Anaesthesiologist. Following these criteria 65 patients revealed an ASA score 3, 39 an ASA score 4 and the remaining 17 patients an ASA score 5.

In 24 patients we could preoperatively detect choledocus duct stones; among these, 9 had concomitant pancreatitis. These patients underwent preoperative ERCP with endoscopic stone removal. In 4 patients, in order to avoid stone descent from the dilated cystic duct, a nasobiliary drain was placed. In 3 of them the intraoperative manipulation of the gallbladder caused a stone passage into the choledochus, successfully managed with endoscopic stone removal at the 2nd – 3rd postoperative day. The operations were carried out under general anaesthesia in 106 patients; 15 patients, due to unsteady cardiopulmonary conditions, underwent high epidural anaesthesia (Figs. 1 A and B). The intervention was performed through a 3 - 4 cm right subcostal skin incision (Fig. 2 A). We used digitoclasic dissection (finger fracture) to spread the subcutaneous fat and the fibres of rectus abdominis muscle (Fig. 2 B). After opening the peritoneum, for a better visualization of the operating field, a three-valve retractor was used, developed especially for this purpose (Fig 3). Adhesions were usually removed using digitoclasic dissection or a mounted pledget. In case of hydrops or empyema a needle evacuation of the gallbladder content was performed. A special dissector was employed to prepare the cystic duct and the cystic artery (Figs. 4 and 5). After binding and cutting the bil-

TABLE 1 - MINISURGICAL CHOLECYSTECTOMY IN 121 HIGH RISK ELDERLY. COMORBIDITY.

• Ischemic and/or hypertensive cardiopathy	69 pts
• Mild or severe renal insufficiency	26
• Diabetes mellitus	25
• Cardiac arrhythmia	15
• Gastroduodenal ulcer	14
• COBP	13
• Valvular cardiopathy	6
• Liver cirrhosis	5
• Parkinson's disease	5
• Ictus cerebri	4
• Single kidney	2
• Dilatative myocardiopathy	2

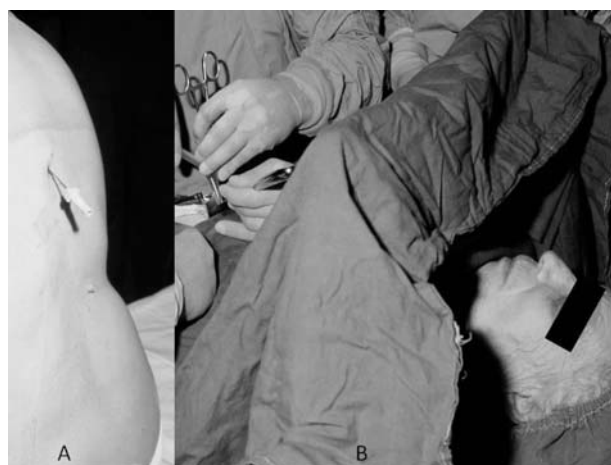


Fig. 1 - A) High epidural anaesthesia for cholecystectomy in high risk patient. B) Patient awake during the procedure.

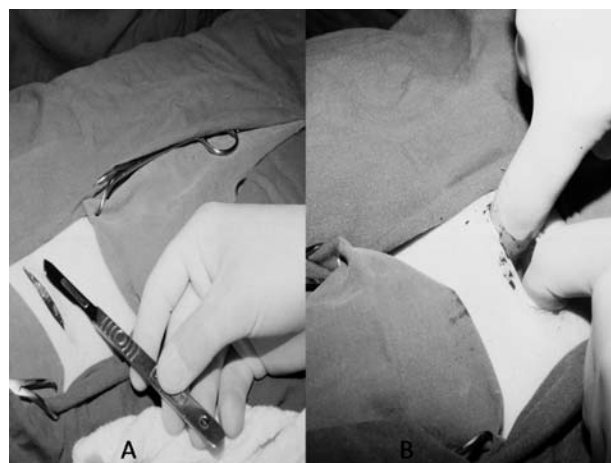


Fig. 2 - A) Right subcostal incision for minisurgical cholecystectomy. B) Digitoclasic dissection of the subcutaneous fat.

iovascular pedicle (Fig. 6), the gallbladder was removed digitoclasically (Figs. 7a, b, c, d). The residual bleeding coming from the gallbladder bed was simply managed placing a gauze soaked with warm water (hydrothermocoagulation). We drained the operating




Fig. 3 - Three-valve retractor for minisurgical cholecystectomy.

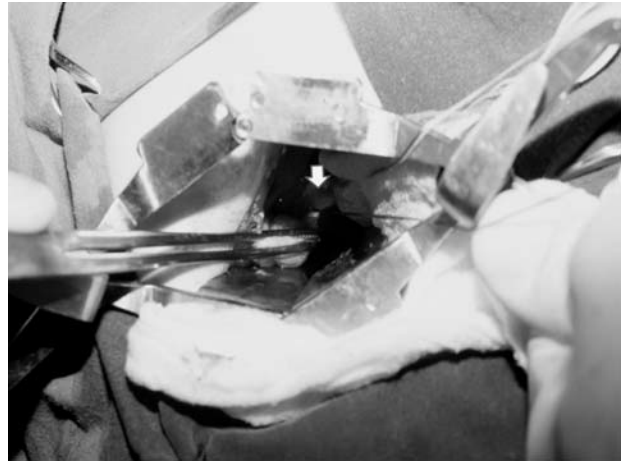


Fig. 6 - Ligation of the cystic duct in proximity of the confluence into the choledochus (arrow).

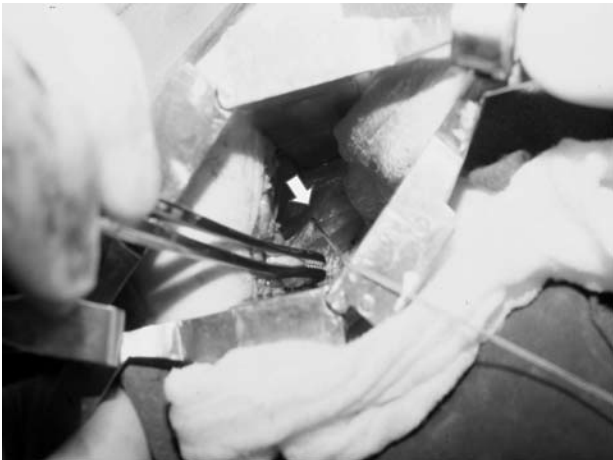
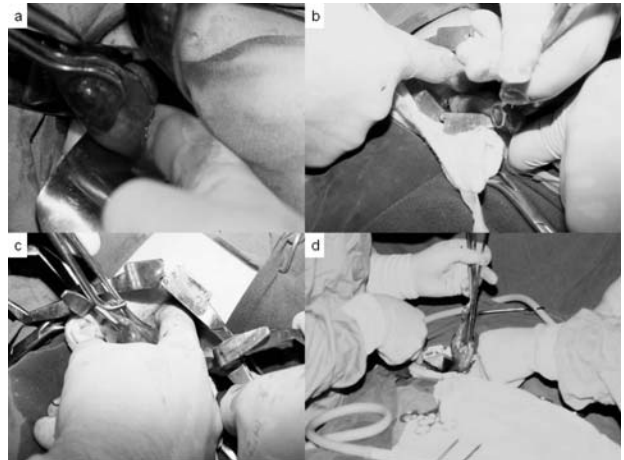


Fig. 4 - Ligation of the cystic artery during the open minisurgical procedure (arrow).



Figs. 7 a, b, c, d - Sequence of the digitoclasic dissection of gallbladder.

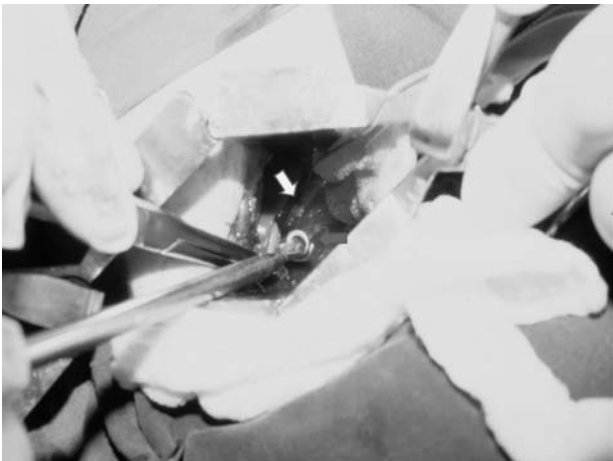


Fig. 5 - Preparation and dissection cystic duct with the cystic dissector. A ligature secures the stump of cystic artery at the bottom (arrow).

field only in 5 cases. Due to intra-operatively evidenced adhesions, in 19 patients (6,3%) an enlargement of the wound was necessary. However the incision length was never longer than 6-7 cm. The wound was closed without external stitches using a continuous subcuticular skin suture having self tightening knots (13). In all patients an antibiotic prophylaxis as well as an intensive postoperative fast track approach was carried out.

Results

The mean operating time was 40 minutes (range 25 - 75 minutes). Among our patient sample we reported 2 cases of double cystic duct. During the procedures could be evidenced 66 acute cholecystitis, 31 empyemas, 6 covered gallbladder perforations, 4 hydrops, 3 gallbladder carcinoma (Tab. 2).

TABLE 2 - MINISURGICAL CHOLECYSTECTOMY IN HIGH RISK ELDERLY. INTRAOPERATIVE FINDINGS.

• Acute cholecystitis:	66 pts
• Empyema:	31
• Bile duct stones:	24
• Pancreatitis:	9
• Covered perforation of the gallbladder:	6
• Hydrops:	4
• Carcinoma:	3

The mean postoperative hospital stay was 3,02 days (range 1 - 25 days); 17 patients were discharged on the 1st, and 46 on the 2nd postoperative day. Concerning the postoperative complications, on the 121 reported patients we registered 4 biliary leakages (3,5%): 3 were early recognized and managed with endoscopic papillotomy and positioning of a biliary endoprosthesis; the fourth patient underwent a hepaticojejunostomy. We also saw 9 postoperative seromas and, in a patient with covered perforation of a gallbladder empyema, wound sepsis. Three patients died (2,4%): one with a single kidney and gangrenous cholecystitis due to septic shock after an “explosion” of the gallbladder at the beginning of the visceral manipulation; 2 patients, with gallbladder empyema and liver cirrhosis in unsteady compensation, died as a result of acute liver failure. All these 3 patients had an ASA score 5.

Discussion

Laparoscopic cholecystectomy is nowadays considered as the gold standard in the surgical treatment of gallbladder lithiasis. However, in our opinion, this concept seems to be not available for all patients. In fact, while the laparoscopic cholecystectomy represents a decisive improvement for uncomplicated patients, this resource of the modern technology could actually be inappropriate or, due to technical difficulties and visceral conditions, quite contraindicated in the case of high risk elderly patients with high ASA score (3). This seems to be a serious contradiction, because the modern technology applied to surgery usually aims to resolve the problems of patients with a high degree of risk. In this case, the laparoscopic procedure is effective in a large number of non-complicated patients but could be inappropriately proposed if employed in high-risk elderly. In this patient category, aiming to avoid long and complex laparoscopic procedures with high risks of conversion, the literature reports that an old-fashioned medical therapy would often be preferred (14).

The use of the described three-valve retractor and cystic duct dissector, allows a selective exposure of the gallbladder pedicle, reduces operative trauma and bleed-

ing risks, permits a careful management of Calot's triangle. The effectiveness of this surgical device facilitates the surgical proceedings in deep and narrow spaces during the intervention, and was essential to properly detect a double cystic duct in 2 patients. To reach a truly “mini-invasive” procedure we also employed simple but effective means: digitoclastic dissection (finger fracture) of subcutaneous fat and fibres of the rectus muscle, use of traumatic instruments only when strictly necessary, digitoclastic removal of the gallbladder and hydrothermocoagulation to stop the residual bleeding, subcuticular continuous skin closure with self tightening knots. All these steps secure an atraumatic handling of the tissues in order to achieve a favourable anatomical exposure of the structures, to shorten the operating time and, in addition, to avoid bleeding, oedema and tissue damage. This method is easy and extremely blood sparing, avoids postoperative haematomas and wound infection also reducing the placement of abdominal drains.

In any case, thanks to the low or quite absent postoperative pain, we could carry out an intensive postoperative fast track patient management through early mobilization beginning within 8 hours after the surgical procedure. This way a good physiological cardiopulmonary condition could be reached and maintained.

None of the reported cases demonstrated the common complications associated with this kind of patient group: bronchopneumonia, thrombosis or heart failure. We are convinced that the employment of a procedural fast track approach, together with the described mini-invasive technique, is the reason for the reported low morbidity. We also consider the reported mortality rate, lower than 3%, as a very favourable result in high risk patient with ASA score 3 to 5.

On the topic of expenses, the material costs for the minisurgical technique are estimated to add only 15-20 € per case, despite 700 – 500 € needed for the laparoscopic cholecystectomy, as reported in the literature (15, 16). This unfavourable economic assessment in performing laparoscopic cholecystectomy is increasingly remarked about in recent scientific reports (11, 12, 17). Moreover, some authors portray a scenario of “a health and financial disaster” if an occurrence of laparoscopic related complications, as like bile duct injury, occurs (18, 19). Is a common opinion that this kind of complications are frequent in high risk elderly.

Conclusions

For the aforementioned reasons, concerning the surgical management of gallbladder lithiasis, besides

traditional laparotomic and the laparoscopic procedures, a third way must be considered. In high risk patients the open minisurgical cholecystectomy should be portrayed as an effective choice in alternative to laparoscopy, with excellent results as depicted in this report. Moreover, the described open mini-surgical ap-

proach can also integrate the laparoscopic procedure if a conversion to the open procedure is needed. Our point of view is, that this open minisurgical treatment represents a valuable and cost effective alternative in case of elderly with elevated risk having a high ASA score.

References

1. Kauvar DS, Brown BD, Braswell AW, Harnisch M. Laparoscopic Cholecystectomy in the Elderly: Increased Operative Complications and Conversions to Laparotomy. *J Laparoendosc Adv Surg Tech.* Aug 2005, Vol. 15, No. 4: 379-382
2. Hadad SM, Vaidya JS, Baker L, Koh HC, Heron TP, Hussain K, Thompson AM. Delay from symptom onset increases the conversion rate in laparoscopic cholecystectomy for acute cholecystitis. *World J Surg.* 2007 Jun;31(6):1298-01; discussion 1302-3
3. Bueno Lledó J, Vaqué Urbaneja J, Herrero Bernabeu C, Castillo García E, Carbonell Tatay F, Baquero Valdelomar R, Mir Pallardó J. Acute cholecystitis and laparoscopic cholecystectomy in the elderly. *Cir Esp.* 2007 Apr;81(4):213-7
4. Leshchenko IG, Aleksandrov IK, Kaplan BI. A decision for the strategy of treatment of patients with chronic calculous cholecystitis in the elderly and senile age. *Vestn Khir Im I I Grek.* 2005;164(4):25-7
5. Tambyraja AL, Kumar S, Nixon SJ. Outcome of Laparoscopic Cholecystectomy in Patients 80 Years and Older. *World J Surg.* 2004 Aug; 28(8):745-8
6. Hazzan D, Geron N, Golijanin D, Reissman P, Shiloni E. Laparoscopic cholecystectomy in octogenarians. *Surg Endosc* Vol. 17, N° 5 May 2003: 773 – 776
7. Makela JT, Kiviniemi H, Laitinen S. Acute cholecystitis in the elderly. *Hepatogastroenterology.* 2005 Jul-Aug;52(64):999-1004
8. Keus F, de Jong JA, Gooszen HG, van Laarhoven CJ. Laparoscopic versus small-incision cholecystectomy for patients with symptomatic cholelithiasis. *Cochrane Database Syst Rev.* 2006 Oct 18;(4):CD006229
9. Tangjaroen S, Watanapa P. Mini-cholecystectomy Under Local Anaesthesia. *Asian J Surg.* 2007 Oct;30(4):235-8
10. Shulutko AM, Kazaryan AM, Agadzhanov VG. Mini-laparotomy cholecystectomy: Technique, outcomes. *Int J Surg.* 2007 Jul 26 + Amir M. et al, Mini-open cholecystectomy in the management of cholelithiasis. *J Coll Physicians Surg Pak.* 2007 May;17(5):269-71
11. Purkayastha S, Tilney HS, Georgiou P, Athanasiou T, Tekkis PP, Darzi AW. Laparoscopic cholecystectomy versus mini-laparotomy cholecystectomy: a meta-analysis of randomised control trials. *Surg Endosc.* 2007 Aug;21(8):1294-300.
12. Vagenas K, Spyropoulos P, Karanikolas M, Sakelaropoulos G, Maroulis I, Karavias D. Mini-laparotomy cholecystectomy versus laparoscopic cholecystectomy: which way to go? *Surg Laparosc Endosc Percutan Tech.* 2006 Oct;16(5):321-4
13. Amato G., Lo Monte A.I., Romano G., Sciacchitano T., Damiano G., Amato N., Romano M. Suture intradermiche totali. *Il giornale di chirurgia* 2010;1 (pub. ahead of print)
14. Mc Mahon AJ, Russell IT, Baxter JN, Ross S, Anderson JR, Moran CG, Sunderland G, Galloway D, Ramsay G, O'Dwyer PJ. Laparoscopic versus minilaparotomy cholecystectomy: a randomised trial. *Lancet* 1994;343: 135-38
15. Champault A, Vons C, Dagher I, Amerlinck S, Franco D. Low-cost laparoscopic cholecystectomy. *Br J Surg.* 2002 Dec;89(12):1602-7.
16. Allen JW, Polk HC Jr. A study of added costs of laparoscopic cholecystectomy based on surgery preference cards. *Am Surg.* 2002 May;68(5):474-6
17. Brazier JE, Johnson AG. Economics of surgery. *Lancet* 2001;358:1077-81
18. Savader SJ, Lillemoe KD, Prescott CA, Winick AB, Venbrux AC, Lund GB, Mitchell SE, Cameron JL, Osterman FA Jr. Laparoscopic cholecystectomy-related duct injuries: A health and financial disaster. *Ann. Surg.* 1997;225:268-73
19. Gouma DJ, Go PM. Bile duct injuries during laparoscopic and conventional cholecystectomy. *J Am Coll Surg.* 1994 Mar;178(3):229-33