

Prostate sarcomatoid carcinoma as accidental finding in transurethral resection of prostate specimen. A case report and systematic review of current literature

K. STAMATIOU, N. GALARIOTIS, M. OLYMPITIS, P. PAPADOPOULOS,
H. MOSCHOURIS¹, A. LAMBRACOPOULOS

SUMMARY: Prostate sarcomatoid carcinoma as accidental finding in transurethral resection of prostate specimen. A case report and systematic review of current literature.

K. STAMATIOU, N. GALARIOTIS, M. OLYMPITIS, P. PAPADOPOULOS,
H. MOSCHOURIS, A. LAMBRACOPOULOS

Background. Sarcomatoid carcinoma of the prostate is an extremely rare and highly aggressive neoplasm that accounts for less than 0.1% of primary prostate malignancies. Long-term survival rates for adult patients with prostate sarcomatoid carcinoma are poor. Surgical treatment seems to be the most effective therapeutic approach. In contrast radiation therapy alone has shown limited efficacy.

Aim. The purpose of the study is to present a case of sarcomatoid carcinoma of the prostate treated with a combination of radiotherapy and TURP.

Case report. A 76-year-old man treated with TURP due to acute urinary retention was finally diagnosed with sarcomatoid carcinoma upon pathology examination of the surgical specimen. Patient was initially treated with external beam radiotherapy. Six months later, he presented with urinary retention suggesting extension of the tumor into the bladder neck. Pathology report diagnosed prostate sarcomatoid carcinoma containing also large areas of necrosis. Patient underwent an extensive TURP and he received a second round radiotherapy. One year after the initial diagnosis of sarcomatoid carcinoma, patient is free of symptoms and follow up investigation shows no evidence of metastatic disease.

Conclusions. Radiation therapy in combination with extensive TURP may delay disease progression.

RIASSUNTO: Carcinoma sarcomatoide della prostata come reperto occasionale nel pezzo operatorio di resezione transuretrale della prostata. Caso clinico e revisione della letteratura.

K. STAMATIOU, N. GALARIOTIS, M. OLYMPITIS, P. PAPADOPOULOS,
H. MOSCHOURIS, A. LAMBRACOPOULOS

Premessa. Il carcinoma sarcomatoide della prostata è un tumore estremamente raro e aggressivo, con un'incidenza pari allo 0,1% tra tutte le neoplasie primarie della prostata. La percentuale di sopravvivenza a lungo termine per i pazienti adulti con carcinoma sarcomatoide della prostata è limitata. Il trattamento chirurgico sembra essere l'approccio terapeutico più efficace, laddove la sola radioterapia ha dimostrato efficacia limitata.

Scopo. Scopo di questo articolo è di presentare un caso di carcinoma sarcomatoide della prostata trattato con resezione transuretrale in combinazione con radioterapia.

Caso clinico. A un paziente maschio di 76 anni, sottoposto a resezione transuretrale della prostata per ritenzione urinaria acuta, è stato diagnosticato un carcinoma sarcomatoide all'esame istologico del campione chirurgico. Il paziente è stato inizialmente trattato con radioterapia esterna. Sei mesi dopo, il paziente ha presentato ritenzione urinaria indicativa di estensione del tumore al collo vescicale. L'istologia ha confermato il carcinoma sarcomatoide della prostata in necrosi estesa. Il paziente è stato sottoposto ad ampia resezione transuretrale estensiva e successivamente ad un secondo ciclo di radioterapia. A un anno dalla diagnosi iniziale di carcinoma sarcomatoide della prostata, il paziente risultava libero da sintomi e senza evidenza di metastasi ai controlli strumentali.

Conclusione. La radioterapia in combinazione con ampia resezione transuretrale può ritardare la progressione della malattia.

KEY WORDS: Prostate cancer - Sarcomatoid carcinoma - Surgery.
Carcinoma della prostata - Carcinoma sarcomatoide - Chirurgia.

Background

Carcinoma of the prostate is the most common form of cancer in men and the second leading cause of cancer death in the United States. Acinar adenocarcinoma represents the large majority (as much as 95%) of the prostatic cancers. Uncommon variants of adenocarcinoma are the ductal (endometrioid) adenocarcinoma, the mucinous (colloid) carcinoma and the signet ring cell carcinoma (ade-

nocarcinoma with signet ring differentiation) (1). Pseudo-hyperplastic carcinoma, adenocarcinoma with atrophic features, foamy gland carcinoma, adenocarcinoma with carcinoid-like morphology and adenocarcinoma with Paneth-like cells are often including as variants of adenocarcinoma but whether and if they really are specific variants of adenocarcinoma is somehow controversial (2).

Rare non acinar carcinomas of prostate include squamous cell carcinoma (although there are some cases with a mixture of glandular and squamous differentiation classified as adenosquamous carcinomas), small-cell (neuroendocrine) carcinoma, urothelial (transitional cell) carcinoma, basaloid and adenoid cystic-like (basal cell) carcinoma, and lymphoepithelioma-like carcinoma as well (1).

Sarcomatoid carcinoma (SC) is a very rare neoplasm of the prostate with less than 100 reported cases in the literature (3). Most have been reported in single case reports and small series (4,5) while only one study examining 42 consecutive cases from a single institute exists in the literature (6). The admixture of high-grade epithelial and sarcomatoid components that characterizes this tumor has led to debate on whether this entity represents a “collision” of epithelial and mesenchymal tumors (carcinosarcoma) or an evolution of an underlying adenocarcinoma into a lesion with associated sarcomatoid features and occasional heterologous elements (SC) (7,8). Interestingly most of the reported cases had a prior history of acinar adenocarcinoma of the prostate and only a few numbers of patients were presented with a de novo SC (4).

Here we present a patient with prostate SC and discuss the clinical, diagnostic and therapeutic aspects of this uncommon tumor.

Case report

A 76-year-old man presented to our department with acute urinary retention. He reported no hematuria or perineal pain and denied any constitutional symptoms. A history of frequent micturition, dysuria, poor urinary stream, and nocturia of approximately 12-month duration were also present. There was no family history of genitourinary cancer. He had ceased smoking 10 years before and drank alcohol socially. He reported no exposure to hazardous chemicals. Rectal examination revealed a moderately enlarged normal prostate gland. There was no palpable lymphadenopathy, and the rest of his physical examination was unremarkable. His last PSA, obtained 3 months earlier by his primary care physician as part of routine annual check up was 2,3 ngr/ml. The overall volume of prostate gland in abdominal ultrasound was 42cm³. A 16Ch Foley catheter was placed and α -blockers were prescribed in order to have a trial without catheter (TWOC) three days later. Due to TWOC failure he underwent transurethral resection of the prostate (TURP).

Results

According to the pathology report 40% of the specimen

(8cc) contained a biphasic tumor consisted of poorly differentiated adenocarcinoma admixed with spindle shaped pleomorphic neoplasm (Fig. 1). Immunohistochemistry confirmed the diagnosis of carcinosarcoma of the prostate. Specifically, carcinomatous element expressed cytokeratins and PSAP but exhibited no staining for PSA and P63. Neoplastic spindle cells expressed vimentin (Fig. 2), but exhibited no staining for PSA, PSAP, cytokeratins, actin, desmin and P63.

Due to the unexpected findings of the pathology report, patient underwent further evaluation. TRUS of the prostate revealed an inhomogeneous transitional zone, but failed to identify any focal lesion (Fig.3). MRI showed a round lesion of pathologic signal intensity at the right side of the transitional zone (Figs. 5 and 6). Both pelvic CT (Fig. 4) and MRI were not considered suspicious for lymph node involvement and extracapsular extension of the tumor. Computed tomographic scans of the abdomen, chest and brain

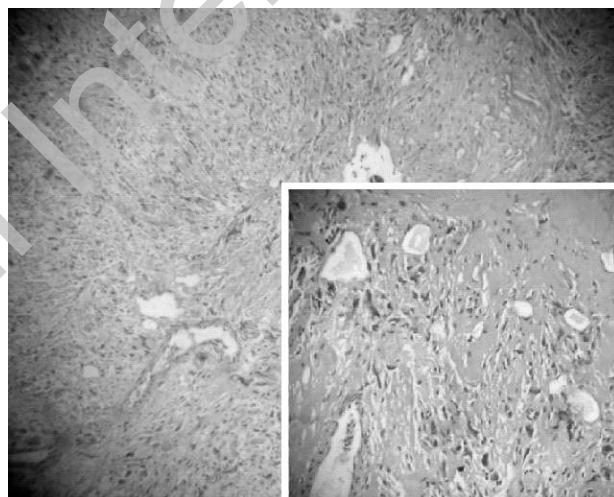


Fig. 1 - Spindle shaped pleomorphic neoplasm and poorly differentiated adenocarcinoma of the prostate. H&E, x40 (scale-up 100x).

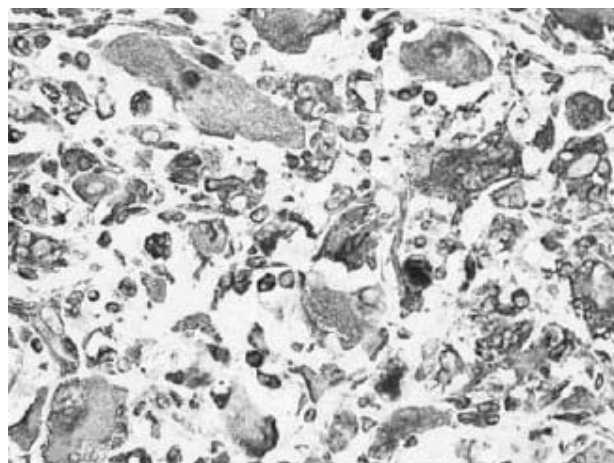


Fig. 2 - Spindle cells expressing vimentin (VIM x40).

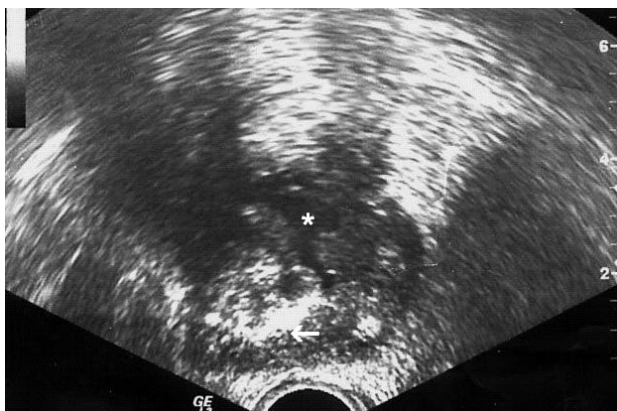


Fig. 3 - TRUS, axial section. The transitional zone is inhomogeneous but no mass lesion can be identified, probably due to the acoustic shadowing from the calcifications of the peripheral zone (arrow). A TUR cavity is present (asterisk).

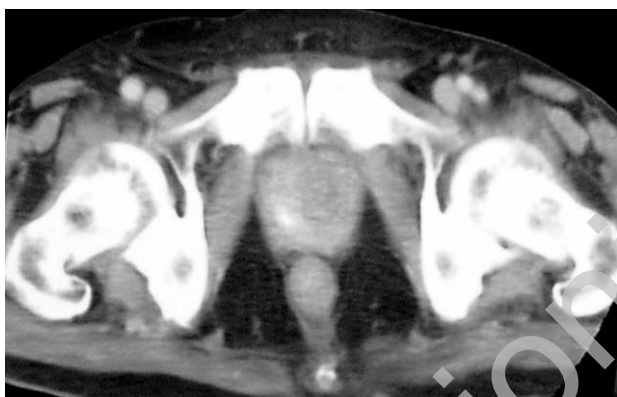

Fig. 4 - Contrast-enhanced CT of the lesser pelvis shows no extraprostatic spread of the disease. Prostatic calcifications and the TUR cavity can be identified.

as well as bone scan were negative for metastatic disease. Although radical cysto-prostatectomy was advised, patient denied any surgical intervention and he recommended palliative external beam radiotherapy. Six months later, he presented with urinary retention suggesting extension of the tumor into the bladder neck. Pathology report diagnosed prostate sarcomatoid carcinoma containing also large areas of necrosis. Patient underwent an extensive TURP and he received a second round radiotherapy. One year after the initial diagnosis of sarcomatoid carcinoma, patient is free of symptoms and follow up investigation shows no evidence of metastatic disease.

Discussion

Sarcomatoid carcinoma, also termed carcinosarcoma, metaplastic carcinoma and spindle-cell carcinoma, is a rare biphasic malignancy in the prostate (9). The two elements of SC are a malignant epithelial (carci-

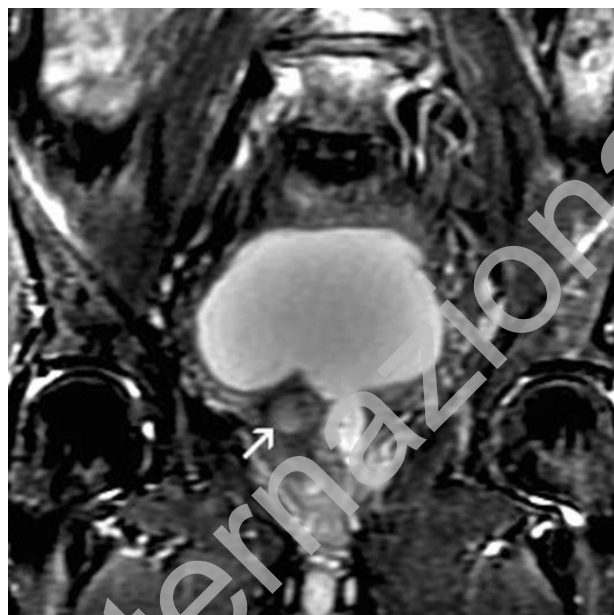

Fig. 5 - Coronal T2-weighted MR image with fat saturation demonstrates a round lesion of relatively high signal (arrow) at the right side of the transitional zone of the prostate. A TUR cavity is also evident.

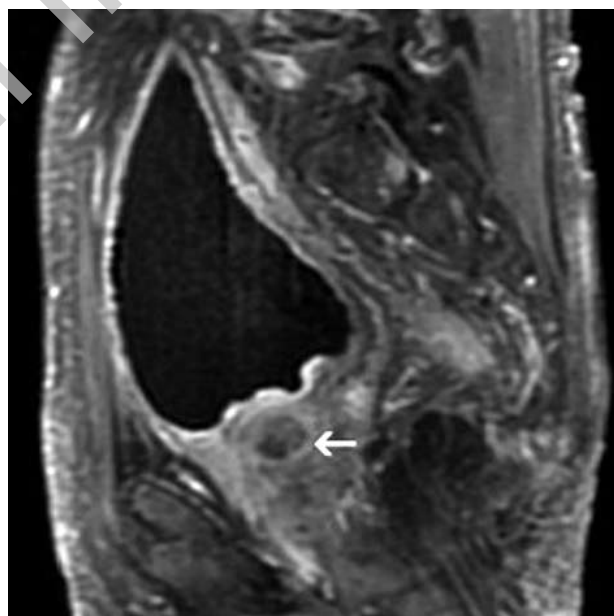


Fig. 6 - Sagittal contrast-enhanced T1-weighted MR image with fat saturation shows that the prostatic lesion is composed of an enhancing rim (arrow) and a non-enhancing, hypointense central part.

nomatous) component and a malignant mesenchymal-like or mesenchymal (sarcomatous) component (2).

Some authors use the term carcinosarcoma (CS) if there are heterologous elements and sarcomatoid carcinoma (SC) if homologous elements are present. In the first case, the sarcoma displays differentiation along the

lines of specific mesenchymal cells such as bone and cartilage. The most common elements are osteosarcoma and chondrosarcoma while myosarcoma, liposarcoma and angiosarcoma are less frequent (10). In approximately 30% of SCs, different types of sarcoma can be found together. In the second case the mesenchymal like areas have the appearance of an undifferentiated sarcoma.

Actually, the origin of these tumors has been controversial, and it is the consideration of some investigators that carcinosarcoma results from 2 distinct components, one epithelial and the other mesenchymal (8). However, there is no biologic data to support this distinction and most importantly, the clinical behavior of these two entities (CS and SC) is exactly the same (11, 12). Moreover, in some reports on the lymph node metastases of carcinosarcomas, the epithelial component predominates or is the only component. For the above reasons, other experts have used the terms CS and SC synonymously recognizing that even tumors with heterologous elements may express epithelial markers immunohistochemically (4). Currently the epithelial and sarcomatoid components are thought to be derived from a single cell of origin and thus both lesions (with and without heterologous elements) can be combined into one entity (6). Delahunt et al suggests that progression from adenocarcinoma is associated with p53 over-expression (7). Nevertheless, the most recent World Health Organization classification of urinary tract tumors does not distinguish between SC and CS and use the term "sarcomatoid carcinoma" to denote all of these lesions (13).

Macroscopically, prostatic SCs are -usually- large (5.5–18 cm), grey-white to pink coloured masses with haemorrhage and necrosis. They often show local extension into surrounding structures such as seminal vesicles and rectal wall (14).

Microscopically, the carcinomatous and sarcomatous components are mixed, with blending of the two in some areas. The most common appearance of sarcomatoid component is that of large areas of undifferentiated spindled and pleomorphic cells demonstrating malignant features including enlarged hyperchromatic nuclei and frequent mitoses, arranged in sheets or fascicles. Areas of necrosis are occasionally present (6,9). The carcinomatous element is almost always of acinar type (6). Rarely, ductal adenocarcinoma (15), squamous or adenosquamous carcinoma (16), and mixed urothelial - squamous components (17) are present. Hansel and Epstein reported a Gleason score 6 in 50% of their series, and a Gleason score 8 in the remaining 50% (6). According to Mazzucchelli et al however, the carcinomatous component is typically of high grade, with a mean Gleason score of 9, and range between 7 and 10 (14).

SCs are uniformly positive for vimentin immunostains and usually positive for cytokeratin and epithelial membrane antigen (18). More precisely, sar-

comatous components are always vimentin positive while epithelial markers (cytokeratins, PSA, PSAP) can be detected in some cases (2, 19). Skeletal muscle and vascular differentiation - if present - are substantiated by positivity for myoglobin and CD31 or CD34, respectively (20). The carcinomatous component is almost always cytokeratin, PSA and PSAP positive. The absence of immunoreaction of PAP and PSA in SC may either be due to the dedifferentiation of the tumor cells with loss of synthesis of these proteins, or to the origin of the tumor from embryonic vestige within the prostate, as suggested by others (21). According to Ray et al, expression of cytokeratin by the spindle cell component of sarcomatoid carcinoma suggests a common origin rather than a collision tumour composed of sarcoma and carcinoma (22). Since epithelial and sarcomatoid components are derived from a single cell of origin some authors suggest that the sarcomatoid component could be considered to be Gleason grade 5, with the glandular element, assigned a grade according to the usual rules (2). Other experts however suggest that a Gleason score can be assigned only to the glandular component (14).

Intriguingly, the natural history of this type of neoplasm is also a matter of debate. In fact, in an important number of patients, SC was developed after treatment for apparently pure prostatic adenocarcinoma (4, 5, 23), and remains unclear whether and if treatment with radiation or hormonal therapy may influence the development of subsequent SC (24). In the study of Hansel and Epstein the majority (66%) had a prior history of acinar adenocarcinoma of the prostate, however no correlation between the presence of treatment and either the time to progression to SC has been found (6). Actually, the time interval between the original diagnosis of acinar adenocarcinoma and diagnosis of SC is too wide (ranges from 6 months to 16 years) to extract any association (6,7,14). In addition, no correlation between the time to progression to sarcomatoid carcinoma and patient survival has been found (6).

It should be mentioned also that some cases present at time of diagnosis with both adenocarcinoma and sarcoma (synchronous carcinosarcoma) while few cases present at time of diagnosis with de novo SC (24). In our case no prior diagnosis of conventional prostatic adenocarcinoma was occurred, however, given the respectively smaller proportion of epithelial component and the rapid progression rate of high-grade prostatic adenocarcinomas, a progression of the acinar adenocarcinoma to a higher-grade sarcomatoid tumor at the very time of diagnosis is not to be excluded.

While adenocarcinomas are more frequent in elderly men, and pure sarcomas of the prostate in adult patients (25), sarcomatoid carcinomas may occur in both adult and elderly patients. In the study of Ren et al the

mean age of the study population was 45.8 years (range 21–76 years) (26) while in that of Hansel and Epstein the mean age of the study population was 70 years (range 50–89).

Most patients present with both filling symptoms (frequency, urgency, dysuria, nicturia) and voiding symptoms (poor stream, hesitancy, terminal dribbling and incomplete voiding). The tumors produce bladder outlet obstruction and often require repeated TURPs to control local symptoms (2). Less frequent manifestations are hematuria, perineal and/or rectal pain and burning on ejaculation. Constipation and constitutional symptoms such as weight loss may also present. Physical examination reveals either nonspecific enlargement of the prostate (as in our case) or an enlarged, nodular and hard prostate (16). In the current study, the serum PSA levels were lower than expected for the tumor volume a finding which is in accordance with that of other reports (2). In a subset of cases serum PSA levels are significantly elevated (4, 24, 27, 28).

In our case symptoms of urinary obstruction were the only manifestations of the disease however, they could also be attributed to the concomitant BPH. Since serum PSA was within normal limits and DRE was not suspicious for malignancy, in our case, diagnosis was established upon pathologic examination of transurethral resection of prostate specimen. In generally diagnosis is accomplished by ultrasound guided transrectal needle biopsy or TURP in patients with urinary obstruction and/or suspicion of prostate cancer. Less commonly diagnosis is accomplished by suprapubic prostatectomy (4). Unfortunately, sarcomatoid carcinoma is generally characterized by a rapid and lethal course and can be locally aggressive in presentation forming large pelvic masses. A significant proportion of these neoplasms presents with metastatic disease. Sites of metastasis include, in order of frequency, lung, bone, lymph nodes, and brain, with rare cases of metastatic spread to skin, liver, peritoneum, adrenal, pleura, and kidney (14).

The local extent of prostatic sarcomas is determined by CT or MRI scans, which provide clear delineation of the tumors from surrounding normal tissues and are important in assessing whether they are surgically resectable (29). Body CT constitutes an important component of the metastatic evaluation. In our case MRI also proved particularly useful, since it excluded extraprostatic spread of the neoplasm, but also identified a residual tumor at the right side of the transitional zone.

Due to the limited experience, there are no standard treatment recommendations the management of CSs of the prostate. Operable tumors are treated with surgery, which may be followed by radiation therapy and/or adjuvant chemotherapy, particularly in patients with positive margins or nodes. Surgeries with curative intent include radical retropubic prostatectomy, radical

cystoprostatectomy, suprapubic prostatectomy, and pelvic exenteration. Non surgical therapy (androgen ablation treatment and chemotherapy) seems to be ineffective: according to Hansel and Epstein 55,5% patients are unresponsive to chemotherapy (taxotere, estramustine, carboplatinum, or cisplatinum). It should be mentioned however that patients who receive chemotherapy usually represent the population with more advanced disease, including distant metastases and bulky local disease.

The outcome of patients with prostatic SC is poor with an actual risk of death of 20% within 1 year of diagnosis. In the largest published series, 5- and 7-year survivals were 41 and 14%, respectively (4,6). According to the existing experience, the histological pattern does not predict progression and survival (6). Other factors that did not correlate with patient outcome include history of prior carcinoma and history of prior radiotherapy. In contrast, the most important prognostic factor seems to be the stage of the disease at presentation and the presence of residual disease after surgery: patients with metastatic disease had worse overall survival than those with no metastatic disease and patients with microscopic or gross residual disease had worse overall survival than those with surgical margins free of disease (6, 16).

Conclusions

SC of the prostate is an exceedingly rare tumor, in which the demonstration of divergent but intimately admixed malignant epithelial and mesenchymal cell populations is required for appropriate diagnosis. Retrospective analyses render prostate SC as one of the most aggressive prostate malignancies. Due to the limited experience, there are no standard treatment recommendations the management of CSs of the prostate. Radiation therapy in combination with extensive TURP may delay disease progression.

List of abbreviations:

Sarcomatoid carcinoma (SC), carcinosarcoma (CS), trial without catheter (TWOC), transurethral resection of the prostate (TURP)

Consent

The authors state that written informed patient consent was obtained for publication of the report and the accompanying images.

Acknowledgment

Authors wish to thank Mr Apostolos Kontoleon of Pharmaten Hellas for the economical support of our research on prostate cancer.

References

- Randolph TL, Amin MB, Ro JY, et al. Histologic variants of adenocarcinoma and other carcinomas of the prostate: pathologic criteria and clinical significance. *Mod Pathol* 1997;10:612–629.
- Grignon DJ. Unusual subtypes of prostate cancer. *Mod Pathol*. 2004;17(3):316–27.
- Epstein JI, Algaba F, Yang XJ. Tumours of the prostate. In Eble JN, Sauter G, Epstein JI, Sesterhenn IA eds, *Tumours of the Urinary System and Male Genital Organs*, Chapter 3. Lyon: IARC-Press, 2004.
- Dundore PA, Cheville CJ, Nascimento AG, Farrow GM, Boswick DG. Carcinosarcoma of the prostate. Report of 22 cases. *Cancer* 1995;76:1035–42.
- Shannon RL, Ro JY, Grignon DJ, Ordóñez NG, Johnson DE, Mackay B, Têtu B, Ayala AG. Sarcomatoid carcinoma of the prostate. A clinicopathologic study of 12 patients. *Cancer* 1992;69:2676–82.
- Hansel DE, Epstein JI. Sarcomatoid carcinoma of the prostate: a study of 42 cases. *Am J Surg Pathol* 2006;30:1316–21.
- Delahunt B, Eble JN, Nacey JN, et al. Sarcomatoid carcinoma of the prostate: progression from adenocarcinoma is associated with p53 over-expression. *Anticancer Res* 1999;19:4279–4283.
- Lauwers GY, Schevchuk M, Armenakas N, et al. Carcinosarcoma of the prostate. *Am J Surg Pathol* 1993;17:342–349.
- Mostofi FK, Price EB. Malignant tumors of the prostate. In: *Atlas of Tumor Pathology: Tumors of Male Genital System*, series 2, part 8. Washington, DC: Armed Forces Institute of Pathology 1973; 257–258.
- Luque Barona RJ, González Cámpora R, Vicioso Recio L, Requena Tapias MJ, López Beltrán A. Synchronous prostatic carcinosarcoma: report of 2 cases and review of the literature. *Actas Urol Esp* 2000;24(2):173–8.
- Humphrey PA. Variants of Prostatic Carcinoma in Prostate Pathology. ASCP Press: Chicago, IL, 2003.
- Lopez Beltran A. Benign and malignant stromal lesions of the prostate *Adv Prost Pathol* 1999;32(3):374–75.
- World Health Organization Classification of Tumors: Pathology and Genetics of Tumors of the Urinary System and Male Genital Organs. Lyon: IARC Press, 2004.
- Mazzucchelli R, Lopez-Beltran A, Cheng L, Scarpelli M, Kirkali Z, Montironi R. Rare and unusual histological variants of prostatic carcinoma: clinical significance. *BJU Int* 2008;102(10):1369–74.
- Poblet E, Gomez-Tierno A, Alfaro L. Prostatic carcinosarcoma: a case originating in a previous ductal adenocarcinoma of the prostate. *Pathol Res Pract* 2000; 196: 569–72.
- Berney DM, Ravi R, Baithun SI. Prostatic carcinosarcoma with squamous cell differentiation: a consequence of hormonal therapy. Report of two cases and review of the literature. *J Urol Pathol* 1979;11:123–32.
- Rogers CG, Parwani A, Tekes A, Schoenberg MP, Epstein JI. Carcinosarcoma of the prostate with urothelial and squamous components. *J Urol* 2005;173:439–40.
- Wick MR, Brown BA, Young RH, Mills SE. Spindle-cell proliferations of the urinary tract: an immunohistochemical study. *Am J Surg Pathol* 1988;12:379.
- Wick MR, Swanson PE. Carcinosarcomas: current perspectives and an historical review of nosological concepts. *Semin Diagn Pathol* 1993;10:118–127.
- Wick MR, Young RH, Malvesta R, Beebe DS, Hansen JJ, Dehner LP. Prostatic carcinosarcomas. Clinical, histologic, and immunohistochemical data on two cases, with a review of the literature. *Am J Clin Pathol* 1989;92:131–9.
- Hamlin WB, Lund PK. Carcinosarcoma of the prostate: A case report. *J Urol* 1967;97:518–522.
- Ray ME, Wojno KJ, Goldstein NS, Olson K, Shah R, Cooney K. Clonality of sarcomatous and carcinomatous elements in sarcomatoid carcinoma of the prostate. *Urology* 2006;67:423.e5–e8.
- Perez N, Castillo M, Santos Y, Truan D, Gutierrez R, Franco A, Palacin A, Bombi JA, Campo E, Fernandez PL. Carcinosarcoma of the prostate: two cases with distinctive morphologic and immunohistochemical findings. *Virchows Arch* 2005;446:511–516.
- Canfield SE, Gans TH, Unger P, et al. Postradiation prostatic sarcoma: de novo carcinogenesis or dedifferentiation of prostatic adenocarcinoma? *Tech Urol* 2001;7:294–295.
- Miedler JD, MacLennan GT. Leiomyosarcoma of the prostate. *Urol*. 2007;178(2):668.
- Ren FY, Lu JP, Wang J, Ye JJ, Shao CW, Wang MJ. Adult prostate sarcoma: radiological-clinical correlation. *Clin Radiol* 2009;64(2):171–7.
- Mannan R, Chufal S.S, Misra V, Singh PA et al: Sarcomatoid carcinoma of prostate with alveolar rhabdomyosarcomatous pattern *Jour Clin Diag Res* 2008;2:1009–1012.
- Renshaw AA, Granter SR. Metastatic, sarcomatoid, and PSA- and PAP-negative prostatic carcinoma: diagnosis by fine-needle aspiration. *Diagn Cytopathol*. 2000;23(3):199–201.
- Antoun H, Leguen O, Vieillefond A, Blanchet P, Bléry M. Imagerie d'un léiomyosarcome prostatique et apport de l'irm. *J Radiol* 1997;78:453–456.