

Abdominal emergency in young women: gynecological or bowel disease? Two case reports

M. ASSENZA, P. BARTOLUCCI, V. ROMEO, M. TASCIOTTI, T. RICCIARDULLI,
I. ZANNINI, E. SACCO, C. MODINI

SUMMARY: Abdominal emergency in young women: gynecological or bowel disease? Two case reports.

M. ASSENZA, P. BARTOLUCCI, V. ROMEO, M. TASCIOTTI,
T. RICCIARDULLI, I. ZANNINI, E. SACCO, C. MODINI

Abdominal pain is a frequent symptom in Emergency Departments. Often is not so easy make a diagnosis of cause. Particular importance in young women has differential diagnosis with gynecological diseases. Often laboratory exams have not good specificity. US and TC are the imaging techniques most used to make a diagnosis, but both have our limits. Definitely surgeon's experience is the most important resource for a correct approach to abdominal pain.

We present two cases of low abdominal pain in young women due to ovarian teratoma erroneously diagnosed as appendicitis.

RIASSUNTO: Emergenza addominale nelle giovani donne: urgenza ginecologica o digestiva? Contributo clinico.

M. ASSENZA, P. BARTOLUCCI, V. ROMEO, M. TASCIOTTI,
T. RICCIARDULLI, I. ZANNINI, E. SACCO, C. MODINI

Il dolore addominale è un sintomo frequente nei Dipartimenti di Emergenza. Spesso non risulta semplice giungere ad una diagnosi specifica. Nelle donne di giovane età acquista particolare importanza discutere una diagnosi differenziale con le patologie di pertinenza ginecologica. Gli esami di laboratorio non hanno elevata specificità. L'ecografia e la TC sono le tecniche radiologiche più utilizzate ai fini diagnostici, ma entrambe hanno i loro limiti. Certamente l'esperienza del chirurgo risulta la principale risorsa nell'approccio e nella gestione delle patologie causa di dolore addominale.

Presentiamo due casi di dolore addominale in giovani pazienti dovuto a teratoma ovarico erroneamente diagnosticato come appendicite.

KEY WORDS: Teratoma - Gynecological emergency.
Teratoma - Emergenza ginecologica.

Introduction

Abdominal pain is the presenting complaint symptom in 1.5 percent of office-based visits and in 5 percent of Emergency Department visits (1). It is a common reason for surgical consultation in the emergency department and is the most common symptom which the surgeon on-call has to evaluate.

Abdominal pain can derive by surgical, urological, gynecological or medical diseases. Differential diagnosis for low abdominal pain can be difficult, especially in

young woman, between surgical or gynecological causes. Acute abdominal pain due to gynecological diseases is more frequent in women of fertile age whereas in childhood and adolescence is occasional and it is rare in post-menopause age (2). The most common gynecological causes of acute abdomen are ectopic pregnancy, ruptured ovarian follicle, twisted ovarian cyst, salpingitis or pelvic inflammatory disease (2-3). In both cases laboratory tests often shows only an increase of inflammation index, particularly leucocytosis with neutrophilia. US is the primary level imaging technique used for diagnosis, but it has not an excellent sensibility. CT results the gold standard but it has some application limits.

We present two cases of ovarian teratoma in young women erroneously diagnosed as appendicitis. Teratoma is a bizarre tumor, usually benign, that belongs to a class of tumors known as nonseminomatous germ cell tumor (NSGCT).

"Sapienza" University of Rome
Emergency Department
(Chief: Prof. C. Modini)
U.O.C. Emergency and Trauma Surgery

© Copyright 2011, CIC Edizioni Internazionali, Roma

Case report

Case 1

A 20 years old nulligravida female at 10th day after period presented to our Emergency Department with a 24-hours history of pelvic pain, originated in epigastric region and later shifted in the right lower quadrant, without fever or nausea.

After a previous gynecologic examination, patient was visited by the surgeon. Physical examination revealed positive abdominal rebound tenderness in the right lower quadrant without palpable mass. Results of laboratory studies showed leucocytosis (14.400) with neutrophilia (77,1%), normal β hCG level and urinalysis positive for ketones. An emergency US was not valuable for intense meteorism. The patient was transferred to surgery with suspicious diagnosis of acute appendicitis. She underwent surgery. After appendectomy through McBurney incision, the exploration of pelvic cavity showed a left ovarian mass (Fig. 1); so we decided to continue the procedure through a low abdominal midline incision. A shiny, white, large cystic mass was found in the left ovary: its capsule was broken with leak of gelatinous substance (Fig. 2). Histology revealed appendix with under-mucosal lymphomatosis and cystic mature teratoma of left ovary.

Case 2

A 40 years old female presented to our Emergency Department with a 12-hours history of pelvic pain and vomit, without fever.

Physical examination revealed positive abdominal rebound tenderness in the right lower quadrant with positive Blumberg. Rectal examination revealed Duoglas tenderness. Laboratory evaluation showed elevated white blood cell count (WBC 17.300) with neutrophilia (84,9%) and urinalysis positive for red blood cell. Patient was brought to surgery for appendectomy. The clinical examination after anaesthesia allowed to palpate an endoabdominal mass, so the surgeon decided to submit the woman to abdominal TC. This examination proved a 9 x 15 cm mass on the right side and a 6 x 7 cm left-sided pelvic mass (Fig. 3). These images were compatible with diagnosis of bilateral ovarian teratomas. The right one probably twisted mini-laparotomy was performed and the radiological diagnosis was confirmed. The abdominal cavity was explored with a low midline incision. A dark purple-black mass was found in the right side of the abdomen, confirming torsion and necrosis of the right ovary (Fig. 4). Which was excised the left ovary was found to have a large cystic teratoma. An ovarian cystectomy was performed with preservation of normal ovarian tissue and Fallopian tube. Histology revealed two mature teratomas containing hairs, glands, calcifications and white clotted substance.

Discussion

Lower quadrant pain in young women can result a diagnostic dilemma between bowel and gynecological diseases. According to Najem et al., the epigastric pain of appendicitis with a shift to the lower quadrant can occur in case of other peritoneal inflammation, like gynecological ones (4). Often these patients are admitted to hospital with generic diagnosis of abdominal pain, but only the 4% had diagnosis of gynecological disease (5).

Gynecological diseases that can result in acute abdomen are ovarian mass, ectopic pregnancy, ruptured ovarian follicle, twisted ovarian cyst and salpingitis or pelvic inflammatory disease. They present most often

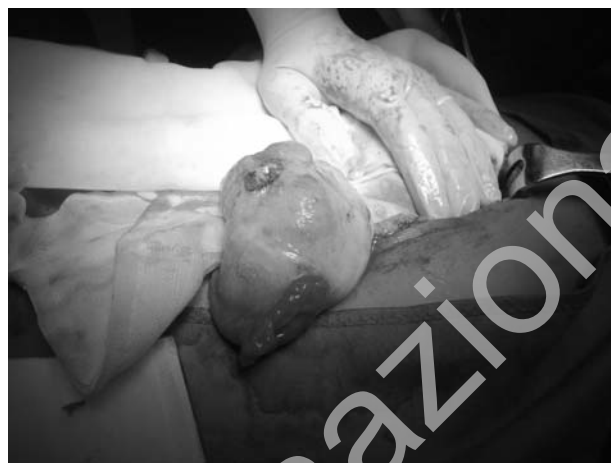

Fig. 1 - Intraoperative image of left ovarian mass (case 1).

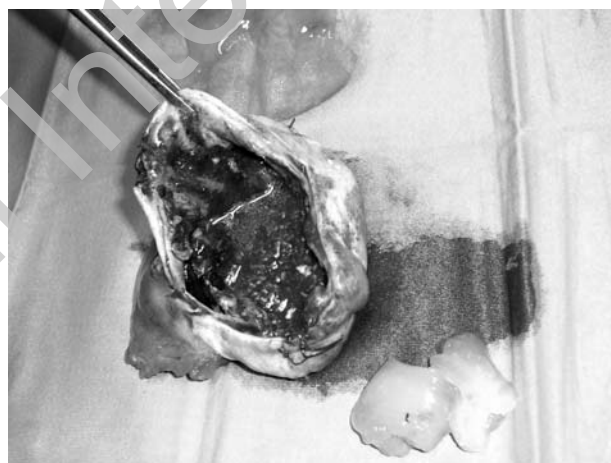


Fig. 2 - Left ovarian teratoma (case 1).

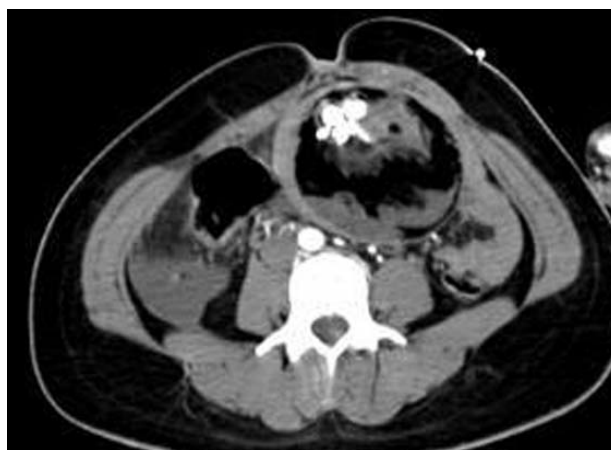

Fig. 3 - TC image of twisted ovarian right teratoma (case 2).

whit abdominal complaints that may imitate other pathologies such as appendicitis (6).

Untreated appendicitis mortality is high, mainly because of peritonitis and shock (7). Incidence is 1-2 cases/1000 people for year, especially aged 20-30. A pregnancy test is vital in all women of child bearing age, as ectopic pregnancies and appendicitis present with similar symptoms.

Imaging are often necessary for the diagnosis of pelvic pathology in women. Ultrasound is accepted as the primary imaging technique. It can show ovarian or uterine masses, but often results inaccurate in sensibility or in characterizing lesions in the female pelvis (8). CT of abdomen and pelvis is the gold standard. It is considered the most sensitive and specific in confirming diagnosis, but it has several limitations in women during reproductive years for high radiation level. MRI is superior to ultrasound and CT for diagnosis, but is no more used in emergency.

Helpful diagnostic support could be given by laboratory exams, but these don't have high sensibility and specificity, moreover specific gynecologic disease parameters are not available during emergency regimen. Beta-hCG levels are the most used parameter for preliminary diagnosis, and have to be quantified in all women during reproductive years with lower abdominal pain (9).

For many authors the laparoscopic approach represent the gold standard, but this kind of procedure is possible only for limited abdomen masses and depends on surgeon's experience.

We presented two cases of acute abdomen due to ovarian teratoma, wrongly diagnosed as appendicitis. Teratoma is most common form of ovarian tumor in women accounting for 25% to 42.8% of all ovarian neoplasm (10, 11).

The word *teratoma* comes from classical Greek and means roughly "monstrous tumor". It belongs to a class of tumors known as nonseminomatous germ cell tumor (NSGCT). They results from abnormal development of pluripotent cells: germ cells and embryonal cells. The most frequent type is the mature cystic teratoma that typically contains mature tissue of ectodermal, mesodermal and endodermal origin. The most common complica-

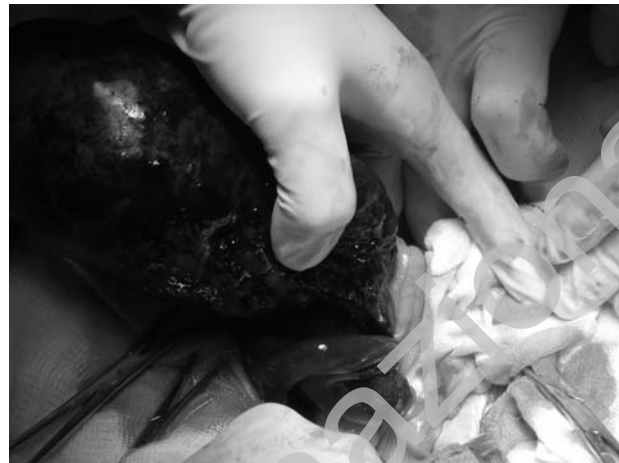


Fig. 4 - Torsion of right ovarian teratoma (case 2).

tion of mature cystic ovarian teratoma is torsion, rupture is less frequent. The risk of torsion, like in the case 2, is approximately 15%. It may be caused by the quantity of the content, causing them to float into the peritoneal cavity, this way promoting twisting of annexa (12). The incidence of perforation, like in the case 1, varies between 0.2% and 2.5% and the typical outcome is insidious intraperitoneal leakage that results in granulomatous peritonitis (13). Definitive diagnosis of a teratoma is based only on its histology.

Of course correct diagnosis is essential to choose correct therapy. In fact if acute appendicitis generally needs an emergency treatment for possible severe complications, some gynecological diseases should be managed with conservative or postponed treatment. Gynecological diseases that need an emergency treatment are haemorrhagic ovarian cyst with haemodynamic instability, breaking of tubarian abscess, twisted ovary and breaking of extrauterine pregnancy. Teratoma could be treated in elective regimen, but in our cases these tumors were treated in emergency because of perforation and twisting.

Initial accurate differential diagnosis could permitted the best surgical approach; therefore we emphasize the importance of guidelines to choose most efficient diagnostic tools.

References

1. Kamin RA, Nowicki TA, Courtney DS, Powers RD. Pearls and pitfalls in the emergency department evaluation of abdominal pain. *Emerg Med Clin North Am.* 2003;21(1):61-72.
2. Burnet LS. Gynecologic causes of the acute abdomen. *Surg Clin North Am* 1988;68:385-98.
3. Tarrazza HM, Moore RD. Gynecologic causes of the acute abdomen and acute abdomen in pregnancy. *Surg Clin North Am* 1997;77:1371-93.
4. Najem AZ, Barillo DJ, Spillert CR, et al: Appendicitis versus pelvic inflammatory disease: a diagnostic dilemma. *Am Surg* 1985; 51:217.
5. Assenza M, Romagnoli F, Bartolucci P, Tomei B, Ricci G, Modini C. inquadramento e gestione dell'addome acuto di origine ginecologica in un Dipartimento di Emergenza ed Accettazione di II livello. *Analisi di 103 casi. Chirurgia Italiana* 2003; 55: 841-847.
6. Pomeranz AJ, Sabnis S. Misdiagnoses of ovarian masses in chil-

- dren and adolescents. *Pediatric Emergency Care* 2004; 20: 172-174.
7. Hobler, K. (Spring 1998). "Acute and Suppurative Appendicitis: Disease Duration and its Implications for Quality Improvement" *Permanente Medical Journal* 2 (2).
 8. Balan P. Ultrasonography, computed tomography and magnetic resonance imaging in the assessment of pelvic pathology. *European Journal of Radiology* 2006; 58: 147-155.
 9. Martin RF, Rossi RL. The acute abdomen. An overview and algorithms. *Surg Clin North Am* 1997; 77: 1227-43.
 10. Robboy SJ, Duggan MA, Kurman RJ. The female reproductive system. In: Rubin E, Farber JL eds. *Pathology*, 3rd ed. Philadelphia: Lippincott-Raven Publishers, 1999:1011.
 11. Ayhan A, Bukulmez O, Genec C, et al. Mature cystic teratomas of the ovary: case series from one institution over 34 years. *Eur J Obstet Gynecol Reprod Biol* 2000;88:153Y7.
 12. Berek JS, Adashi EY, Hillard PA, eds. *Novak's Gynecology*. 12th ed. Baltimore, Md: Williams & Wilkins; 1996:365.
 13. Peterson WF, Prevost EC, Edmunds FT, et al. Benign cystic teratomas of the ovary: a clinico-statistical study of 1,007 cases with a review of the literature. *Am J Obstet Gynecol* 1955;70:368-82.
-