

Schwannoma of median nerve at the elbow. Case report and short review of the literature

A. MARIOTTINI, B. CARANGELO, G. PERI, D. TACCHINI¹, V. MOURMOURAS¹,
M. MUYA, L. PALMA, A. ZALAFFI

SUMMARY: Schwannoma of median nerve at the elbow. Case report and short review of the literature.

A. MARIOTTINI, B. CARANGELO, G. PERI, D. TACCHINI,
V. MOURMOURAS, M. MUYA, L. PALMA

The Authors present a case of rare elbow localization of schwannoma of the median nerve, in 42 year old woman. The surgical treatment and the short follow-up are presented.

RIASSUNTO: Schwannoma del nervo mediano al gomito. Descrizione di un caso e revisione della letteratura.

A. MARIOTTINI, B. CARANGELO, G. PERI, D. TACCHINI,
V. MOURMOURAS, M. MUYA, L. PALMA

Gli Autori presentano un caso di neurinoma del nervo mediano, a rara localizzazione nel gomito, associato ad anomala divisione dello nervo in una donna di 42 anni. Sono descritti il trattamento chirurgico e il follow-up.

KEY WORDS: Schwannoma - Peripheral nerve surgery - Median nerve - Magnetic resonance.
Schwannoma - Chirurgia dei nervi periferici - Nervo mediano - Risonanza magnetica.

Introduction

Schwannomas are benign nerve tumours arising from the neural sheath of peripheral nerves (1-4): malignant transformation is extremely rare (5). The term neurinoma dates back to 1910, when Verocay postulated that this tumour was histologically to be distinguished from neurofibromas (6). He also postulated that this tumour arises from Schwann cells (7).

According to its origin, in the Anglo-American literature the tumour is called neurilemmoma or schwannoma. It presents as an isolated mass with a diameter ranging from 1 to 250 mm and it is characterized by a non infiltrating pattern of growth (8-10). In many cas-

es it is found incidentally as a painless mass but it may cause neurological symptoms by compressing surrounding tissues/ structures. Most of them are sporadic or expression of neurofibromatosis type two (11,12). They represent 5% of benign soft tissue tumors (3) and the incidence is 5% in adults and 2% in children (14). Sometimes schwannoma is associated to a tingling sensation or pain.

Most lesions are solitary and present as slow-growing masses, usually painless, that can be removed without injury to the nerve fibers (15,16) In some cases these tumors compress the surrounding tissues and lead to compressive neuropathy.

The common site of recurrence include the spinal roots and peripheral nerves on the flexor area of the upper limbs and the posterior aspect of the lower limbs (17).

Histologically, the schwannomas consist of two different types of cells: the Antoni A, which are dense spindle cells, and the Antoni B, which are loosely arranged.

For surgical treatment of neurinomas of the median nerve, few case reports and small series are described in medical literature.

The aim of the present study is to report a case of a rare location of schwannoma of the median nerve at the elbow.

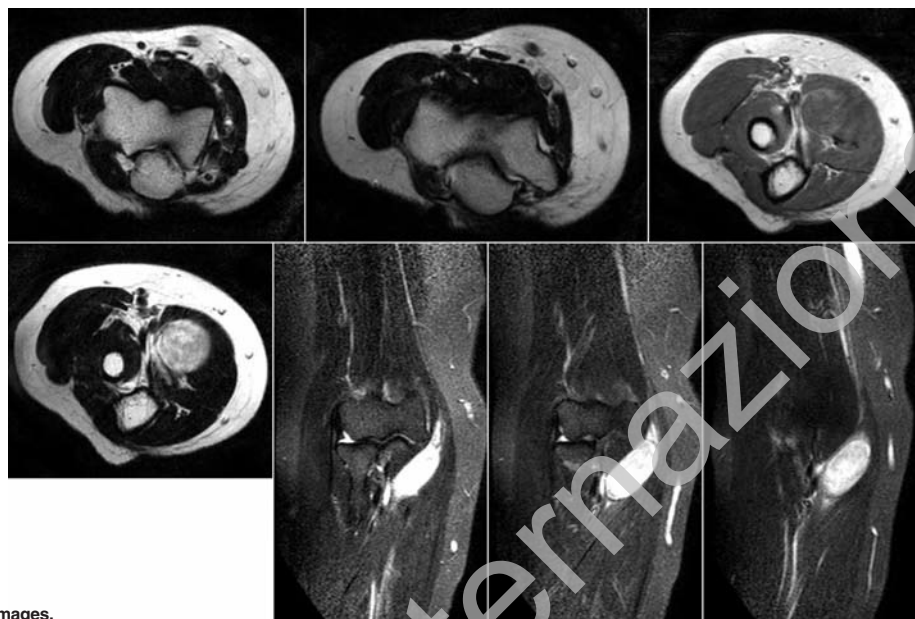


Fig. 1 - Preoperative magnetic resonance images.

Case report

A 42-years old female painter, with an history of two years of pain and heavier and heavier paresthesias on right forearm. Electromyography was negative. Ultrasound reveals oval hyperechoic lesion of uncertain interpretation, to be defined by MRI. She was admitted to our department after several months of paresthesia and pain.

Physical examination revealed a tumour mass, identified by palpation at the elbow, that appeared transversally mobile but fixed on the longitudinal medial nerve axis; a motor and a sensitive deficit was present.

Magnetic resonance imaging (MRI) revealed at the right elbow, in the anteromedial front, at a plane passing through the ulnar Koronis apophysis, solid well-defined neoplasm, compressing the round pronator muscle. The lesion appears hyperintense in T1-weighted sequences and hyperintense in T2-weighted sequences. The injection of gadolinium shows the impregnation of a small mass (Fig. 1).

The patients underwent surgery in general anesthesia. A skin S-incision was outlined on the internal face of the right elbow. The mass was found below the pronator muscle by blunt dissection. The neoplasm is in clear continuity with the median nerve, has a globular shape and is entirely englobed in it. Some thin threads of the nervous trunk are gently dissected to free the tumor without damage of the nerve. The mass is entirely removed. The main trunk of the nerve appears oedematous but in continuity (Fig. 2).

Pathologic examination showed a solitary yellowish, 22x21x33 cm well-circumscribed mass with cystic area (Fig. 3).

This finding is found in large-sized schwannomas that could be mistaken for ganglia, causing an incorrect intra-operative diagnosis (18). Microscopic appearance shows areas where nuclei are arranged in parallel rows termed "nuclear palisading" or in an organoid arrangement (Verocay bodies). Mitoses are rare or extremely scanty. The pathologist confirmed the diagnosis of benign schwannoma Antoni's type A (Figs. 4 and 5).

In the following days the patient showed a marked improvement of symptoms and was discharged in postoperative IV day without complications.

After 3 months MR shows the complete healing (Fig. 6). The

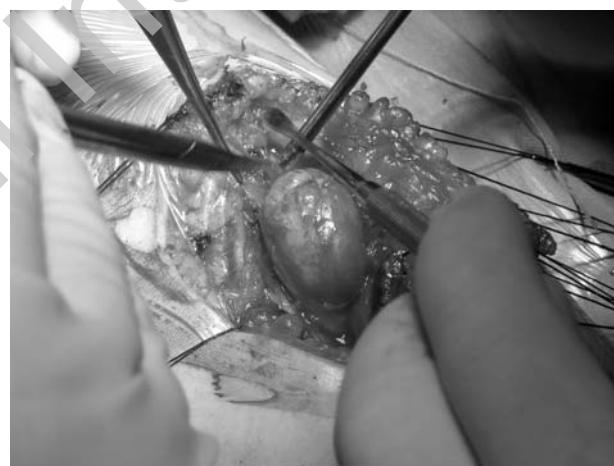

Fig. 2 - Enucleation of the schwannoma arising in the median nerve at the elbow.

patient was pain-free and the motor and sensitive deficits were resolved.

Discussion

Schwannomas are the most common benign tumors developing in peripheral nerves arising from the Schwann cells of the nerve sheath. It presents in 95% of cases as an isolated mass (8) with a diameter ranging from 10mm to 250mm (9) with noninfiltrating pattern of growth. It is often found incidentally as painless mass but may cause symptoms by compressing surrounding tissues.

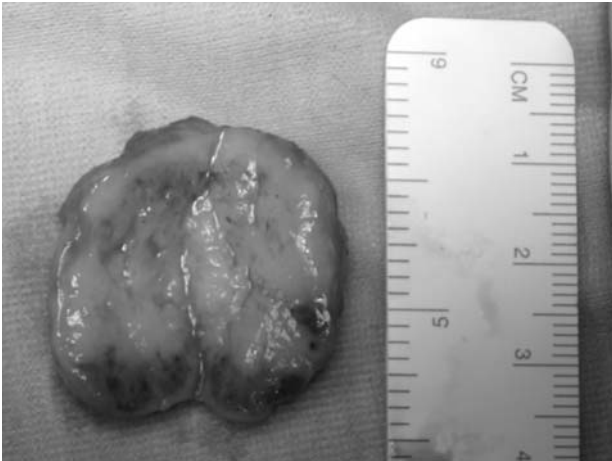


Fig. 3 - The size of the resected tumour.

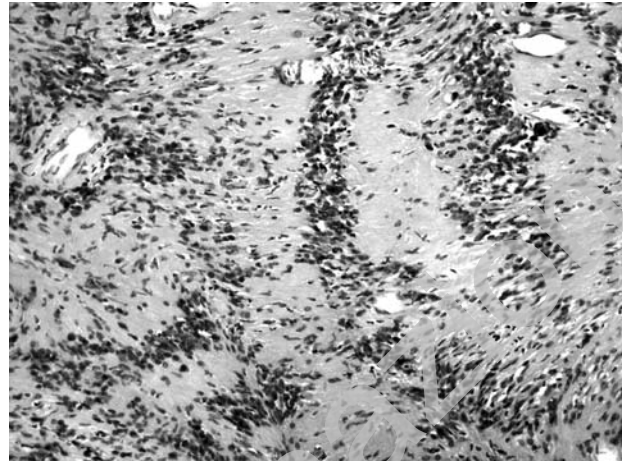

Fig. 5 - Schwannoma-cell nuclear palisading with Verocay bodies. O.M.: 100x; H.E.

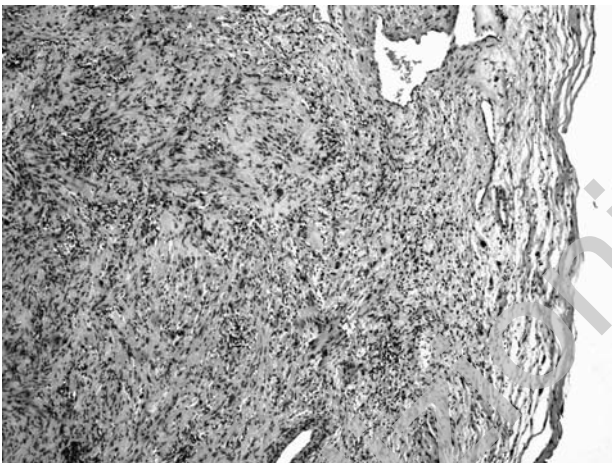


Fig. 4 - Encapsulated schwannoma composed with Antoni A cells. Haematoxylin&Eosin (H.E.).

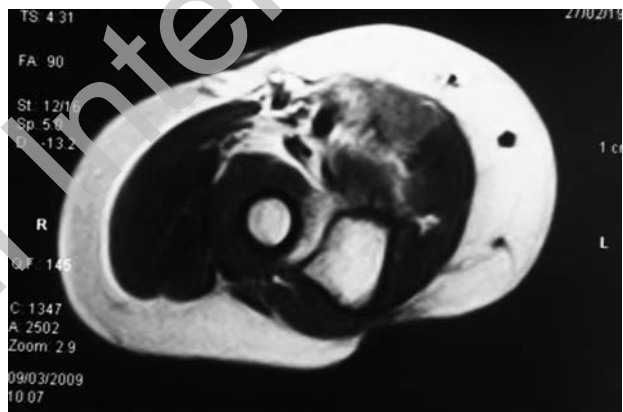


Fig. 6 - Magnetic resonance three months after surgery shows the complete recovery.

The possibility of a wrong diagnosis is high because of the lack of specific clinical signs. Padua et al. (19) reported five cases of schwannoma of the median nerve that simulated the carpal tunnel syndrome. Oberle et al. (20) established the diagnosis of a peripheral nerve neuroma by a combination of symptoms: visible or palpable mass in the way of a peripheral nerve, pain, paraesthesiae or neurological deficits corresponding to the nerve. According to Phalen et al. (13), schwannomas of the hand and wrist are sometimes mistaken for a ganglion because they can exhibit cystic areas. However deep-seated masses that have been present for a long time, are located over in the way of a nerve and are transversally but not longitudinally mobile compared to the nerve are suggestive for schwannoma (21,22).

Tinel's sign has been reported in 4 to 79% (23,24) of cases as reported by Artico et al. and by Silver et al.

Many methods have been reported to help an accurate diagnosis. Akerman (25) uses a fine needle biopsy but Vincent et al. (26) recommended the use of ultrasonography during percutaneous biopsy to show the relations between the tumour and the surrounding tissues and anatomic structures.

The best method for the diagnosis of schwannomas is magnetic resonance imaging (MRI) that can give news on the origin of the tumour and relationship with the peripheral nerve and surrounding structures to avoid intraoperative lesions (28,32). Although Computerized Tomography (CT) scan and MRI can provide morphologic data on the tumour but can not provide dynamic information. Sonography offers detailed images during active and passive flexion and extension manoeuvre (33).

According to Yao Lang et al. (15), high resolution sonography may help the surgeon to preserve not directly involved

thin threads of the nervous trunk during excision.

Conclusions

Peripheral nerve tumors of the arm and forearm are not frequent. The median nerve neurinoma at the elbow

is a very rare location and the excision by an experienced surgeon is the right therapy.

The careful dissection of the nerve to remove this benign tumor is of paramount importance to preserve the function of the affected nerve.

In our case pre-operative neurological deficits improved following surgery.

References

1. Weiss SW, Goldblum JR, Enzinger FM. Benign tumours of the peripheral nerves. In: Weiss S, Goldblum JR, eds. *Enzinger and Weiss's soft tissue tumours*. Fourth ed. St. Louis: Mosby 2001:1111-208.
2. Giannini C. Tumors and tumor-like conditions of peripheral nerves. In: Dyck PJ, Thomas PK, eds. *Peripheral Neuropathy*. Fourth ed. Philadelphia: Elsevier Saunders, 2005: 2585-606.
3. Hoglund M, Muren C, Engkvist O. Ultrasound characterized of five common soft tissue tumours in the hand and forearm. *Acta Radiol* 1997;38:348.
4. Woodruff JM, Selig AM, Crowley K, Allen PW. Schwannoma (neurilemmoma) with malignant transformation: a rare distinctive peripheral nerve tumour. *Am J Surg Pathol* 1994;18:882-95.
5. Verokay J. Zur Kenntnis der "neurofibrome". *Beitr Pathol Anat Allg Pathol* 1910; 48: 1.
6. Stout AP. The peripheral manifestations of the specific nerve sheath tumor (Neurilemmoma). *Am J Cancer* 1935: 24: 751
7. Takase K, Yamamoto K, Imakiire A. Clinical pathology and therapeutic results of neurilemmoma in the upper extremity. *J Orthop Surg* 2004; 12:222-225.
8. Ogose A, Hatta T, Morita T. Tumours of peripheral nerves: correlation of symptoms, clinical signs, imaging features and histologic diagnosis. *Skeletal Radiol* 1999;28:183-188.
9. Kang HJ, Shin SJ, Kang ES. Schwannomas of the upper extremity. *J Hand Surg Br* 2000;25:604-607.
10. Fletcher JA. Cytogenic analysis of soft tissue tumours. In: Weiss SW, Goldblum JR, eds. *Enzinger and Weiss's soft tissue tumours*. Fourth ed. St. Louis: Mosby 2001: 103-124.
11. Meltzer PS. Molecular genetics of soft tissue tumours. In: Weiss SW, Goldblum JR, eds. *Enzinger and Weiss's soft tissue tumours*. Fourth ed. St. Louis: Mosby 2001:1146.
12. Forthman CL, Blazar PE. Nerve tumors of the hand and upper extremity. *Hand Clin* 2004;20:233-242.
13. Kang HJ, Shin SJ, Kang ES. Schwannomas of the upper extremity. *J Hand Surg* 2000; 25:604.
14. Stull MA, Moser RP, Kransdorf MJ, et al. Magnetic resonance appearance of peripheral nerve sheath tumours. *Skeletal Radiol* 1991;20:9.
15. Hoglund M, Muren C, Engkvist O. Ultrasound characteristics of five common soft-tissue tumors in the hand and forearm. *Acta Radiol* 1997;38:348.
16. Padua L, Pazzaglia C, Insoia A, Aprile I, Rampoldi M, Bertolini C, Tonali P. Schwannoma of the median nerve (even outside the wrist) may mimic carpal tunnel syndrome. *Neurol Sci* 2006; 26: 430.
17. Oberle J, Kahamba J, Richter H.P. Peripheral nerve Schwannoma: an analysis of 16 patients. *Acta Neurochir* 1997; 139: 949-953.
18. Phalen GS. Neurilemmomas of the forearm and hand. *Clinical Orthopaedics and Related Research* 1976; 114: 219-222.
19. Inoue M, Kawano T, Matsumura H, et al. Solitary benign Schwannoma of the brachial plexus. *Surgical Neurology* 1983; 20: 103-108.
20. Kehoe NJS, Reid RP, Semple JC. Solitary benign peripheral nerve tumours: review of 32 years experience. *Journal of Bone and Joint Surgery* 1995; 77: 497-500.
21. Artico M, Cervoni L, Wierzbicki V, D'Andrea V, Nucci F. Benign neural sheath tumours of major nerves: characteristics in 199 surgical cases. *Acta Neurochirurgia* 1997; 139:1108-1116.
22. Silver M, Patel MR. Preoperative diagnosis of a forearm peripheral schwannoma. *Orthopaedic Review* 1993; 22: 714-716.
23. Akerman M, Idvall I, Rydholm A. Cytodiagnosis of soft tissue tumours and tumour-like conditions by means of fine needle aspiration biopsy. *Archives of Orthopedic Trauma Surgery* 1980; 96: 61-67.
24. Vincent LM. Ultrasound of soft tissue abnormalities of the extremities. *Radiologic Clinics of North America* 1998; 26: 131-143.
25. Chmn DH, Fally RA, Callen PW. Unusual ultrasonographic appearance of a solid Schwannoma. *J Clin Ultrasound* 1982; 10:243-245.
26. Hughes DG, Wilson DJ. Ultrasound appearance of peripheral nerve tumours. *Br J Radiol* 1986; 59: 1041-1043.
27. Fornage BD. Peripheral nerves of the extremities: imaging with US. *Radiology* 1988;167: 179-182.
28. Graif M. Peripheral nerves. *Clin Diagn Ultrasound* 1995; 30: 73-83.
29. De Pra L, Derchi LE, Balconi G. Peripheral nerves in: Solbiati L, Rizzato G, Chanboneau JW. *Ultrasound of superficial structures. High frequencies, doppler and interventional procedures*. New York: Churchill Livingstone, 1995.
30. Fornage BD. Peripheral nerves of the extremities: imaging with US. *Radiology* 1988; 167:179.
31. Yao-lung K, Wey-Jen Y, Haw-Yen C. Role of sonography in the preoperative assessment of neurilemmoma. *J Clin Ultrasound* 2005; 33:87-89.
32. Donner TR, Voorhies RM, Kline DG. Neural sheath tumors of major nerves. *J Neurosurg* 1994; 81: 362-373.