

## Management of corrosive injuries of the upper gastrointestinal tract. Our experience in 58 patients

U. ROBUSTELLI, R. BELLOTTI, F. SCARDI, M. FORTUNATO ARMELLINO, A. DE MASI,  
A.L. FORNER, E. RICCIO<sup>1</sup>, F. MANGUSO<sup>1</sup>

**SUMMARY:** Management of corrosive injuries of the upper gastrointestinal tract. Our experience in 58 patients.

U. ROBUSTELLI, R. BELLOTTI, F. SCARDI, M. FORTUNATO ARMELLINO,  
A. DE MASI, A.L. FORNER, E. RICCIO, F. MANGUSO

**Background.** *The ingestion of caustic substances is one of the most difficult conditions to be treated in Emergency Department.*

**Patients and methods.** *The medical records of patients with caustic ingestion and hospitalized from 2003 to 2008 at the Division of General Emergency Surgery with Polyspecialistic Observation of AORN "A. Cardarelli" in Naples, have been revalued.*

**Results.** *From 2003 to 2008, 58 patients with caustic ingestion were admitted to our Division. Ten of these patients (17.24%) underwent surgery. Six patients underwent oesophageal and gastric resection with cervical esophagostomy and alimentary digiunostomy in emergency; two underwent exploratory laparotomy, two had gastroenteroanastomosis for antropyloric stenosis. One patient underwent new operation for a complication. In total, three reconstructions of oesophagus with colon were performed. Of the six patients undergoing esophagostomy, two died in the first postoperative day, but four have passed the acute phase.*

**Conclusions.** *There is no universally accepted diagnostic and therapeutic procedure for the management of these patients, who are often left - as it appears in literature - to the personal experience of the surgeon who is dealing with this situation.*

**RIASSUNTO:** *Management delle lesioni da ingestione di caustici del tratto digestivo superiore. Nostra esperienza in 58 pazienti.*

U. ROBUSTELLI, R. BELLOTTI, F. SCARDI, M. FORTUNATO ARMELLINO,  
A. DE MASI, A.L. FORNER, E. RICCIO, F. MANGUSO

**Background.** *L'ingestione di sostanze caustiche rappresenta una delle condizioni più difficili da gestire che possano presentarsi in un Dipartimento di Emergenza.*

**Pazienti e metodi.** *Sono state rivalutate tutte le cartelle di malati con riferita ingestione di caustici ricoverati dal 2003 al 2008 presso la Divisione di Chirurgia Generale d'Urgenza con Osservazione Polispecialistica della AORN "A. Cardarelli" di Napoli.*

**Risultati.** *Dal 2003 al 2008 sono stati ricoverati presso la nostra Divisione 58 pazienti (28 maschi e 30 femmine) per riferita ingestione di caustici. Dieci di questi pazienti (17,24%) sono stati sottoposti ad intervento chirurgico. Sei pazienti sono stati sottoposti ad intervento di esofagogastrectomia, con esofagostomia cervicale e digiunostomia alimentare in urgenza/emergenza, 2 a laparotomia esplorativa, 2 a gastroenteroanastomosi per stenosi pilorica. Un paziente è stato sottoposto a reintervento per una complicanza (deiscenza della digiunostomia alimentare). In totale sono state eseguite tre riconversioni (due pazienti provenienti dalla serie di sei pazienti già citata ed uno riconvertito in conseguenza di un intervento di demolizione eseguito nel 2002). Dei sei pazienti sottoposti ad intervento demolitivo, due sono deceduti nel primo postoperatorio, ma quattro hanno superato la fase acuta.*

**Conclusioni.** *Non esiste una procedura diagnostico-terapeutica universalmente accettata per questi malati la cui gestione, come sembra evincersi dalla letteratura, viene spesso lasciata all'esperienza personale del medico che si trova a gestire tale situazione.*

**KEY WORDS:** Caustic ingestion - Esophageal caustic burns - Esophagogastrectomy - Esophageal reconstruction.  
Ingestione di caustici - Lesioni esofagee - Esophagogastrectomia - Ricostruzione esofagea.

AORN "A. Cardarelli" Hospital, Naples, Italy  
UOC General and Emergency Surgery with Surgical  
and Polyspecialistic Observation

<sup>1</sup> UOSC of Gastroenterology and Digestive Endoscopy

© Copyright 2011, CIC Edizioni Internazionali, Roma

## Introduction

Caustic products are widely available and utilized in every house, but their danger is often underestimated. The ingestion of these substances is one of the most dif-

difficult condition to be treated in an Emergency Department because its effects can be immediately deadly or can determine serious and disabling sequelae involving high social, health, and human costs. Mortality due to injuries from ingestion of caustic substances (1.5%) (1-2) is only ascribed to adulthood, although the majority of poisonings occurs in children, where the event is often accidental and therefore less serious. In adulthood, instead the ingestion of toxic substances and therefore also caustic, is voluntary in at least half of the cases, and this inevitably involves higher doses, with more severe lesions and higher risk for life. The lesions resulting from ingestion of caustic substances pose considerable diagnostic and therapeutic problems in acute phase and in post-acute phase. In literature there is no standard of reference and diagnostic-therapeutic decisions often depend on the personal experience of the operators.

There are no recent data on the number of hospitalizations of patients reporting ingestion of caustics in Italy. If you browse the website of the Ministry of Health the latest data date back to 2005; this year 225 patients have been hospitalized in Italy for toxic effects from caustic or corrosive substances and 34 were in Campania (3). In the same year 11 patients were hospitalized for this condition in our division which is approximately 5% of all the hospitalized patients in Italy and 34% of the total of all patients hospitalized in Campania.

TABLE 1 - NUMBER, SEX AND THERAPY IN OUR EXPERIENCE.

| Year  | Admitted |         | Submitted to surgery |         |
|-------|----------|---------|----------------------|---------|
|       | Males    | Females | Males                | Females |
| 2003  | 5        | 4       | 1                    | 1       |
| 2004  | 6        | 6       | 0                    | 0       |
| 2005  | 3        | 8       | 0                    | 3       |
| 2006  | 8        | 7       | 2                    | 1       |
| 2007  | 5        | 3       | 1                    | 0       |
| 2008  | 1        | 2       | 1                    | 0       |
|       | 28       | 30      | 5                    | 5       |
| Total | 58       |         | 10 (17,24%)          |         |

TABLE 2 - TYPE OF SURGERY.

| Year | Oesophageal and gastric resection | Reconstruction | Surgical exploration | Gastroentero-anastomosis | Reoperation |
|------|-----------------------------------|----------------|----------------------|--------------------------|-------------|
| 2003 | 1                                 | 0              | 1                    | 0                        | 0           |
| 2004 | 0                                 | 0              | 0                    | 0                        | 0           |
| 2005 | 3                                 | 1              | 0                    | 0                        | 0           |
| 2006 | 1                                 | 0              | 1                    | 1                        | 0           |
| 2007 | 1                                 | 1              | 0                    | 0                        | 1           |
| 2008 | 0                                 | 0              | 0                    | 1                        | 0           |
|      | 6                                 | 2              | 2                    | 2                        | 1           |

## Patients and methods

The medical records of patients who reported ingestion of caustic and hospitalized at the Division (UOC) of General and Emergency Surgery of AORN "A. Cardarelli" in Naples, from 2003 to 2008, have been valued. The data of all patients undergoing surgery were extrapolated and all surgery indications have been assessed, as well as those who had surgery more often performed in emergency and those who had surgery performed under deferred emergency and the follow up of patients undergoing surgery was rated.

## Results

From 2003 to 2008, 58 patients (28 male and 30 female) were admitted to our Division (Table 1). The average stay in hospital was 7.67 days (range 20 to 178). Ten of these patients (17.24%) underwent surgery for a total of thirteen surgical procedures (Table 2). Six patients underwent esofagogastratomy with cervical esophagostomy and alimentary digiunostomy in emergency; two underwent exploratory laparotomy, two had gastroenteroanastomosis for pyloric stenosis; one patient had a new operation for a complication (dehiscence of alimentary digiunostomy). In total, three alimentary reconstructors were performed (two from the above six patients) and one resulting from esofagogastratomy carried out in 2002).

The two patients undergoing gastroenteroanastomosis for duodenal stenosis came to our observation not in the acute phase. Both reported ingestion of caustic substances about twenty days to two months prior to admission and onset of dysphagia. At endoscopy and contrast examination of gastrointestinal transit the antropyloric stenosis (Fig. 1) was confirmed in both patients. In both cases a gastroenteroanastomosis was performed to bypass the stenosis without resection of the stomach. We use this procedure, in contrast with other authors (4), because it is faster and less invasive for patients. In both cases, postoperative course was regular and the patients were discharged after about twelve days of hospitalization.

Two patients underwent exploratory laparotomy.

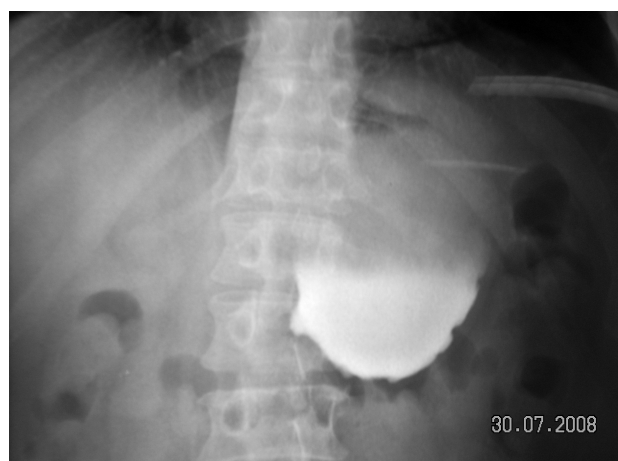


Fig. 1 - Thè radiogram shown antropyloric stenosis.

In both cases endoscopy showed third degree lesions of the gastric mucosa, but instrumental examinations showed no sign of perforation. At laparotomy, the walls of the stomach and the intra-abdominal tract of the esophagus showed neither areas of necrosis nor lesions in other organs; therefore a conservative attitude was adopted, with alimentary digiunostomy.

Six patients underwent radical surgery in emergency.

At endoscopy they all had third degree lesions and signs of esophago or gastric parietal perforation and / or necrosis at TC examination. Five patients showed involvement of the esophagus and stomach, the sixth patient showed also involvement of the I and II duodenal portion. Therefore the first five patients underwent esophagogastrectomy and the sixth also had a resection of the I and II duodenal portion with external duodenal biliary drainage.

Two of these patients died in immediate postoperative, within twenty-four hours from surgery. Four passed the acute phase: two of these underwent retrosternal esophagocoloplasty, one asked to another hospital, therefore we lack information about the follow-up, for another black patient, male, hospitalized in a long-term patient division, developed cervical esophagostomy stenosis. This situation has resulted in a clinical aspiration pneumonia that led to the patient's death about two months after the operation (Table 3).

In total, however, over the years ranging from 2003 to 2008 three patients underwent alimentary reconstructions (Table 4). Two from the above six patients and one digestive reconstruction resulting from radical surgery was carried out in 2002. Two were male patients and one was female. One of the male patients died with multiorgan failure after twenty-four hours

TABLE 3 - OUTCOME OF OESOPHAGEAL AND GASTRIC RESECTION.

| Patient, sex | Organs involved               | Type of surgery   | Outcome                | Postoperative complications     | Follow up                        |
|--------------|-------------------------------|---|------------------------|---------------------------------|----------------------------------|
| M            | Oesophagus, Stomach, Duodenum | "Esophagectomy; Gastrectomy; Partial resection of duodenum" | Exitus within 24 hours | —                               | —                                |
| M            | Oesophagus, Stomach           | Esofagogastrectomy  | Exitus within 24 hours | —                               | —                                |
| M            | Oesophagus, Stomach           | Esofagogastrectomy  | Alive                  | None                            | Reconstruction in other hospital |
| F            | Oesophagus, Stomach           | Esofagogastrectomy  | Alive                  | None                            | Reconstruction                   |
| M            | Oesophagus, Stomach           | Esofagogastrectomy  | Alive                  | Dehiscent jejunostomy           | Reconstruction                   |
| M            | Oesophagus, Stomach           | Esofagogastrectomy  | Alive                  | Exitus by ab ingestis pneumonia | —                                |

TABLE 4 - OUTCOME OF OESOPHAGUS RECONSTRUCTION.

| Patient, sex | Type of graft | Outcome                    | Postoperative complications      | Follow up |
|--------------|---------------|----------------------------|----------------------------------|-----------|
| M            | Left colon    | Exitus within 24 hours     | —                                | —         |
| M            | Right colon   | MOF syndrome within 7 days | —                                | —         |
| F            | Left colon    | —                          | Stenosis of cervical anastomosis | Alive     |

from the conversion. The other had two postoperative complications that delayed plastic surgery and influenced surgery techniques at the time of conversion. At first, despite a silicone tube placed in cervical esophagostomy, there was a stenosis of the esophagostomy associated with hypersalivation. This was treated with administration of atropine, which had only a partial effect. In addition, approximately 40 days after the first surgery, there was a dehiscence of alimentary digiunostomy that resulted in a biliary peritonitis. This required an additional surgery which consisted of resection of the 'perforated loop, peritoneal toilet, and mechanical termino-terminal anastomosis between the two ileal stumps with repackaging of alimentary digiunostomy on another loop further downstream. It was therefore necessary to extend the period of convalescence by delaying the time of reconstruction and, at the time of conversion, as a result of previous biliary peritonitis, the transverse colon was now completely inseparable from the pancreas and the wall of the abdomen, which has influenced the choice of the part of the intestine for transplantation, in this case the ascending colon and the last ileal loop (about 20 cm from the valve). The cervical anastomosis was performed between esophageal stump and ileal loop. This patient died of a multi organ syndrome seven days after the operation.

The female patient has undergone conversion by interposition of the left colon, using the technique described later. About four months from the operation and after an initial period of apparent prosperity, she developed a partial stenosis of cervical anastomosis. This condition was treated with endoscopic dilatations and the patient is currently able to feed herself in a satisfactory manner and in good health.

## Discussion

When emergency radical surgery is necessary, our goal is to remove the necrotic lesions and to save as much as possible of the organs to facilitate subsequent reconstruction. In general, the first phase of the operation is an exploratory laparotomy, which allows an accurate account of endo-abdominal injuries and can suggest the most appropriate surgical approach. In our experience, all patients had involvement of the stomach and esophagus, therefore the first step has always been the stomach preparation which was prepared in a classical way, sinking the duodenal stump with a stapler and then strengthened with a long absorption material. The following step is to prepare the esophagus. The esophago-gastric junction is completely dissected on tourniquet without sectioning it from the stomach. Then cervical incision can be performed: oblique incision me-

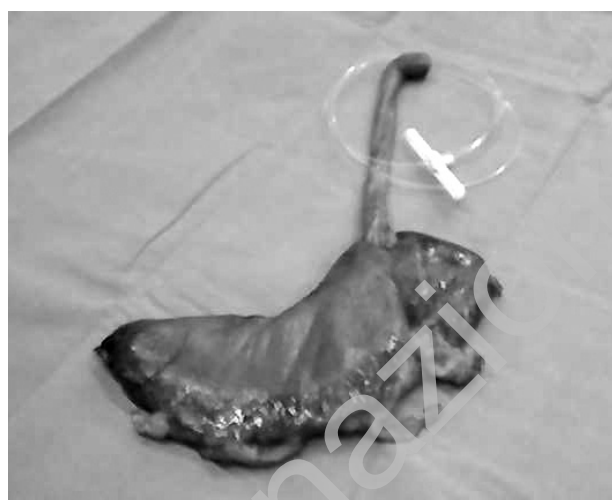

Fig. 2 - Postoperative sample after esophagogastric resection.

dially to the border of the left sternocleidomastoid muscle. Beyond the lateral margin of the thyroid lobe, the esophagus is identified and removed with the help of a nose gastric device or preferably of gastroscopy. The esophagus is then manually mobilized from the neck and from the abdomen. When the esophagus is completely mobile, it is cut in the cervical region, trying to leave the cranial stump free from necrotic areas. Then a small incision is performed at the lower esophagus where it enters the stomach. We introduce a vein stripper from the stomach into the pharynx, which gets out from the cervical esophageal stump and, contrary to what other authors do (5), we strip the esophagus in oral gastric direction: following bleeding is usually small. At the end of the procedure, the sample consists of the complete esophagogastric stump (Fig. 2). The operation is always completed with alimentary digiunostomy.

Before reconstructive surgery all patients undergo to Computed Tomography (CT) angiography and conventional catheter angiogram of mesenteric vessels to exclude vascular malformations. Moreover, colonoscopy is also performed to exclude concomitant diseases. Even though there is no agreement in international literature about the surgical procedure for reconstruction (4, 6-8), the use of left colon for esophageal replacement has been considered by many to be a preferable behaviour. In our series only one patient required the use of the ascending colon for replacement. During assessment of the colon and its evaluation, care is taken not to damage the vessels. After vessels identification, for left colon grafts, the left colic artery is isolated and all collaterals are clamped to assess the adequacy of the circulation of the Riolo's arcade. To minimize the possibility of intimal damage, the pressure applied by vascular clamps should not be higher than that just occluding the circulation. The vessels are not stretched with clam-



ps in place. The length to which the colon could be unfolded is limited by the vascular arcade and not by the colon itself. After this procedure, the resection of an appropriate length of healthy colon for anastomosis is performed. After cervical esophagus and retrosternal preparation, the colic segment is transferred via retrosternal space and a manual cervical termino-lateral esophagocolic anastomosis is performed. Finally, the distal anastomosis stays in the abdomen. The colon graft is joined to the jejunum. The completion of the abdominal phase includes a Roux-en-Y jejunal loop to prevent bile reflux into the colon. Colonic continuity is re-established by bringing the remaining previously mobilized right colon to the distal stump of the colon and performing an end-to-end single-layer anastomosis.

In literature there is no universally recognized procedure for the treatment of these patients. Most authors consider the 'endoscopic examination' the first examination to be executed as soon as possible, because it is the most appropriate procedure to plan more suitable diagnostic therapeutic processes and to exclude patients who do not show lesions of the gastrointestinal tract (2-5 -8- 9). Although in literature it is possible to find interesting endoscopic classifications (2) of caustic injuries, the most widely accepted (5-9) identifies three levels of lesions. Grade I: hyperaemia, erythema and / or edema of the mucosa, Grade II: superficial necrosis, Grade III: extensive necrosis and / or signs of perforation. At present there are different opinions whether to stop the examination at the first lesion identified to avoid the risk of iatrogenic perforation (9) or to continue into upper digestive tract in order to obtain a more complete staging of possible lesions (2).

When endoscopic lesions are present in the upper digestive tract, of whatever degree, we always perform X-ray examination of the abdomen and chest, and - in the presence of third degree lesions or suspected perforation - in contrast with other authors who consider useful to perform a barium contrast examination (5-9) - a chest and abdomen CT is performed. We believe this is the only procedure to study chest, mediastinum and abdomen appropriately and extensively; it also provides adequate information on the tracheo bronchial tree, without using diagnostic procedures such as bronchoscopy, which may lengthen the operation (2-8), and it helps planning an adequate surgical access to chest in case of injury to the bronchial tree (10). In addition, last generation equipment have shortened examination length.

In the presence of sure signs of instrumental perforation or endoscopic III grade injury - in agreement with

international literature (4-9) - we all claim surgery, since a delayed operation may interfere with patient's life. In case of perforation, our goal is to remove the necrosis and to save as much as possible of the organs to facilitate subsequent reconstruction. In our experience resection in urgency is still fraught with significant mortality: out of six patients undergoing esophagogastricectomy in urgency/emergency, two died within the postoperative 24 hours. However this corresponds to a percentage of 33% and it is in line with other authors' rates, ranging from 22% (5-8) 40% (4) to 66% (11).

Also the lapse of time before plastic surgery is under debate. In literature there is no agreement. Some authors recommend immediate reconstruction at the same time of radical surgery (5). Others suggest variable waiting periods: thirty days according to Tognini (2), three months according to Berthet (4), from four to eight months according to Cattani (8), more than six months according to Hang (6). We have not a well-defined time limit, but we simply wait for patient's recovering after the first surgery and reaching a good nutritional status.

As for mortality after conversion operation, there are different rates in literature, ranging from 5% according to Zhou (7) to 37.5% according to Cattani (8). However, since these are personal experiences and not controlled studies, it is not possible to value the different treatments of these patients and what affected their survival. In our experience three patients have been converted and only one is currently living.

## Conclusions

There is no universally accepted diagnostic and therapeutic procedure for the treatment of these patients, who are often left, as it appears in literature, to the personal experience of the surgeon. We believe that once we have supported the patient's vital functions, an endoscopic examination and a CT are essential for a correct classification of these patients and for proper therapeutic planning. Integrated assessment of the information provided by these two procedures may help to determine which patients should undergo conservative treatment and which surgery has to be done. In the presence of grade III endoscopic lesions or instrumental signs of perforation, in our opinion there is evidence for surgery to be performed as soon as possible, because it is the only way to improve the survival of these patients and make then possible for them to undergo a reconstructive operation that can give these patients a good quality of life.

## References

1. M.L. Farina. Ingestione di sostanze Caustiche. Dossier InFad, anno 3, n° 45, maggio 2008, Editore Zadig, Milano.
2. Tognini L., Gavinelli M., Scacchi G.L., Martino E., Padalino P., Belloli F., Tiberio G.A.M., Massari M., Tiberio G. Indicazioni alla Chirurgia d' Urgenza nelle lesioni da ingestione da caustici. Ruolo di una classificazione endoscopica originale. Chir Ital 1998;50,5-6:41-46
3. [http://www.ministerosalute.it/programmazione/sdo/ric\\_informazioni/interrogad.jsp](http://www.ministerosalute.it/programmazione/sdo/ric_informazioni/interrogad.jsp).
4. Berthet B.; Castellani P.; Brioché M.I.; Assadourian R. and Gauthier A. Early operation for severe corrosive injury of the upper gastrointestinal tract. Eur J Surg 1996; 162:951-955.
5. Makela J.T., Laitinen S. and Salo J.A. Corrosion injury of the upper gastrointestinal tract after swallowing strong alkali. Eur J Surg 1998;164: 575-580.
6. Yong Han, Qing-Shu Cheng, Xiao-Fei Li, Xiao-Ping Wang Surgical management of esophageal strictures after caustic burns: A 30 years of experience. World J Gastroenterol 2004;10(19):2846-2849.
7. Zhou J., Jiang Y., Wang R., Lin y., Gong T., Zhao Y., Zheng M. and Tan Q. management of corrosive esophageal burns in 149 cases. J Thorac Cardiovasc Surg 2005; 130:449-445.
8. Cattani P., Munoz-Bongrand N., Berney T., Halimi B., Sarfati E., Celerier M., Extensive abdominal surgery after caustic ingestion. Ann Sur 2000;231(4): 519-523.
9. Keh S.M., Onyekwelu N., McManus K., McGuigan J., Corrosive injury to upper gastrointestinal tract: still a major surgical dilemma World J Gastroenterol 2006; 12(32): 5223-5228.
10. S. Jaillard, S. Nseir, D. Métois, C. H. Marquette, J. Darras, H. Porte and A. Wurtz. Extensive corrosive injuries of the upper airways and gastrointestinal tract. J Thorac Cardiovasc Surg 2002;123:186-188.
11. Munoz E.M., Garcia – Domingo M.,I., Santiago J.R., Veloso E.V., Molina C.M. Massive necrosis of the gastrointestinal tract after ingestion of hydrochloric acid. Eur J Surg 2001;167(3):195-198(4).