

Single Stapler Parachute Technique (SSPT): a new procedure for large hemorrhoidal prolapse

A. CAVIGLIA^{1*}, M. MONGARDINI^{2*}, M. MALERBA¹, M. GIOFRÈ², A. MATURO²,
A. DEL GRAMMASTRO¹, A. STRANIERO¹, M. SCARNÒ³, F. CUSTURERI²

SUMMARY: Single Stapler Parachute Technique (SSPT): a new procedure for large hemorrhoidal prolapse.

A. CAVIGLIA, M. MONGARDINI, M. MALERBA, M. GIOFRÈ, A. MATURO,
A. DEL GRAMMASTRO, A. STRANIERO, M. SCARNÒ, F. CUSTURERI

Procedure for Prolapse and Hemorrhoids (PPH or Longo procedure), a stapled circumferential anal mucosectomy, has proven to be very popular as it is considered safe and successful. However, a high haemorrhoid recurrence rate is reported, specially due to insufficient mucosal resection. The authors have come up with a technical modification to the mucoprolapsectomy, notably the Single Stapler Parachute Technique (SSPT), in order to obtain more abundant mucosal resection. In this study they will present the results obtained in 80 patients treated for muco-haemorrhoidal prolapse, 40 of whom underwent traditional PPH, while the remaining 40 patients underwent SSPT, both performed in two different specialised centres located in Rome, Italy.

RIASSUNTO: Tecnica a paracadute con singola suturatrice (Single Stapler Parachute Technique - SSPT): una nuova procedura per i prolassi emorroidari di grandi dimensioni.

A. CAVIGLIA, M. MONGARDINI, M. MALERBA, M. GIOFRÈ, A. MATURO,
A. DEL GRAMMASTRO, A. STRANIERO, M. SCARNÒ, F. CUSTURERI

La procedura per prolasso emorroidario (PPH) o procedura di Longo, una mucosectomia anale circonferenziale meccanica, ha ottenuto notevole popolarità per la sua sicurezza ed efficacia. Ciononostante viene riportato un alto tasso di recidiva emorroidaria, dovuto in particolare a una insufficiente asportazione di mucosa. Gli Autori hanno messo a punto una variante tecnica della mucoprolassectomia con l'utilizzo di una sola suturatrice, ovvero una tecnica a paracadute con singola suturatrice (Single Stapler Parachute Technique SSPT), al fine di ottenere lembi di resezione più abbondanti. In questo lavoro presentano i risultati ottenuti in 80 pazienti trattati per prolasso muco-emorroidario, 40 dei quali operati con PPH tradizionale, 40 con SSPT, in due centri specialistici di Roma (Italia).

KEY WORDS: Hemorrhoids - Rectal prolapse - Anopexy - Mucoprolapsectomy - Longo procedure - Single Stapler Parachute Technique - SSPT.
Emorroidi - Prolasso rettale - Anopessia - Mucoprolassectomia - Procedura di Longo - Tecnica a paracadute con singola suturatrice meccanica - SSPT.

Introduction

The symptomatic haemorrhoidal prolapse is one of the most common ano-rectal disorders (1). In 1998, a new surgical technique for the treatment of such disease was introduced by Longo and it later became rather

widespread (2). This revolutionary technique is the stapled haemorrhoidectomy, better known as the Procedure for Prolapse and Hemorrhoids (PPH). It has introduced a new way of treating the haemorrhoidal disease, as it consists in a circumferential anal mucosectomy that lifts up the mucosa (anopexy). Differently from traditional treatments (such as open haemorrhoidectomy or Milligan-Morgan technique, or closed haemorrhoidectomy or Ferguson technique), with the PPH the prolapsed haemorrhoids are not removed. The operation rather restores the haemorrhoidal plexus to its original anatomical position in the anal canal so as to respect the important physiological role that the haemorrhoidal cushions have in aiding continence. This procedure has proven to be very popular among surgeons and patients alike, as it is considered safe (3) and successful (4-6). Moreover, it results

¹ Colon-Proctology Unit, "San Camillo-Forlanini" Hospital, Rome, Italy
² Department of Surgical Sciences, "Sapienza" University, Rome, Italy
³ CASPUR (Consorzio interuniversitario per le Applicazioni di Supercalcolo per Università e Ricerca), Rome, Italy

*These authors contributed equally to the study

© Copyright 2011, CIC Edizioni Internazionali, Roma

in reduction of postoperative pain (7), operative time, and hospital stay, as well as it shortens recovery time (8), which allows for a faster return to normal activities (9). However, several studies have also reported a higher haemorrhoid recurrence rate as compared to conventional haemorrhoidectomy procedures (10–15). In some cases, this could be due to insufficient mucosa removal or incomplete mucosa lifting in patients who show asymmetry of the rectal prolapse, which the PPH cannot always manage to correct properly (16).

The authors have come up with a technical modification to the mucoprolapsectomy, notably the Single Stapler Parachute Technique (SSPT), in order to obtain more abundant mucosal resection while fully exploiting the capacity of the stapler set. In this study, the authors will present the results obtained in 80 patients treated for muco-haemorrhoidal prolapse, 40 of whom underwent traditional PPH, while the remaining 40 patients underwent SSPT, both performed in two different specialised centres in Rome, Italy.

Patients and methods

Between October 2009 and December 2010, 80 patients were consecutively treated at two Surgical Units in Rome, Italy (Colon-Proctology Unit of “San Camillo-Forlanini” Hospital and the Department of Surgical Sciences “Umberto I” Hospital, “Sapienza” University) for symptomatic haemorrhoidal prolapse. Preoperative evaluation included medical history, physical examination, routine laboratory test and anaesthesiological evaluation. Patients with symptoms of ODS (Obstructed Defecation Syndrome) were not included in the study. Lower gastrointestinal endoscopy was performed to exclude other colorectal lesions for those patients with rectal bleeding that could not be solely attributed to haemorrhoids. Informed consent was obtained from the patients for stapled haemorrhoidectomy after full explanation of the procedure.

Patients were operated in lithotomy position. Metronidazole 500 mg was given intravenously at induction of anaesthesia. In addition to a standard sedation anaesthesia, we always performed a regional anaesthesia with blockage of the branches to the anus from the anococcygeal nerve, the pudendal nerve and the inferior haemorrhoidal nerves. All procedures were performed by two senior surgeons. Both Longo procedure and SSPT were performed with similar staplers (PPH01 or PPH03, Ethicon Endosurgery, Cincinnati, US; and Chex-CPH34, Frankenman International Limited, HongKong). Prolapse staging - i.e. length of the prolapse less or more than half the length of the Circular Anal Dilator (CAD) - was obtained at the beginning of the procedure by introducing the CAD included in the stapler set and removing the obturator.

Surgical techniques

Longo procedure

A purse-string suture was carried out, 4 to 5 cm above the dentate line, to make the suture line at the end of the procedure approximately 2 to 3 cm proximal to the dentate line. The head of the circular stapler was introduced proximal to the purse-string, which was tied with a closing knot. The ends of the suture are pulled through the lateral holes of the instrument.

Single Stapler Parachute Technique (SSPT)

Instead of a single purse-string suture, six separated stitches, at 3, 9, 1, 11, 5 and 7 hours or 12, 6, 2, 5, 7 and 10 hours, were placed proximal to the dentate line as for traditional Longo's procedure (Fig. 1). The single suture threads were secured to each other in two groups (Fig. 2) in order to allow them to be retrieved through the lateral suture conduits positioned on the right and left side of the circular stapler.

With both procedures the ends of the sutures should be fixed externally using a clamp and a gentle digital pressure on the sutures should be maintained while tightening the stapler to draw the mucosa and submucosa into the stapler “case” (Fig. 3). After the stapler had been fired, meticulous haemostasis was achieved by suturing of the bleeding points at the anastomotic line with absorbable material (Vicryl 3-0). Volume (in mL), weight (in g) and length (in cm) of the specimen were registered immediately after resection. Duration of the procedure, postoperative complications within 30 days

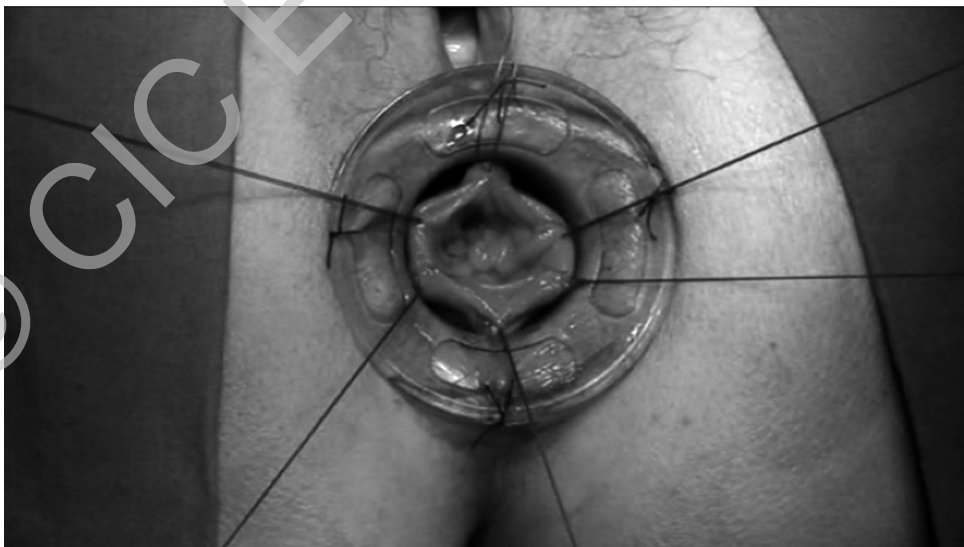

Fig. 1 - Single Stapler Parachute Technique (SSPT) for hemorrhoidal prolapse. Six separated stitches placed proximal to the dentate line.

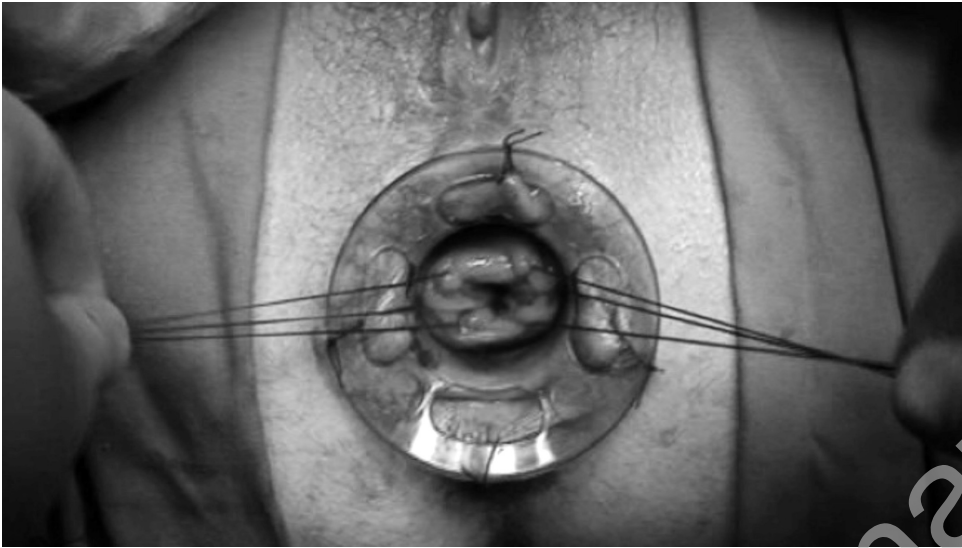


Fig. 2 - Single Stapler Parachute Technique (SSPT) for hemorrhoidal prolapse. Single suture threads secured to each other in two groups.



Fig. 3 - Single Stapler Parachute Technique (SSPT) for hemorrhoidal prolapse. Insertion of the stapler drawing mucosa and submucosa into the "case".

after surgery and short term functional results between 30 days and 3 months from surgery were registered.

Statistical analysis

In a first analytical step we checked the compatibility (in terms of sex, age and CAD staging) between the two groups of patients treated with the different surgical techniques (conventional Longo procedure and SSPT). To this purpose we evaluated the chi-square value (and its associated probability) for categorical variables, while we used the t-test statistics for the continuous ones. Going further in the analysis we studied the duration of the surgical procedures, in order to verify significant differences. We analyzed the volume, the weight and the length of the specimens immediately after the resection. Since higher values of these parameters could be associated to better outcomes, we evaluated their mean values and the associated p-value for their differences. We made this analysis by considering the different surgical procedures and these crossed by the different CAD staging.

Results

There were no differences between the two groups of patients (Longo procedure versus SSPT) in sex or grade of rectal prolapse (CAD staging), as reported in the Tables 1 and 2 (chi-square, respectively, 0.2 and 0.65, with associated p-value of 0.654 and 0.2). This implies that the two procedures are applied on two comparable groups; this is confirmed by considering the mean age of the patients (Table 3), in which the t-test is 1.16 with a p-value of 0.246.

For what concerns the mean duration of the surgical procedure, the SSPT results to be longer (26 minutes versus 29 minutes for Longo procedure) (Table 4). This difference has only slight statistical significance (t-

TABLE 1 - CLASSIFICATION OF PATIENTS BY SEX AND SURGICAL PROCEDURE (chi-square 0.2, associated p-value 0.654).

Sex	Longo procedure	SSPT	Total
Females, n	19	21	40
Males, n	21	19	40
Total	40	40	80

TABLE 2 - CLASSIFICATION OF PATIENTS BY CAD STAGING OF THE RECTAL PROLAPSE (chi-square 0.65, associated p-value 0.2).

CAD staging	Longo procedure	SSPT	Total
Less the half	18	16	34
More the half	22	24	46
Total	40	40	80

TABLE 3 - CLASSIFICATION OF PATIENTS BY AGE AND SURGICAL PROCEDURE (t-test between the two groups 1.16 with an associated probability of 0.246).

	Age, yrs mean \pm SD (range)
Longo procedure	49.9 \pm 12.4 (22-80)
SSPT	46.7 \pm 12.7 (21-69)

TABLE 4 - CLASSIFICATION OF PATIENTS BY DURATION OF THE SURGICAL PROCEDURE (t-test statistic between the two groups 1.72 with an associated probability of 0.08).

	Duration of the procedure, minutes mean \pm SD (range)
Longo procedure	26.2 \pm 8.14 (15-55)
SSPT	29.1 \pm 6.69 (20-55)

TABLE 5 - CLASSIFICATION OF PATIENTS BY MEAN VALUES OF VOLUME, WEIGHT AND LENGTH OF THE SPECIMENS AND SURGICAL PROCEDURE.

Specimen parameter	Surgical procedure	Mean \pm SD (range)	t-test, p-value
Volume, mL	Longo	6.86 \pm 1.49 (4-9)	14.99, < 0.05
	SSPT	11.83 \pm 1.47 (9-14)	
Weight, g	Longo	7.1 \pm 1.55 (5-10)	15.08, < 0.05
	SSPT	11.57 \pm 1.06 (9-14)	
Length, cm	Longo	2.61 \pm 0.63 (1.5-4.25)	8.4, < 0.05
	SSPT	4.18 \pm 0.99 (2-6)	

test 1.72, p-value 0.08, i.e. the probability is less the threshold of 0.1). The Authors think it depends on the fact that a purse-string suture may be faster to perform than placing six separate stitches as required in SSPT.

For what concerns the volume, the weight and the length of the specimens, it could be observed (Table 5) that these parameters are significantly different between two groups of patients: all the p-values associated to the t-test statistics between the mean values of the parameters are less the threshold of 0.05. Furthermore it can be observed that the single stapler parachute technique is associated with greater values of volume, weight and length of the specimens. This could be interpreted as a more efficient way to treat the disease. By introducing in the analysis also the information on the CAD staging (a factor that characterizes the patients before the surgical intervention), we observed that SSPT is always associated to a statistically significant increase of the weight and the volume of the specimens (Table 6).

Follow-up

As we started the present study in October 2009, the current average follow-up period amounts only to 1 year (range between 6 months and 20 months).

Results showed similar complications for both techniques. Major complications were not observed. Two out of 80 patients (2.5%) experienced an episode of proctorrhagia within 6 hours following surgery. One of the two patients had undergone Longo procedure, while the other had been treated with the single stapler parachute technique (Table 8). Both patients were taken back to the operating theatre where haemostatic sutures in Monocryl 3/0 were performed in order to stop the bleeding. Four out of 80 patients (5%), two of whom had undergone Longo mucoprolapsectomy and two mucoprolapsectomy with SSPT, experienced severe anal pain during the night following discharge (Table 7), successfully treated with ketorolac tromethamine IV in emergency room. All four patients were kept under observation for the remaining part of the night and were therefore discharged the following morning.

TABLE 6 - CLASSIFICATION OF PATIENTS BY MEAN VALUES OF VOLUME, WEIGHT AND LENGTH OF THE SPECIMENS, SURGICAL PROCEDURE AND CAD STAGING. Statistical test consider each combination of data against all the others (for example, "Longo and CAD staging less the half" against the remaining combinations).

Specimen parameter	Surgical procedure	CAD staging	Mean value	t-test, p-value
Volume, mL	Longo	Less the half	5.75	8.01, < 0.05
		More the half	7.77	3.16, < 0.05
	SSPT	Less the half	10.75	2.21, < 0.05
		More the half	12.56	9.39, < 0.05
Weight, g	Longo	Less the half	5.94	11.83, < 0.05
		More the half	8.04	4.53, < 0.05
	SSPT	Less the half	10.75	3.71, < 0.05
		More the half	12.12	11.67, < 0.05
Length, cm	Longo	Less the half	2.14	6.55, < 0.05
		More the half	3	1.94, 0.55
	SSPT	Less the half	3.78	1.51, 0.13
		More the half	4.44	6.70, < 0.05

TABLE 7 - SHORT-TERM COMPLICATIONS.

	Proctorrhagia, pts	Postoperative pain, pts
Longo procedure (n = 40)	1 (2,5%)	2 (5%)
SSPT, n (n = 40)	1 (2,5%)	2 (5%)
Total (n = 80)	2 (2,5%)	4 (5%)

One month following surgery, 9 out of the 40 patients (22.5%) treated with the Longo procedure presented residual prolapse. This occurrence was however asymptomatic in 7 out of 9 patients, and was observed only during anoscopy exam. Eight out of these nine patients were part of the patient subgroup with prolapse that occupied as much or more half of the length of CAD. One month

following surgery, only one out of the 40 patients (2.5%) treated with SSPT presented residual prolapse. This was observed, however, only during anoscopy exam, and was therefore asymptomatic. The patient was part of the patient subgroup with prolapse that occupied more half of the size of CAD (Table 8).

Discussion

The Longo procedure has rapidly gained acceptance due to the fact that it is practical, easy to perform and provide optimal results (17, 18). As far as cases with not particularly severe prolapse (i. e., the prolapse that in our classification do not occupies half of the length of CAD during the intraoperative assessment), the results are more satisfactory (19). However, in cases of more large prolapse (meaning those cases that are often clinically referred to as grades 3 and 4, which occupy as much as or more

TABLE 8 - RESIDUAL PROLAPSE.

Residual prolapse	Longo procedure (n = 40)		SSPT (n = 40)	
	Less the half (18 pts)	More the half (22 pts)	Less the half (16 pts)	More the half (24 pts)
Asymptomatic, n	1 (5,6%)	6 (27,3%)	0	1 (4,2%)
Symptomatic, n	0	2 (9,0%)	0	0
Subtotal	1 (5,6%)	8 (36,4%)	0	1 (4,2%)
Total	9 (22,5%)		1 (2,5%)	

half the length of the CAD) the PPH seems inappropriate as the mucosal resection may be insufficient. Therefore we believe that the traditional Longo procedure should be applied only to those cases in which the prolapse is assessed as occupying less than half the length of the CAD.

In cases of more large prolapse, it is often advisable to resort to the “double stapler technique” (Stapled Transanal Rectal Resection, STARR). This consists in transanal resection using circular staplers in order to widen the resection, which would otherwise be affected by the size of the stapler itself (20). However, this method may appear excessive in cases of prolapse which do not present rectocele, intussusception, or ODS (disease for which the STARR has been developed) (4). Moreover, the use of two staplers rather than one proves to be a more expensive procedure (21). Therefore, we have developed a technical modification to the mucoprolapsectomy, which allows the use of only one stapler. In fact, by fully exploiting the capacity of the stapler’s “case”, we have managed to obtain more appropriate resections.

We have therefore attempted to demonstrate that the mucoprolapsectomy with SSPT is easy to perform (especially for those surgeons who are skilled in Longo prolapsectomy), safe and easy to repeat. Only the duration of procedure seems to have slightly increased. In our case study the average duration of the traditional Longo procedure amounts to 26.2 minutes, against 29.1 minutes with SSPT. The new technique maintains all the advantages of the traditional method. We have observed similar complications between the two techniques. We have not experienced major complications, nor cases of anal stenosis or incontinence, neither temporary nor permanent.

Having taken all these considerations into account, it is therefore possible to increase the extension of the resection, both for prolapses that occupy more than half the length of the CAD (average length of resection with Longo technique is 3 cm, with the new parachute technique 4.44, with an average increase of 48%) as well as for prolapses that do not occupy as much as the length of the CAD (average length of resection with Longo 2.14 cm, with SSPT 3.78 cm, with an average increase of 76.6%). It is also possible to increase the specimen volume for more significant prolapses that occupy more than half the length of the CAD (average volume of resection with Longo procedure 7.77 mL, with SSPT 12.56 mL, with an average increase of 61.9%), and also for prolapses that do not occupy as much as the length of the CAD (average volume of resection with Longo procedure is 5.75 mL, with SSPT 10.57 mL, with an average increase of 87.0%). We could also increase the specimen weight both for prolapses that occupy more than half the length of the CAD (average weight of resection with Longo procedure 8.04 g, with SSPT 12.12 g, average increase 50.7%) and for prolapses that are inferior to half the length of the CAD (ave-

rage weight of resection with Longo procedure 5.94 g, with SSPT 10.75 g, average increase 81%).

Moreover, the single stapler parachute technique allows to perform more asymmetrical resection. Although this may initially appear as a limitation, it offers instead the possibility to obtain an asymmetrical resection in cases in which the prolapse itself is asymmetric (it is in fact very rare to find that the amount of prolapsed mucosa is “regular” at 360°). Therefore, this new method allows to resect only the prolapsed mucosa, without overtreatment. This is indeed possible thanks to the simple application of traction stitches rather than to perform a purse-string.

We have observed a more amount of resection, as well as an asymmetrical removal which has also proven to be more appropriate to the prolapse size. In our case study, these factors have also implied a significant reduction of residual prolapse, especially in the cases of more large prolapse which occupied more than half the length of the CAD. As for those patients who had undergone the Longo procedure we have recorded only one residual prolapse out of 18 procedures (5.6%) in the subgroup with prolapse inferior to half of the length of the CAD. We have instead observed 8 residual prolapses out of 22 procedures (36.4%), 2 of which were asymptomatic, in the subgroup with prolapse exceeding half of the length of the CAD. On the other hand, out of the 40 patients who were treated with SSPT, only 1 (2.5%) who belonged to the subgroup with prolapse occupying more than half the length of the CAD, experienced residual prolapse, which was however asymptomatic.

By the light of our data, we consider SSPT an optimal technical solution for those patients whose prolapse occupies more than half the length of the CAD or is particularly irregular or asymmetric. In fact, the traditional Longo procedure can expose these patients to an excessive risk of residue, while the STARR, outside its specific indications, may be an overtreatment. SSPT does not intend in any way to replace the traditional Longo procedure or STARR, if indicated. However, in selected cases, it seems to be a halfway solution in relation to the amount of removed mucosa.

Conclusion

SSPT allows to obtain a resection that is mainly mucosal, and is definitely at a higher position compared to traditional prolapsectomy. It also provides a surprising lifting effect and significant mucosal unclotting. A further, and not less relevant, feature of the technique is the adequacy and “asymmetry” of the mucosal resection. In fact, if the prolapse is asymmetrical, the new technique offers the possibility of a tailored resection, applying stitches where more necessary and calibrating the traction of threads.

References

1. Chen JS, You JF. Current status of surgical treatment for hemorrhoids - systematic review and meta-analysis. *Chang Gung Med J* 2010; 33 (5): 488-499.
2. Longo A. Treatment of hemorrhoid disease by reduction of mucosa and hemorrhoid prolapse with a circular-suturing device: a new procedure. Proceedings of the 6th World Congress of Endoscopic Surgery. Bologna, Monduzzi Editore, 1998: pp. 777-84.
3. Mongardini M, Pappalardo G. The use of Floseal in the prevention and treatment of intra- and post-operative hemorrhage in the surgical treatment of hemorrhoids and coloproctoceles. Preliminary results. *G Chir* 2003; 24 (10): 377-81.
4. Corman ML, Gravié JF, Hager T, Loudon MA, Mascagni D, Nyström PO, Seow-Choen F, Abcarian H, Marcello P, Weiss E, Longo A. Stapled haemorrhoidopexy: a consensus position paper by an international working party - indications, contra-indications and technique. *Colorectal Dis* 2003; 5: 304-10.
5. Law WL, Tung HM, Lee FCW, Chu KW. Ambulatory stapled haemorrhoidectomy: a safe and feasible surgical technique. *Hong Kong Med J* 2003; 9: 103-7.
6. Caviglia, A, Del Grammastro, R, Crocetta, A, Straniero, F, Giorgiano. Feasibility of stapled haemorrhoidopexy in Day Surgery. *Eur Rev Med Pharmacol Sci* 2009; 13: 295-298.
7. Mongardini M, Custureri F, Schillaci F, Cola A, Maturo A, Fanello G, Corelli S, Pappalardo G. Prevention of post-operative pain and haemorrhage in PPH (Procedure for Prolapse and Hemorrhoids) and STARR (Stapled Trans-Anal Rectal Resection). Preliminary results in 261 cases. *G Chir* 2005; 26 (4): 157-61.
8. Gabrielli F, Chiarelli M, Cioffi U, Guttaduro A, De Simone M, Di Mauro P, Arriciati A. Day surgery for mucosal-hemorrhoidal prolapse using a circular stapler and modified regional anesthesia. *Dis Colon Rectum* 2001; 44: 482-844.
9. Batori M, A. Straniero, Pipino R, Chatelou E, Sportelli G. Stapled hemorrhoidopexy in the treatment of hemorrhoid disease. Our eight-year experience. *Min Chir* 2010; 65: 21-5.
10. Giordano P, Gravante G. Long-term outcomes of stapled hemorrhoidopexy vs conventional hemorrhoidectomy. A meta-analysis of randomized controlled trials. *Arch Surg* 2009; 144 (3): 266-272.
11. Oughriess M, Yver R, Faucheron JL. Complications of stapled hemorrhoidectomy: a French multicentric study. *Gastroenterol Clin Biol* 2005; 29:429-33.
12. Jongen J, Bock JU, Peleikis HG, Eberstein A, Pfister K. Complications and reoperations in stapled anopexy: learning by doing. *Int J Colorectal Dis* 2006; 21: 166-71.
13. Sileri P, Stolfi VM, Franceschilli L, Perrone F, Patrizi L, Gaspari AL. Reinterventions for specific technique-related complications of stapled haemorrhoidopexy (SH): a critical appraisal. *J Gastrointest Surg* 2008; 12: 1866-72.
14. Pescatori M, Gagliardi G. Postoperative complications after procedure for prolapsed hemorrhoids (PPH) and stapled transanal rectal resection (STARR) procedures. *Tech Coloproctol* 2008; 12: 7-19.
15. Boccasanta P, Stuto A, Naldini G, Caviglia A, Carriero A. Opinions and facts on reinterventions after complicated or failed stapled hemorrhoidectomy. *Dis Colon Rectum* 2006; 49 (5): 690-1; author reply 691-3.
16. Acheson AG, Scholefield JH. Management of haemorrhoids. *BMJ* 2008; 336: 380-3.
17. Burch J, Epstein D, Baba-Akbari A, Weatherly H, Fox D, Golder S, Jayne D, Drummond M, Woolcott N. Stapled hemorrhoidectomy (haemorrhoidopexy) for the treatment of hemorrhoids: a systematic review and economic evaluation. *Health Technology Assessment* 2008; 12 (8): iii-iv, ix-x, 1-193.
18. Mongardini M, Custureri F, Schillaci F, Leone G, Cola A, Fanello G, Benedetti F, Maturo A, Pappalardo G. Rectal stenosis after stapler hemorrhoidopexy. *G Chir.* 2005; 26(6-7): 275-7.
19. Kanellos I, Zacharakis E, Kanellos D, Pramateftakis MG, Tsachalis T, Betsis D. Long-term results after stapled haemorrhoidopexy for third-degree hemorrhoids. *Tech Coloproctol* 2006; 10 (1): 47-9.
20. Naldini G, Martellucci J, Talento P, Caviglia A, Moraldi L, Rossi M. New approach to large haemorrhoidal prolapse: double stapled haemorrhoidopexy. *Int J Colorectal Dis* 2009; 24 (12): 1383-7.