

## Mucocele of the appendix. Two case reports

G. STURNIOLO<sup>1</sup>, M. BARBUSCIA<sup>2</sup>, F. TARANTO<sup>1</sup>, A. TONANTE<sup>1</sup>,  
D. PAPARO<sup>1</sup>, G. ROMEO<sup>1</sup>, D. NUCERA<sup>1</sup>, M. LENTINI<sup>3</sup>

**SUMMARY: Mucocele of the appendix. Two case reports.**

G. STURNIOLO, M. BARBUSCIA, F. TARANTO, A. TONANTE,  
D. PAPARO, G. ROMEO, D. NUCERA, M. LENTINI

*The authors present two cases of mucocele of the appendix and discuss them in relation to the literature and the clinical features of this disease.*

*They clarify the definition of mucocele as an intraluminal accumulation of mucus in the appendix, and concentrate on the observable pathological processes, agreeing on the higher frequency of mucinous cystadenoma and the possibility that mucocele can develop into peritoneal pseudomyxoma or degenerate into cystadenocarcinoma.*

*They also note that most diagnoses are made intra-operatively during appendectomy, and that, in cases suspected preoperatively, thorough investigation with imaging techniques is very important in order to plan the best treatment.*

**RIASSUNTO: Il mucocele appendicolare: descrizione di due casi operati.**

G. STURNIOLO, M. BARBUSCIA, F. TARANTO, A. TONANTE,  
D. PAPARO, G. ROMEO, D. NUCERA, M. LENTINI

*Gli Autori presentano due casi di mucocele appendicolare e prendono da essi lo spunto per rivedere la letteratura sull'argomento e discutere le caratteristiche cliniche di questa particolare affezione.*

*Dopo aver fatto qualche puntualizzazione sulla genericità della definizione di mucocele quale dilatazione dell'appendice per accumulo intraluminale di muco, si soffermano proprio sui processi patologici osservabili, concordando sulla maggiore frequenza del cistoadenoma mucinoso e sulla possibilità che il mucocele possa evolvere verso lo pseudomixoma peritonei o degenerare in cisto-adenocarcinoma.*

*Puntualizzano quindi come la maggior parte delle osservazioni venga fatta al tavolo operatorio in corso di appendicectomia e come, nei casi sospettati pre-operatoriamente, molto importante sia un accurato studio di imaging anche ai fini di un'adeguata programmazione terapeutica.*

**KEY WORDS:** Appendiceal mucocele - Appendicitis - Pseudomyxoma peritonei - Mucinous cystadenoma - Cystadenocarcinoma.  
Mucocele appendicolare - Appendicite - Pseudomixoma peritonei - Cistoadenoma mucinoso - Cistoadenocarcinoma.

## Introduction

Mucocele of the appendix involves the slow but progressive buildup of mucinous material inside the appendiceal lumen (1,2). This uncommon condition is generally asymptomatic and may be found completely by chance during ultrasound or CT procedures or, more frequently, during surgery. In most cases, it is completely

benign. However, in a small percentage of cases it can develop into a malignant neoplasm, cystadenocarcinoma. This disease may sometimes be associated with other neoplasms, especially of the right colon (3).

We decided therefore to review our caseload to verify the incidence and features of this disease.

## Case reports

Over the last 15 years we have observed two cases of mucocele of the appendix.

### Case 1

A 36-year-old man who had been suffering from quite intense abdominal pain in the right iliac fossa for at least 10 hours. This pain was associated with nausea and some retching. With no other medical history, the clinical signs and severe neutrophilic leukocytosis pointed to appendicitis. Surgical treatment was therefore decided.

University of Messina, Italy  
<sup>1</sup>Chair of General Surgery  
(Director: G. Sturniolo)  
<sup>2</sup>Chair of Digestive Surgery  
(Head: M. Barbuscia)  
<sup>3</sup>Chair of Anatomical Pathology  
(Director: G. Barresi)

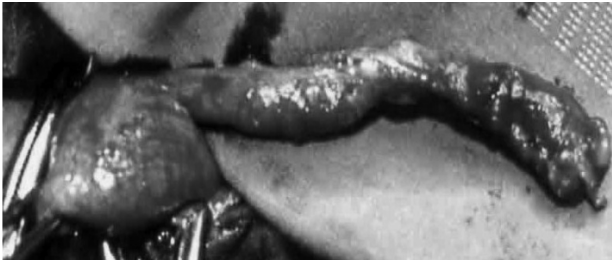

Fig. 1 - Moderately dilated appendix, with a small perforation about 2 cm from the tip.

On opening the abdomen (right pararectal laparotomy), a small quantity of serous fluid was aspirated and the appendix was found to be highly hyperemic and strongly adherent to the base of the cecum: it was removed. The appendix was about 12 cm long and dilated throughout, above all in two well-defined areas: a section of at least 3 cm starting from about 2 cm above the base of the cecum, and a section of 2 cm at the tip. In the latter, there was a small perforation from which mucus material emerged (Fig. 1). Histological examination revealed abundant mucus in the appendiceal lumen and focal hyperplasia of the intestinal crypts in the wall (Fig. 2).

#### Case 2

A 51-year-old post-menopausal woman who also presented clinical signs, symptoms and laboratory data strongly indicating appendicitis. Gynecological examination, including transvaginal ultrasound, excluded any genital disease and only found a small quantity of fluid in the pouch of Douglas. Here too, it was decided to proceed with surgery through a right pararectal laparotomy. On opening the abdomen, the base of the cecum was exposed and the appendix was found to be highly dilated throughout, especially in the end section. About 1.5 cm from the base there was a small (about 4 mm) laceration from which abundant mucus material emerged (Fig. 3). Histological examination confirmed the presence of extravasated mucus on the outer surface of the appendix wall, while dilation of the mucous glands was observed on the luminal side. Focal deposits of calcium salts could be seen in the wall (Fig. 4).

## Discussion

Mucocele was described for the first time by Rokitsky in 1842 and then by Fere in 1876. It is a cystic dilation of the appendix due to buildup of mucus consequent to the obstruction of the ostium. In most cases, this obstruction is secondary to inflammation. The obstruction inevitably leads to a buildup of mucin and thus the organ's dilation, associated with focal or diffuse mucosal hyperplasia. Neoplasms can also cause obstruction of the appendiceal lumen and a consequent buildup of mucin, resulting in the formation of a mucocele. The definition of mucocele should thus be considered generic, as it includes a multitude of both benign and malignant conditions (4-6). The former include cystadenoma, the most common lesion (52% of cases), followed by mucus hyperplasia (20%) and mucus retention cysts (18%). In any of these cases, especially cystadenoma, the smallest perforation can cause the perivisceral leakage of mucous material, while a larger laceration can cause mu-

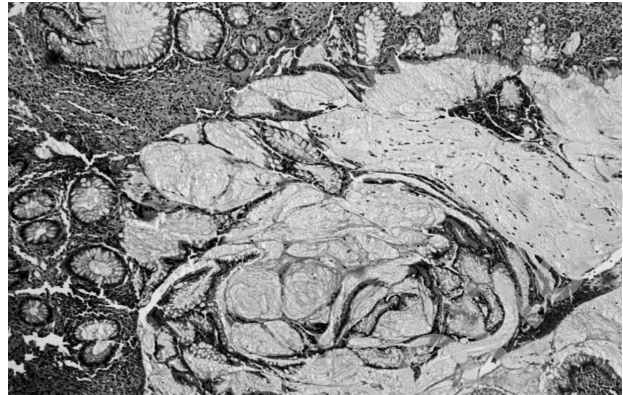


Fig. 2 - Abundant mucus collection in the appendiceal lumen. Focal hyperplasia can be seen in the intestinal crypts.

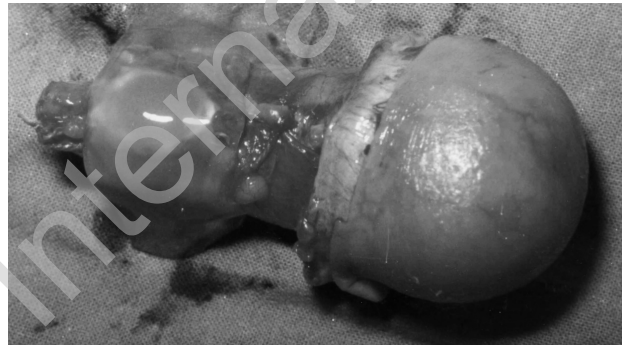

Fig. 3 - Highly dilated appendix, lacerated near the base, with leakage of abundant mucous material.

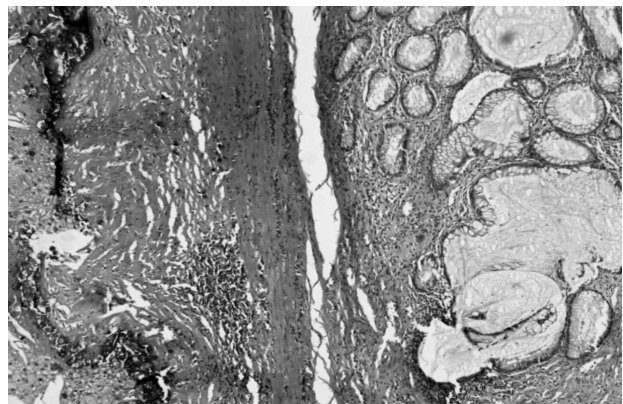


Fig. 4 - Extravasated mucus can be seen on the outer surface of the appendix wall with focal deposits of calcium salts. Dilation of the mucous glands can be seen on the luminal side.

cus to accumulate in the peritoneal cavity. Malignant formations account for about 10% of cases and are almost exclusively cystadenocarcinomas, consisting of small cell aggregates situated near the serosa. In advanced stages, they too can cause perforation of the appendix, subsequently developing into pseudomyxoma peritonei.

It should also be remembered that there are literature

reports of mucoceles associated synchronous, or more commonly metachronous, with other malignant tumors in the colon (0-21%) or ovary (4-24%), as well as other organs (gallbladder, thyroid, breast) (7).

Mucoceles are rarely observed, being seen in only 0.2-0.3% of all appendectomies reported in the various caseloads. Only Collins, in 1963, reported a significantly higher percentage (1.35%), in a very large caseload (8). They are mainly found in females (4:1), and generally in adults (especially in their forties).

As in our cases, mucocele is almost always an incidental finding during surgery for an inflammatory disease of the appendix. Although it is often associated with a complete absence of symptoms, it can cause non-specific abdominal pain in the right iliac fossa (which can however have the characteristics of intermittent pain in cases in which the mucocele tends to invagination) sometimes accompanied, as in numerous cases of appendicitis, by urinary symptoms and/or signs of sepsis (9,10). A palpable mass in the right iliac fossa is a relatively frequent finding, whereas mucocele as a possible cause of gastrointestinal bleeding is much less common. In addition to the aforementioned invagination of the appendix within the cecum and consequent intestinal occlusion, other possible complications include torsion of the appendix with gangrene and rupture of the mucocele (11,12). This relatively common condition is due to the anatomy of the appendix: an extremely thin serosal and subserosal layer, a delicate submucosa, vascularised by an end artery leaving no possibility of collateral circulation, and very thin longitudinal and circular muscle layers. Diagnostic suspicion is possible only in the case of a giant mucocele that can determine displacement of the intestinal loops on plain abdominal X-ray.

In the diagnosis of mucocele, ultrasound examination is in any case the primary technique, as it can reveal a well encapsulated cystic mass adhering to the cecum, with posterior enhancement, containing fluid of variable density (13,14). Following a barium enema, the presence of circular folds at the base of the cecum and a filling defect of the appendiceal lumen suggests an appendiceal mucocele (15).

Endoscopic examination does not seem to be of importance for diagnosis as it cannot be carried out in urgent cases, in which category most of these patients fall. However, it should be remembered that this procedure can provide pathognomonic evidence of mucocele: the so-called volcano sign, described by Hamilton and Stromont in 1989 (16) and consisting of the observation of a well-defined, smooth, soft, erythematous mass with a central crater from which mucin emerges. This mass surrounds the appendix opening and is covered with normal mucosa. It is a chance finding during endoscopic investigations carried out for screening purposes or diagnosis of another disease of the large intestine.

CT is the current gold standard for the diagnosis of mucocele, which is described as a cystic, roundish or tubular neoplasm against the wall of the cecum, with punctate or curvilinear parietal calcifications and variable opacity (17, 18). The walls may be enhanced after intravenous injection of contrast agent, whereas the contents have the same opacity in both plain and contrast-enhanced scans. The presence of ascites or a low-density mass compressing the intestinal loops without infiltrating them is suggestive of *pseudomyxoma peritonei*. CT can also reveal any perivisceral fluid or signs of perforation with mucus leakage and enables differential diagnosis against other diseases, whether more common, such as ovarian cysts, or less common, such as mesenteric cysts, intestinal duplication and hydrosalpinx. Above all, however, it enables a sufficiently certain differentiation between mucinous cystadenoma of the appendix and cystadenocarcinoma, demonstrating in the latter case the neoplastic invasion of the appendix wall and any distant peritoneal implants.

As with other diseases, laparoscopy is ever more valuable not only for diagnosis of mucocele but also, unless there is a risk of perforation or intraoperative rupture, for therapeutic purposes (19,20).

Appendiceal mucocele is generally treated by surgery (21,22). Access is decided on the basis of the clinical picture, initial diagnosis and, above all, the likelihood of perforation. With a probable diagnosis of benign mucocele, a simple appendectomy with complete removal of the mesentery is the procedure of choice, taking care to avoid dispersal of mucus in the peritoneal cavity. With malignant mucocele, the surgical procedure depends on the size of the tumor and above all on whether there is any extraparietal infiltration. Therefore:

- for all tumors < 1 cm (70-80% of cases), simple appendectomy with removal of the mesentery may be sufficient;
- in patients with tumors between 1 and 2 cm, as the risk of metastasis is quite unlikely (0-11%), simple appendectomy may also be sufficient; however if there is a suspicion of neoplastic infiltration or, in any case, with tumors located at the base of the appendix with positive margins, tumors involving the cecum or any cases where endoscopic biopsy has revealed a high degree of malignancy and high proliferation indices, a right hemicolectomy should be carried out;
- in tumors > 2 cm, the required treatment remains resection of the terminal ileum with right hemicolectomy;
- the usefulness of intraoperative hyperthermic chemotherapy is still debated, and this should in any case be used only in the presence of *pseudomyxoma peritonei*; in this case, careful revision of the entire abdominal cavity should be performed, if possible removing all mucinous implants.

## Conclusions

Mucocele is often a completely incidental finding during an appendectomy, as in the cases reported herein, or even a solely histological finding. It should however be reiterated that however encountered, the presence of an intra-abdominal cystic mass situated close to the cecal wall should raise the suspicion of this condition and indicate a more in-depth look at the situation. This should involve above all abdominal CT and endoscopic investigation of the large intestine:

- the first to establish the features of the mass and any signs of association with *pseudomyxoma peritonei* or possible malignant degeneration;

- the second to look for any concomitant colon tumor, undoubtedly the most common of the synchronous cancers found in patients with appendiceal mucocele.

Thorough investigation is the only way to establish a suitable surgical approach that takes account of the fragility of the appendix wall and the complications that could be caused by the ever-possible dispersal of mucus in the peritoneal cavity.

Finally, it should be stressed that an equally thorough evaluation should be carried out in all patients in which a mucocele was found by chance and in any case all patients undergoing surgery, following them up in order to catch any metachronous neoplastic growths in time.

## References

1. Rodríguez Alonso A, Suárez Pascual G, Bonelli Martín C, González Blanco A, Lorenzo Franco J, Cuerpo Pérez MÁ, Nogueira Carballo C, Álvarez Fernández Jc, Nieto García J. Masa quística retroperitoneal gigante: mucocele apendicular. *Actas Urol Esp* 2004;28(4): 327-31.
2. De Rezende Pereira JC, Trugilho JC, Sarmat AA. Mucocele of the appendix. *Surgery* 2004; 136(5):1096-7 .
3. Kunin N, Musolino A, Skufca J, Cisero N. Appendiceal mucocele. *J Chir* 2003;140(1):46-7.
4. Soueï-Mhiri M, Tlili-Graies K, Ben Cherifa L, Derbel F, Hmissa S, Dahmen Y, Jeddi M. Mucocele of the appendix. Retrospective study of 10 cases. *J Radiol* 2001;82(4):463-8.
5. Minni F, Petrella M, Morganti A, Santini D, Marrano D. Giant mucocele of the appendix. Report of a case. *Dis Colon Rectum* 2001;44(7):1034-6.
6. Haritopoulos KN, Brown DC, Lewis P, Mansour F, Eltayar AR, Labruzzo C, Hakim NS. Appendiceal mucocele: a case report and review of the literature. *Int Surg* 2001;86(4):259-62.
7. Higa E, Rosai J, Pizzimbono CA, Wise L. Mucosal hyperplasia, mucinous cystadenoma and mucinous cystadenocarcinoma of the appendix. A re-evaluation of appendiceal "mucocele". *Cancer* 1973;32(6):1525-41.
8. Collins DC. 71,000 human appendix specimens. A final report, summarizing forty years' study. *Am J Proctol* 1963;14:265-81.
9. De Pablo Cárdenas A, Lozano Uruñuela F, Pinós Paul Ma, Jiménez Aristu Ji, Jiménez Calvo Jm, Ruiz Ramo M, Guarch Troyas R, Santiago González de Garibay AM, Sebastián Borrueal JL. Extrinsic ureteral obstruction secondary to appendiceal mucocele. *Arch Esp Urol* 2001;54(5):451-4.
10. Pereira Arias JG, Ibarluzea González JG, Gutiérrez Díez JM, Muñeta-Goyena Mendizábal J, Álvarez Martínez JA. Lesión quística retrovesical inusual: mucocele apendicular. *Arch Esp Urol* 2002;55(5):560-4 .
11. Parada R, Rosales A, Algaba F, Lluís F, Villavicencio H. Mucocele of the appendix: an unusual cause of obstructive kidney failure. *Br J Urol* 1998;82(3):444-5 .
12. Sato H, Fujisaki M, Takahashi T, Maruta M, Maeda K, Kuroda M. Mucinous cystadenoma in the appendix in a patient with non rotation: report of a case. *Surg Today* 2001;31(11):1012-5.
13. Caspi B, Cassif E, Auslender R, Herman A, Hagay Z, Appelman Z. The onion skin sign: a specific sonographic marker of appendiceal mucocele. *J Ultrasound Med* 2004;23(1):117-21.
14. Sasaki K, Ishida H, Komatsuda T, Suzuki T, Konno K, Ohtaka M, Sato M, Ishida J, Sakai T, Watanabe S. Appendiceal mucocele: sonographic findings. *Abdom Imaging* 2003;28(1):15-8.
15. Watanabe T, Yoshikawa I, Kihara Y, Kume K, Otsuki M. Appendiceal mucocele. *Gastrointest Endosc* 2003;58(6):909-10.
16. Hamilton DR, Stormont JM. The volcano sign of appendiceal mucocele. *Gastrointest Endosc* 1989;35(5):453-6.
17. Kalu E, Croucher C. Appendiceal mucocele: a rare differential diagnosis of a cystic right adnexal mass. *Arch Gynecol Obstet* 2005;271(1):86-8.
18. Zissin R, Gayer G, Kots E, Apter S, Peri M, Shapiro-Feinberg M. Imaging of mucocele of the appendix with emphasis on the CT findings: a report of 10 cases. *Clin Radiol* 1999;54(12):826-32.
19. González Moreno S, Shmookler RM, Sugarbaker PH. Appendiceal mucocele. Contraindication to laparoscopic appendectomy. *Surg Endosc* 1998;12(9):1177-9.
20. Lau H, Yuen WK, Loong F, Lee F. Laparoscopic resection of an appendiceal mucocele. *Surg Laparoscopic Endosc Percutan Tech* 2002;12(5):367-70.
21. Wallis JW, Madan A, Shoemaker MC. Giant mucocele of the appendix. *AJR Am J Roentgenol* 1995;165(4):1013-4.
22. Stocchi L, Wolff BG, Larson DR, Harrington JR. Surgical treatment of the appendiceal mucocele. *Arch Surg* 2003;138(6):585-9.