

Surgical significance of Fredet's area

F. RUOTOLO

During ontogenetic development, the capacity of the peritoneum to grow and evolve conditions the final organization of each area of the abdomen, leading to the definitive arrangement of every organ through an extensive, active fusion process regulated by Toldt's law of fusion ("the peritoneum of the mesentery and organs in fixed contact with other serous parietal, mesenteric or organ surfaces fuse together") (1). This fusion, also promoted by the reciprocal pressure of the contiguous organs, generates fasciae that delimit the cleavage planes. The latter lack vessels and nerves and are interposed with structures, organs and viscera that are completely independent.

The fusion process also involves the anterior face of the pancreas. At the point of entry into the root of the transverse mesocolon the head of the pancreas has a supra- and submesocolic part. The root of the transverse mesocolon slopes from right to left and from bottom to top. It thus leaves on an upper plane a large part of D_2 , and the upper two thirds of the head and body-tail of the pancreas, while the distal D_2 end, the third and fourth duodenal portion with the duodenal-jejunal junction and the lower third of the head of the pancreas with the uncinata process remain under the point of entry.

The transverse mesocolon covers the duodenum, pancreas and superior mesenteric vascular peduncle. Below the root of the mesocolon, the fusion of the primary preduodenopancreatic peritoneum (*anterior mesoduodenum*) with the lower leaflet of the right transverse mesocolon generates the *submesocolic preduodenopancreatic fascia* or *Fredet's area*. This extends from the hepatic flexure to the secondary root of the mesentery and thus to the subisthmic preduodenal emergence of the vascular peduncle (2). [Pierre Fredet (1870-1946) - Dernier Président de la Société Nationale (1935) et premier Président de l'Académie de Chirurgie (1936)].

To the right of the median sagittal plane of the body, the omental bursa alongside the supramesocolic plane disappears due to the fusion of the four omental leaflets. In this area the full thickness of the omentum adheres to the upper two thirds of the anterior face of the head of the pancreas, the anterior face of the second portion of the duodenum above the mesocolon and the upper surface of the transverse mesocolon, thus generating the *supramesocolic preduodenopancreatic omental fascia* (3). This fascia, which belongs to the anterior primitive intestine (*mesogastrium*), is equivalent to the submesocolic preduodenopancreatic fascia, belonging to the middle primitive intestine (*mesenterium commune*). Laterally to the duodenum, these fasciae merge into *Treitz's fascia*, originating from the fusion of the *posterior mesoduodenum* with the posterior parietal peritoneum, which further down becomes the right *Toldt's fascia* (4) (Fig. 1).

Toldt's embryogenetic theory considers these fasciae to be the result of the fusion processes of leaflets from the primitive parietal peritoneum and the duodenal and colon mesenteries. This interpretation is supported by Treitz and Fredet, then the fascia and area named after them can be considered the continuation of the right Toldt's fascia along respectively the posterior and submesocolic anterior faces of the pancreatic duodenal block. Thus, ontologically, it would not be inappropriate to attribute Fredet's area to Toldt also. However, keeping a more precise name allows a more exact topographic definition (5).

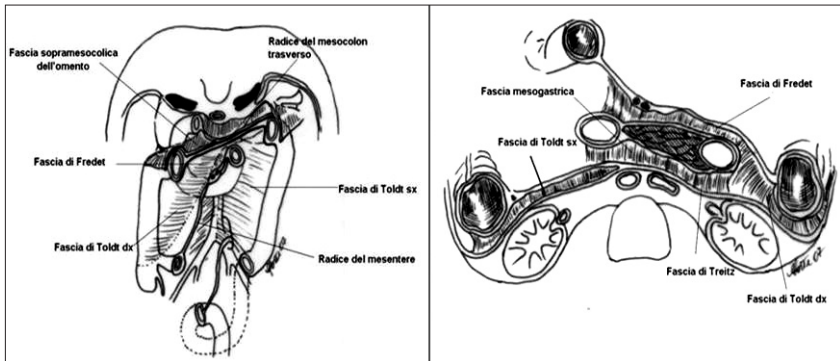


Fig. 1 - Fusion fascia: frontal and transversal sections.

Legend: Fascia sopramesocolica dell'omento = Supramesocolic omental fascia; Radice del mesocolon trasverso = Root of the transverse mesocolon; Fascia di Fredet = Fredet's area; Fascia di Toldt sx = Left Toldt's fascia; Fascia di Toldt dx = Right Toldt's fascia; Radice del mesentere = Root of the mesentery; Fascia mesogastrica = Mesogastric fascia; Fascia di Treitz = Treitz's fascia.

Like Toldt's and Treitz's fasciae, Fredet's area derives from the fusion of primitive peritoneum leaflets. However, its particular characteristics derive not from its ontogenesis, but its arrangement. In fact, the cleavage plane between right Toldt's fascia and Gerota's fascia, like that between Treitz's fascia and Gerota's fascia, provides a distinct separation between structures with different functions (colon and duodenopancreatic block in front and the retroperitoneal plane behind). In contrast, Fredet's area, which derives from the fusion of the preduodenal peritoneum and the inferior leaflet of the transverse mesocolon, forms part of both formations and thus has no true cleavage plane.

This makes its dissection more problematic: *"the anatomy of the region is one of the most challenging aspects for the fusion between the greater omentum, the anterior mesoduodenum and the transverse mesocolon"* (6) but enables the submesocolic anterior face of the head of the pancreas, the subpapillar second duodenal portion and the third and fourth duodenal portions to be exposed (Fig. 2).

This procedure, which forms one of the stages of the Cattell-Braasch maneuver, is carried out during exeresis of the duodenum, the head of the pancreas and the right colon, in submesocolic access to Vater's papilla, in the dissection of lymph nodes at the root of the mesentery along the superior mesenteric vein (SMV) and superior mesenteric artery (SMA) (groups 14v and 14a) and of satellite lymph nodes of the middle colic vessels (group 15), in preduodenal submesocolic access to the SMA and when creating an anastomosis between the SMV (Paitre and Giraud's surgical segment) and the inferior vena cava (IVC) (7,8). Dissection in the preduodenopancreatic area must be carried out with extreme caution so as not to damage *the complex anatomy of the vulnerable venous tributaries of the superior mesenteric vein* (Henle's gastrocolic trunk, which originates from the variable fusion of the right gastroepiploic vein, anterior-inferior pancreaticoduodenal vein, middle colic vein and right superior colic vein, and whose outlet is the right edge of the SMV at the lower margin of the pancreas). In around 10% of cases, an aberrant right hepatic artery originating from

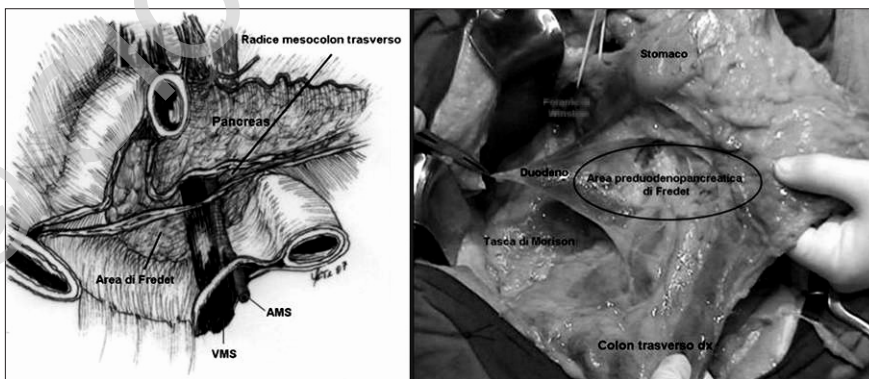


Fig. 2 - Fredet's preduodenopancreatic submesocolic area.

Legend: Radice mesocolon trasverso = Root of the transverse mesocolon; Pancreas = Pancreas; Area di Fredet = Fredet's area; AMS = Superior Mesenteric Artery (SMA); VMS = Superior Mesenteric Vein (SMV); Stomaco = Stomach; Forame di Winslow = Winslow's foramen; Duodeno = Duodenum; Area preduodenopancreatica di Fredet = Fredet's preduodenopancreatic area; Tasca di Morrison = Hepatorenal space (Morrison's pouch); Colon trasverso dx = Right transverse colon.

Surgical significance of Fredet's area

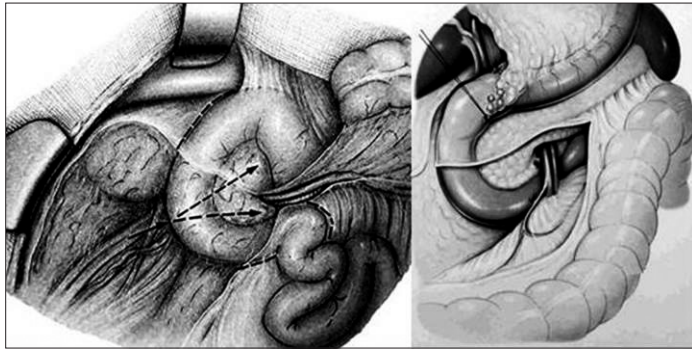


Fig. 3 - Lateromedial and craniocaudal access to Fredet's area (from Valdoni, ref. 9).

the SMA runs briefly through this area (which is covered by Fredet's area) on the right of the mesenteric root, before heading towards the liver, passing behind the head of the pancreas (retroportal lamina) and through Wiart's hepatocholedochal triangle and then Calot's triangle.

Three different approaches to the submesocolic preduodenopancreatic area are possible: lateromedial and craniocaudal supramesocolic, mediolateral and caudocranial submesocolic, or lateromedial and caudocranial submesocolic. In the first, the cecum and ascending colon must be detached along the right paracolic gutter and then from the cleavage plane between Toldt's and Gerota's fasciae. Next, the hepatic flexure must be freed completely, sectioning the serous folds (ligaments) attached to it. The right part of the root of the transverse mesocolon is then detached and the right mesocolon is separated down to the superior mesenteric peduncle (*subisthmic access to the mesenteric-portal axis*), dissecting Fredet's area between the end of the pancreatic capsule and the part fused to the transverse mesocolon. By extending the dissection to the plane of the supramesocolic omental fascia in which are located the satellite subpyloric lymph nodes of the right gastroepiploic vessels (station no. 6), the anterior face of the head of the pancreas and the second duodenal portion are completely exposed (Fig. 3) (9).

In the second approach (laparoscopic right hemicolectomy), after full-thickness opening of the right mesocolon and primary sectioning of the colic vessels close to the right margin of the superior mesenteric axis (*vascular stage*), Fredet's area is accessed by lifting the mesocolon and freeing

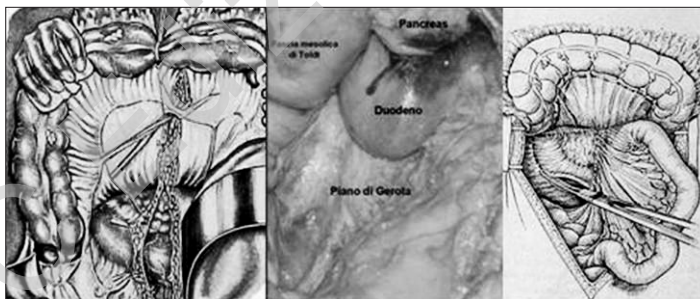


Fig. 4 - Mediolateral and caudocranial submesocolic access to Fredet's area (from Leger, ref. 10).

Legend: Pancreas = Pancreas; Fascia mesocolica di Toldt = Toldt's mesocolic fascia; Duodeno = Duodenum; Piano di Gerota = Gerota's fascia.

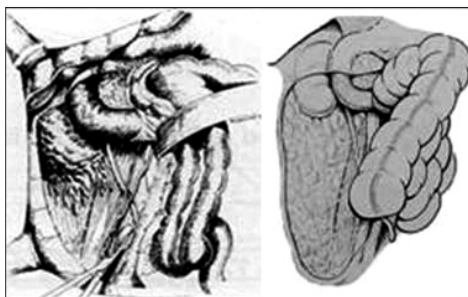


Fig. 5 - Lateromedial and caudocranial submesocolic access to Fredet's area (from Cattell, ref. 7).

Toldt's posterior mesocolic fascia from Gerota's fascia, which covers the retroperitoneal plane. The duodenal window thus created is enlarged laterally and proximally within Grégoire's triangle (between the trunk of the SMA and the middle colic or superior right colic artery), so exposing the submesocolic anterior face of the duodenopancreatic block (Fig. 4) (8).

The third approach, proposed by Cattell for submesocolic access to Vater's papilla in repeat bile duct surgery, involves the freeing of the cecum and ascending colon along the paracolic gutter and then in the cleavage plane between Toldt's and Gerota's fasciae (Fig. 5) (7).

In conclusion, the topographic position of Fredet's area makes it an undoubtful useful location when carrying out anatomic surgery.

References

1. Toldt C. Darmgekröse und Netze im gesetzmässigen und gesetzwidrigen Zustand. Wien, 1889.
2. Fredet P. Le péritoine in *Traité d'Anatomie humaine de Poirier et Charpy*. T. 4, 3 fasc. Paris Masson Ed., 1905.
3. Gullino D. *Chirurgia del peritoneo e del sottoperitoneo*. Trattato di Tecnica Chirurgica, vol. VIII, UTET, Torino, 1988.
4. Treitz W. Ueber einen neuen Muskel am Duodenum des Menschen, uber elastische Sehnen und einige andere anatomische Verhältnisse. *Prager Vierteljahrschrift*, XXXVII, Prague, 113-144, 1853.
5. Testut L, Jacob O. *Trattato di Anatomia Topografica*. Vol. II, UTET, Torino, 1922.
6. Skandalakis E. *Surgical Anatomy. The Embryologic and Anatomic Basis of Modern Surgery*. Vol. II, PMP, 2004.
7. Cattell RB, Braasch JW. A technique for the exposure of the third and fourth portions of the duodenum. *Surg Gyn Obst* 1960;111:379.
8. Corcione F, Miranda L, Ruotolo F. *Chirurgia laparoscopica. Dall'anatomia alla tecnica chirurgica standardizzata*. Idelson-Gnocchi, Napoli, 2008.
9. Valdoni. *Chirurgia addominale. Tecniche operatorie*. Vallardi Ed, Milano 1974.
10. Leger L. *Chirurgie du pancreas*. Nouveau *Traité de Technique Chirurgicale*. Vol. XII, Masson Ed., Paris, 1975.

I invited Professor Francesco Ruotolo to write the present original editorial article considering his excellent knowledge on surgical anatomy, and the importance which those topics can have for surgeons.

Giorgio Di Matteo
Editor-in-Chief