

Clinical review of patients subjected to mini-Mumford arthroscopy

Carlo Biz¹,
Giovanni Battista Vinanti²,
Marco Zamperetti¹,
Alberto Rossato²,
Roberto Aldegheri¹

¹ Orthopaedic Clinic, Padua University, Italy

² "Sant Rocco" Clinic, Ome, Brescia, Italy

Corresponding author:

Carlo Biz

Orthopaedic Clinic, Padua University

via Giustiniani 2, 35128 Italy

e-mail: carlo.biz@unipd.it

Summary

Purpose: assessment of the clinical efficacy of isolated arthroscopic mini-Mumford surgery, associated with shoulder surgery in patients with degenerative disease of the acromioclavicular joint. **Materials and methods:** 52 patients (group A) underwent isolated arthroscopic mini-Mumford and 84 (group B) additional arthroscopic surgery of rotator cuff and/or long head of biceps. They were evaluated clinically using Visual Analogue Scale (VAS), Simple Shoulder Test (SST) and Modified UCLA shoulder rating, pre- and post-operatively after a mean period of 18.1 months. **Results:** the results obtained in groups A and B overlap. **Discussion:** arthroscopic mini-Mumford is a simple, low-risk procedure, which has proved effective in treating degenerative disease of the acromioclavicular joint, both in isolation and in association with reconstruction of the rotator cuff and/or biceps long head tenotomy.

Key words: arthroscopic mini-Mumford, degenerative acromioclavicular joint pathology, long head biceps, rotator cuff.

Introduction

The degenerative disease of the acromioclavicular joint (AC) is one of the most common causes of shoulder pain. The etiology is relatively varied and a thorough history associated with careful clinical examination should lead to the possible cause^{1,2}. The clinical manifestation occurs mostly in nonspecific way, this complicates the diagnosis for a less skilled operator resulting in an underestimation of the prevalence of the disease^{2,3}. In an analysis of 1000 patients with shoulder pain, acromioclavicular joint abnormalities were found on standard radiographs with a prevalence of 12.7%⁴. We must also consider that AC disease is frequently associ-

ated with other diseases of the shoulder, such as lesions of the rotator cuff or subacromial impingement, thus complicating the clinical picture⁵. Cuomo et al.⁶ compared groups of age-matched shoulders [a group with rotator cuff tear (RCT) versus a non-RCT group] and revealed a much larger number (60% of cases) of inferiorly directed osteophytes on AC joint in the RCT group.

Imaging can be of considerable diagnostic utility and MRI is the most comprehensive examination; however, considering that the degenerative process at the AC joint starts in the second decade of life and it is very common to find patients with clear osteoarthritis of AC⁷, a positive MRI must be associated with clinical symptoms: indeed, such damage is clinically silent in most cases⁸. It's clear that in order to establish a correct diagnosis and therapeutic approach, it is crucial to correlate the instrumental context with the clinical context. Treatment should initially be non-operative, when there is no other damage, such as a lesion of the rotator cuff, combining a rehabilitative approach with localized physical therapy and possibly local steroid infiltration². In a second phase arthroscopic surgery may be indicated, performing a mini-Mumford⁹.

In this study we aimed to clinically analyze, over the medium-term, patients undergoing an arthroscopic mini-Mumford, either in isolation or associated with other surgical procedures in the shoulder^{10,11}.

Materials and methods

From June 2002 to December 2008, 175 patients, with degenerative disease of the acromioclavicular joint underwent an arthroscopic mini-Mumford. 136 of these patients, 79 females and 57 males with a mean age of 55 years, were clinically evaluated pre- and post-operatively. We also wanted to see if associated arthroscopic treatment at rotator cuff and/or biceps long head would affect the outcome.

Therefore, we divided the 136 patients examined in two groups:

Group A: included 52 patients, 31 females and 21 males with a mean age of 46 years who underwent an isolated arthroscopic mini-Mumford;

Group B: included 84 patients, 48 females and 36 males with a mean age of 63 years, who also underwent an associated treatment.

Inclusion criteria

Patients were included in this study only if they met the following criteria:

- Failure of 6 months of non-surgical treatment;
- Clinical picture characterized by pain radiating from AC to the base of the neck, a local tenderness on palpation and a positive test in hyperadduction;
- Imaging examination (MRI) which was positive for AC arthritis.

Exclusion criteria

Patients were excluded in this study if they presented:

- Previous shoulder fractures;
- Systemic diseases such as cancer or rheumatoid arthritis;
- Subject with cognitive limitation.

The clinical analysis was performed pre-operatively (time 0) and post-operatively after a mean period of 18.1 months (time 1). Subjective evaluation boards were used, such as the VAS and the Simple Shoulder Test (SST) and objective evaluation boards such as the UCLA (modified according to Burkhart) (Tab. 1).

Surgical Procedure

Clavicle resection was performed arthroscopically using an indirect approach, with anterior dedicated access centered on the joint and back portal arthroscope^{12, 13}.

The first step of this technique involves the accurate removal of the bursal and lower capsular tissue by a motorized tool and/or by radiofrequency. In this way we obtain an adequate skeletonization of the acromial and clavicular bony structures, while the second step involves the partial minimal removal of the acromial bone surface, in order to render the clavicular one more visible (Fig.1). At this point, using a spinal needle, the anterior portal can be identified and this guarantees proper access to the articulation (Fig.2). Using radiofrequency (Fig.3) and a motorized shaver we proceed to the removal of peri- and intra-articular soft tissue, exposing the subchondral portion of the clavicle and acromion: in this step it is crucial to keep the capsule and superior AC ligaments intact^{14,15}. Finally, the third step involves the

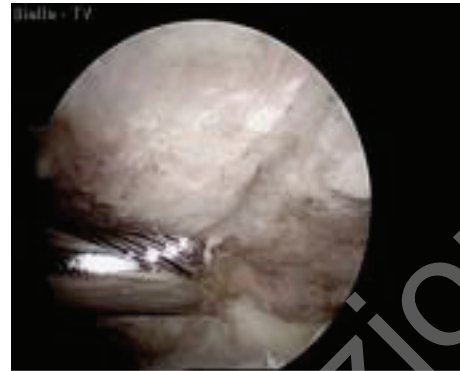

Figure 1. The initial reduction of the side door of the acromial portion of the AC joint, in order to allow a better view of the joint.

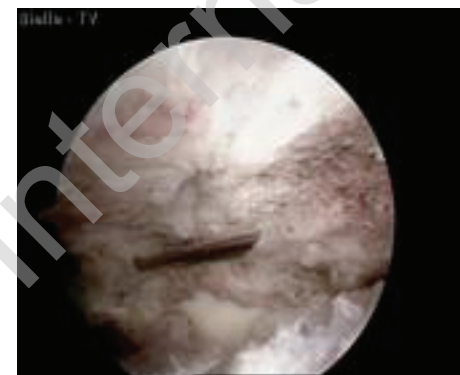


Figure 2. Identification of the correct parallelism and height of the anterior portal with the joint space, using a spinal needle.

	Worst score	Best score	Features	Rest
VAS	10	0	Subjective self-completion evaluation of pain	
SST	0	12	Subjective self-completion clinical and functional evaluation with 12 closed questions; every affirmative answer corresponds to a point	
UCLA	0	35	Objective clinical and functional evaluation; it examines pain, functionality, active forward flexion, external rotation isometric strength and patient satisfaction	Results: 0-20: poor 21-27: modest 28-33: good 34-35: excellent

Table 1. Evaluation boards used in this study, scores and main features.

removal of the clavicular bone surface, creating a gap of 5 mm between clavicle and acromion, which can guarantee the absence of conflict¹⁶ (Fig. 4).

Results

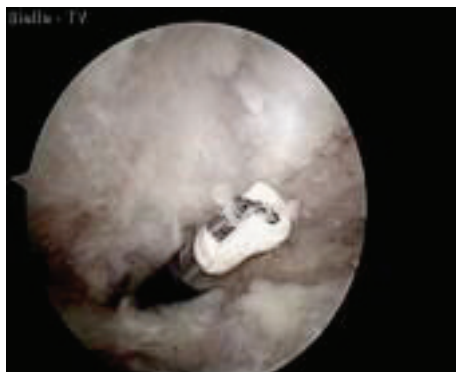


Figure 3. Skeletonization of the articular surfaces by a radiofrequency instrument.

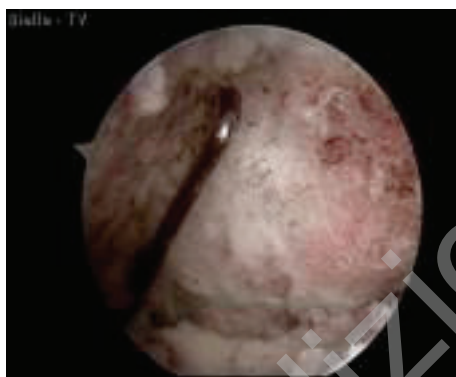


Figure 4. Checking the adequate bone resection using a stylus; it is essential to have completely removed clavicular bone up to its cranial and posterior margins.

The subjective evaluation of pain by the VAS showed a significant improvement going from a pre-operative average value of 7.5 (out of 10) to a post-operative average of 0.9 (out of 10). The subjective assessment of functionality with the SST confirmed the positive results, going from a pre-operative average score of 4 (out of 12) to a post-operative score of 11.1 (of 12). Finally, the objective clinical-functional assessment using the UCLA evaluation board resulted in a pre-operative average score of 12.1 (out of 35) and post-operative of 32.7 (out of 35). In detail, 3 patients had a poor result, 5 moderate, 47 good and 81 excellent (Tab. 2). Patients in group A obtained the results shown in Table 3. Patients in group B obtained the results reported in Table 4. There were no complications at intra- peri- and post-operative stages. In particular, there were neither infections, nor evidence of instability of the clavicle^{3,10,17,18}.

	Time 0	Time 1
VAS	7.5	0.9
SST	4	11.1
UCLA	12.1	32.7
		- 3 poor
		- 5 modest
		- 47 good
		- 81 excellent

Table 2. Mean scores reported in the 136 patients who underwent mini-Mumford.

	Time 0	Time 1
VAS	7.4	0.9
SST	4.3	11
UCLA	14.1	33
		- 2 poor
		- 3 modest
		- 14 good
		- 33 excellent

Table 3. Mean scores reported in the 52 patients who underwent isolated mini-Mumford.

	Time 0	Time 1
VAS	7.6	0.9
SST	3.4	11.2
UCLA	10.8	32.6
		- 1 poor
		- 2 modest
		- 33 good
		- 48 excellent

Table 4. Mean scores reported in the 84 patients who underwent mini-Mumford associated with arthroscopic surgery of rotator cuff and/or biceps long head.

Discussion

The arthroscopic approach to AC disease allows the avoidance of morbidity on muscle structures such as deltoid and trapezius and on upper capsular-ligamentous structures, which are critical for joint stability^{14,15}. It also allows a more detailed vision of the gleno-humeral and subacromial portions, which may be damaged and should be assessed intra-operatively¹¹. The use of the arthroscope from the posterior portal allows a correct display of the entire AC joint. At the end of the procedure it is also a good idea to evaluate the performance from the anterior portal, subsequently making any required adjustments. It should be stressed that

in order to have a correct view of the joint it is essential to perform the surgery under good blood pressure control and to prevent excessive bleeding, which may significantly complicate the procedure.

The results of Groups A and B were overlapping (Tabs. 2-3). It is important to note that patients who underwent an isolated mini-Mumford have obtained excellent results both in terms of pain and functionality^{10,18}. The excellent recovery of these patients indicates that the AC joint by itself causes a significant and painful disease, as can be seen from the pre-operative values of this group. Finally, we analyzed the individual cases that obtained a poor or modest result at UCLA and we studied the factors that may have influenced it^{3,17}. We identified factors such as inveterate irreparable lesions of the rotator cuff, altered scapular posture (with its strong anteposition that can not be corrected and a consequent chronic overloading of the AC joint), the presence of rheumatic diseases and, finally, the confirmation at the pre-operative MRI of a diffuse clavicular swelling. However, extreme care must be taken in completely removing the clavicle without leaving even small areas of contact, as these can cause an extremely painful overload.

The strengths of this prospective study include the sample size, and the use of 3 different rating scales: two subjective scales (VAS, TSS) and one objective scales (UCLA modified). Weak points include the different number of patients in the two groups (52 patients A, 84 patients B), the mid-term follow-up (18 months), and the higher mean age of group B compared to group A (63 years B, 46 years A).

This surgical procedure was effective both when performed alone or when associated with the reconstruction of the rotator cuff and/or tenotomy of the long head biceps^{6,9}.

The excellent results obtained by us are not always supported by the literature because the mini-Mumford associated subacromial decompression surgery is a common procedure and perhaps not always implemented correctly, similarly to decompression. A study by Fischer et al.¹⁹ observed the appearance of a painful symptomatology involving the AC articulation caused by interventions of sub-acromial decompression associated with a mini-Mumford in the presence of preoperative AC joint pathology (39% shoulders operated with mini-Mumford, developed pain on average in 8.4 months with a range from 1.8 to 19 months after surgery), with a significantly higher frequency compared to sub-acromial decompressions where the AC had not been touched and compare to subacromial decompression with complete distal clavicle resection (none of shoulders operated with the last two interventions reported AC joint pain). Docimo et al.³ stressed how diagnostic error was a possible complication of this type of intervention, if the AC joint contributes only in part to the pain of the patient's shoulder. They emphasized the importance of the role of arthroscopy in the investigation of the subacromial space and glenohumeral joint.

Mini-Mumford has been considered a not difficult procedure but as anterior acromionplasty need a correct indication for any patient in the way to not spoil the outcome.

The mini-Mumford is a simple, low-risk procedure, but it can ensure good results, even if performed alone. Symptomatic

acromioclavicular joint pathology must always be identified, even in the presence of lesions of the rotator cuff, to prevent residual post-operative symptoms.

It would be interesting to continue the follow-up in subsequent years so as to assess the possible recurrence of pain.

References

1. Pattee GA, Snyder SJ. Synovial chondromatosis of the acromioclavicular joint. A case report. *Clin Orthop* 1988; 233: 205-207.
2. Buttaci CJ, Stitik TP, Yonclas PP, Foye PM. Osteoarthritis of the acromioclavicular joint: A review of anatomy, biomechanics, diagnosis, and treatment. *Am j Phys Med Rehabil* 2004; 83: 791-797.
3. Docimo S, Kornitsky D, Futterman B, Elkowitz DE. Surgical treatment for acromioclavicular joint osteoarthritis: patient selection, surgical options, complications, and outcome. *Curr Rev Musculoskelet Med* 2008; 1:154-160.
4. Strobel K, Pfirman C, Zanetti M, Nagy L, Hodler J. MRI features of the acromioclavicular joint that predict pain relief from intraarticular injection. *AJR* 2003; 181: 755-760.
5. Kim J, Chung J, Ok H. Asymptomatic acromioclavicular joint arthritis in arthroscopic rotator cuff tendon repair: a prospective randomized comparison study. *Arch Orthop Trauma Surg* 2011; 131(3): 363-369.
6. Cuomo F, Kummer FJ, Zuckerman JD, Lyon T, Blair B, Olsen T. The influence of acromioclavicular joint morphology on rotator cuff tears. *J Shoulder Elbow Surg* 1998; 7(6): 555-559.
7. Edelson JG. Patterns of degenerative change in the acromioclavicular joint. *J Bone Joint Surg Br* 1996; 78(2): 242-243.
8. Stein BE, Wiater JM, Pfaff HC, Bigliani LU, Levine WN. Detection of acromioclavicular joint pathology in asymptomatic shoulders with magnetic resonance imaging. *J Shoulder Elbow Surg* 2001; 10(3): 204-208.
9. Lesko PD. Arthroscopic Mumford Procedure variation of technique. *The Iowa Orthopaedic Journal* 1999; 19: 93-98.
10. Snyder SJ, Banas MP, Karzel RP. The arthroscopic Mumford procedure: an analysis of results. *Arthroscopy* 1995; 11(2): 157-164.
11. Martin SD, Baumgarten TE, Andrews JR. Arthroscopic resection of the distal aspect of the clavicle with concomitant subacromial decompression. *JBJS Am* 2001; 83-A(3): 328-335.
12. Levine WN, Barron OA, Yamaguchi K, Pollock RG, Flatow EL, Bigliani LU. Arthroscopic distal clavicle resection from a bursal approach. *Arthroscopy* 1998; 1: 52-56.
13. Flatow EL, Duralde XA, Nicholson GP, Pollock RG, Bigliani LU. Arthroscopic resection of the distal clavicle with a superior approach. *J Shoulder and Elbow Surg* 1995; 4: 41-50.
14. Klimkiewicz JJ, Williams GR, Sher JS, Karduna A, Des Jardins J, Iannotti JP. Anatomical observations on the acromioclavicular joint and supporting ligaments. *J Shoulder Elbow Surg* 1999; 8(2): 119-124.
15. Dawson PA, Adamson GJ, Pink MM et al. Relative contribution of acromionclavicular joint capsule and coracoclavicular

- vicular ligaments to acromionclavicular stability. *J shoulder Elbow Surg* 2009; 18(2): 237-244.
16. Edwards SL, Wilson NA, Flores SE, Koh JL, Zhang LQ. Arthroscopic distal clavicle resection: a biomechanical analysis of resection length and joint compliance in a cadaveric model. *Arthroscopy* 2007; 23(12): 1278-1284.
 17. Fischer BW, Gross RM, McCarthy JA, Arroyo JS. Incidence of acromioclavicular joint complications after arthroscopic subacromial decompression. *Arthroscopy* 1999; 3:241-248.
 18. Eskola A, Santavirta S, Viljakka HT, Wirta J, Partio TE, Hoiikka V. The results of operative resection of the lateral end of the clavicle. *J Bone and Joint Surg* 1996; 4: 584-587.
 19. Fischer BW, Gross M, McCarthy JA, Arroyo JS. Incidence of acromioclavicular joint complications following arthroscopic subacromial decompression. *Arthroscopy* 1999; 15(3): 241-248.