

Is there a role of percutaneous drainage in non-parasitic splenic cysts? Case report

E. MORANDI, M. CASTOLDI, D.A. MERLINI, G. VIGNATI, M. MILANESI

SUMMARY: Is there a role of percutaneous drainage in non-parasitic splenic cysts? Case report.

E. MORANDI, M. CASTOLDI, D.A. MERLINI, G. VIGNATI, M. MILANESI

Pathogenesis, classification and treatment of non-parasitic splenic cysts (NPSCs) are controversial.

The utility of percutaneous aspiration of the cyst is not well understood.

We report a case of a 32 year-old woman with a symptomatic giant epidermoid cyst of the spleen treated with laparoscopic splenectomy. A percutaneous transcatheter drainage was performed under ultrasound guidance before surgical procedure in order to classify the type of cyst and to choose the best treatment.

RIASSUNTO: C'è indicazione al drenaggio percutaneo delle cisti spleniche non parassitarie? Caso clinico.

E. MORANDI, M. CASTOLDI, D.A. MERLINI, G. VIGNATI, M. MILANESI

La patogenesi, la classificazione e il trattamento delle cisti spleniche non parassitarie è controverso.

L'utilità del drenaggio percutaneo della cisti non è ben valutato.

Riportiamo il caso di una donna di 32 anni sottoposta a splenectomia laparoscopica per cisti splenica gigante epidermoide sintomatica. Sotto guida ecografica è stato posizionato un drenaggio percutaneo prima dell'intervento chirurgico al fine di classificare il tipo di cisti e di scegliere il miglior trattamento.

KEY WORDS: Non parasitic splenic cysts - Percutaneous drainage - Laparoscopic splenectomy.
Cisti spleniche non parassitarie - Drenaggio percutaneo - Splenectomia laparoscopica.

Introduction

Non-parasitic splenic cysts (NPSCs) are uncommon lesions of the spleen that may affect children and young adults. The term was firstly used in 1913 by Fowler, who classified them as true cysts and false cysts according to the presence or absence of lining epithelium. Nowadays there is still confusion about their pathogenesis and classification. The main classifications proposed are the ones of Flower, Pleiades and Morgestern (1), as well as a more recent classification proposed by Mirilas.

If etiology and pathogenesis are not clearly defined,

the best treatment of the splenic cysts is controversial. The aim of this report is to discuss the role of percutaneous treatment of the splenic cysts and its place as a step of surgical treatment.

Case report

A 32 year-old female was referred to our surgical department for a large splenic cyst diagnosed with ultrasonography (US) during a routine gynaecological examination. She had no history of trauma or parasitic disease. On physical examination a tender mass was detected in the patient's left upper and lower quadrant of the abdomen. Abdominal ultrasonography showed up a large abdominal lesion with fine hyperechoic spots. A CT scan of the abdomen confirmed a large uninocular splenic cyst with a maximum diameter of 26 cm (Figs 1 and 2). Serum concentration of the tumor marker CA 19-9 was markedly elevated.

We decided to perform a percutaneous drainage under US guidance leaving a 10 Fr pig tail catheter inside allowing for the complete emptying of the cyst. The brown fluid collected was sent to the laboratory for culture and chemical/cytological examination: no culture was positive; cytological examination was negative for malignant

"Guido Salvini" Hospital, Garbagnate Milanese, Milan, Italy
Rho Hospital, Rho, Milan, Italy

© Copyright 2012, CIC Edizioni Internazionali, Roma

tumor cells. An elevated concentration of CA 19-9 was even found in the cystic fluid collected.

The drain was left inside. The amount of fluid and serum concentration of CA 19-9 was checked daily. The cystic marker CA 19-9 reduced after a few days. The fluid output was 200 ml every day. Finally the spleen with the cyst was removed with laparoscopic procedure.

Discussion

Splenic cysts are rare, especially the non-parasitic ones (NPSCs) that account for 30-40% of all splenic cysts. Non-parasitic cysts are classified into primary cysts or true cysts, that are lined by an epithelium, and secondary cysts or pseudocysts, that lack a true epithelium. This classification has been paired with the primary-secondary classification even if some authors questioned the appropriateness of this ethiological classification. A new classification has been recently proposed by Mirilas et al. (2) to overcome the problems posed by the previous types, in order to avoid confusion and to reach a uniform classification.

Clinical evidence results from the size and the site of the cyst. Abdominal discomfort or pain are the most frequent symptoms. The cysts rupture in the case of trauma or even spontaneously and can cause complications such as infection, haemorrhage within the cyst, hypertension due to renal compression, hypersplenism and degeneration. Therefore it is always necessary to treat splenic cysts that tend to enlarge overtime. The problem is choosing the best option for treatment because we know the importance of splenic immunologic function.

Aspiration, marsupialisation, partial cystectomy (decapsulation), partial or total splenectomy are the main alternative treatment options.

Aspiration of the cyst with or without agents such as alcohol or tetracycline has high incidence of recurrence and is no longer recommended as definitive treatment (3). Marsupialization that consists of making an opening into the cystic wall for drainage has high incidence of recurrence and nowadays has been abandoned (4). Decapsulation, i.e. the near total resection of the cyst, especially laparoscopically, is an attractive conservative treatment but quite often it is followed by the regeneration of the cyst (5).

We propose the percutaneous aspiration as a bridge to surgery in order to plan the best treatment for the specific cyst. After the insertion of the drain it is important to measure the daily output of fluid to check if there is a progressive reduction of the amount of fluid as expected or a persistence of significant discharge. The chance of complete healing without recurrence is rare in the second case without removing the entire cystic wall. This means that decapsulation is not feasible unless a high re-

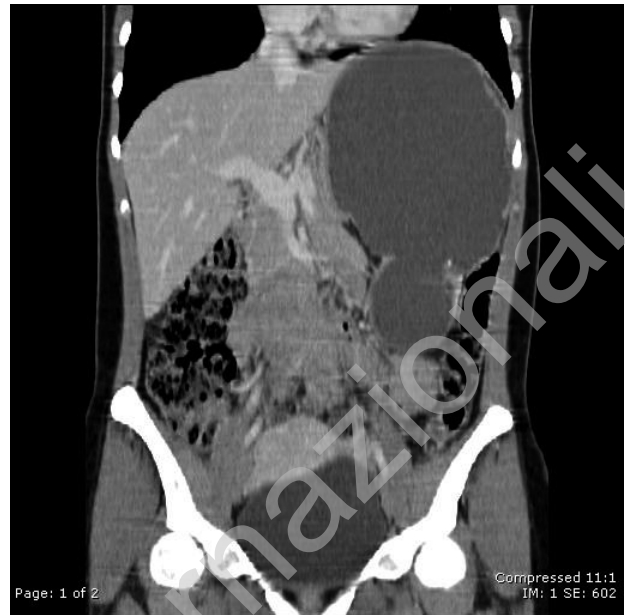

Fig. 1 - Coronal abdominal CT image showing the giant epidermoid cyst of the spleen.

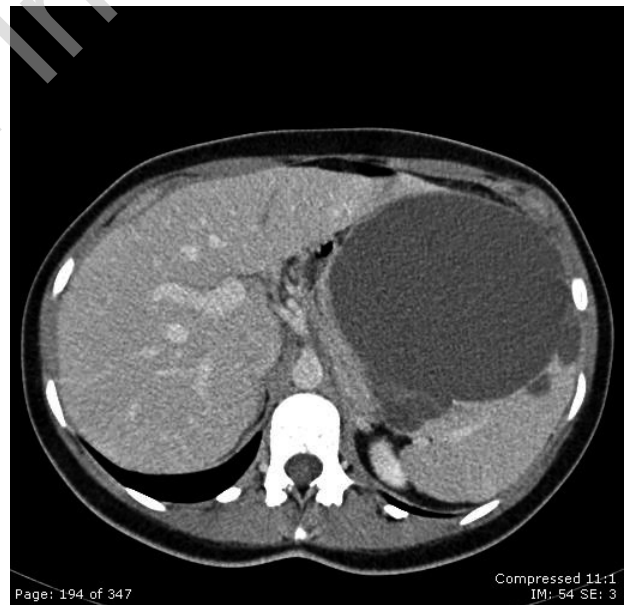


Fig. 2 - Axial abdominal CT image showing the giant epidermoid cyst of the spleen.

currence rate is expected, that is why it is better in this case to perform a partial or total splenectomy as a definitive treatment. The other purpose of percutaneous aspiration is to exclude malignancy through cytological examination of the aspirated fluid and the measurement of the concentration of the tumor marker CA 19-9 (6) that is supposed to be reduced over time in case of benignity.

The awareness of malignancy of the cyst before planning the operation has important implications because a conservative treatment shouldn't be proposed in this case and splenectomy still remain the only definitive treatment.

Our proposal, although it should be validated by large scale studies, suggests a possible role of the percutaneous drainage.

Conclusion

NPSCs are uncommon lesions of which treatment is controversial. Percutaneous drainage can be used to collect fluid for biological examination in order to evaluate the level of both CA 19.9 and CEA, to classify the type of cyst and, most important, as a bridge to surgery in order to plan the best treatment.

References

1. Morgestern L. Nonparasitic splenic cysts: Pathogenesis, classification and treatment. *J Am Coll Surg* 2002;194:306-314.
2. Mirilas P, Mentessidou A, Skandalakis JE. Splenic cysts: are there so many types? *J Am Coll Surg* 2007;204:459-465.
3. Hansen MB, Moller AC. Splenic cysts. *Surg Laparosc Endosc Percut tech* 2004;14:316-22.
4. Schier F, Waag K, Ure B. Laparoscopic unroofing of splenic cysts results in a high rate of recurrence. *J Pediatric Surg* 2007;42:1860-1863.
5. Fisher JC, Gurung B, Cowles RA. Recurrence after laparoscopic excision of nonparasitic splenic cysts. *J Pediatr Surg* 2008;43:1644-1648.
6. Trompetas V, Panagopoulos E, et al. Giant benign true cyst of the spleen with high serum level of CA 19-9. *Eur J Gastroenterol Hepatol* 2002;14:85-88.