

Evaluation of negative pressure vacuum-assisted system in acute and chronic wounds closure. Our experience

S. CHIUMMARIELLO, G. GUARRO, A. PICA, C. ALFANO

SUMMARY: Evaluation of negative pressure vacuum-assisted system in acute and chronic wounds closure. Our experience.

S. CHIUMMARIELLO, G. GUARRO, A. PICA, C. ALFANO

Negative-pressure therapy or vacuum-assisted closure (VAC) has been used in clinical applications since the 1940's and has increased in popularity over the past decade (1). This dressing technique consists of an open cell foam dressing put into the wound cavity, a vacuum pump produces a negative pressure and an adhesive drape. A controlled sub atmospheric pressure from 75 to 150 mmHg is applied.

The vacuum-assisted closure has been applied by many clinicians to chronic wounds in humans; however it cannot be used as a replacement for surgical debridement. The initial treatment for every contaminated wound should be the necrosectomy. The VAC therapy has a complementary function and the range of its indications includes pressure sores, stasis ulcers, chronic wounds such as diabetic foot ulcers, post traumatic and post operative wounds, infected wounds such as necrotizing fasciitis or sternal wounds, soft-tissue injuries, bone exposed injuries, abdominal open wounds and for securing a skin graft.

We describe our experience with the VAC dressing used to manage acute and chronic wounds in a series of 135 patients, with excellent results together with satisfaction of the patients.

RIASSUNTO: Valutazione dell'utilizzo della terapia a pressione negativa per la chiusura di lesioni acute e croniche: nostra esperienza.

S. CHIUMMARIELLO, G. GUARRO, A. PICA, C. ALFANO

La terapia a pressione negativa o Vacuum-Assisted Closure (VAC) fu introdotta nella pratica clinica già dal 1940, aumentando in popolarità negli ultimi dieci anni (1). Questa tecnica consiste di una medicazione espansa a celle aperte che viene posizionata sul letto della ferita, di una pompa che produce una pressione negativa e di una pellicola adesiva che sigilla il tutto. La macchina è in grado di mantenere una pressione sub-atmosferica costante di 75-150 mmHg. La terapia a pressione negativa è stata utilizzata dai clinici per il trattamento di ferite croniche nell'uomo, tuttavia però non può sostituirsi al debridement chirurgico. Il trattamento iniziale di ogni ferita contaminata dovrebbe essere la necrosectomia. La terapia VAC ha una funzione complementare e il range delle sue indicazioni varia da piaghe da decubito, ulcere da stasi, ferite croniche come ulcere diabetiche del piede, ferite traumatiche e post-operatorie, fino a ferite infette come fasciti necrotizzanti o sternali, ferite dei tessuti molli, esposizioni ossee, lesioni addominali, ferite aperte, così come per la "messa in sicurezza" un innesto cutaneo.

Nel seguente articolo descriviamo la nostra esperienza circa l'impiego della VAC therapy per la gestione di ferite acute e croniche in una serie di 135 pazienti, con ottimi risultati personali associati anche alla soddisfazione dei pazienti.

KEY WORDS: Negative pressure wound closure - Vacuum-assisted closure (VAC).
Trattamento a pressione negativa ferite difficili - VAC.

Introduction

In 1998 Schneider et al. and Blackburn et al. described the use of the vacuum-assisted closure (VAC®) device ne-

gative pressure dressing (KCI, San Antonio, TX, USA) for stabilizing skin grafts by immobilizing themselves, limiting shear stresses, eliminating fluid collections and decreasing bacterial contamination: it led to a graft successful rate greater than 95% (2). Since it was introduced (Fleischmann et al. 1995, Morykwas et al. 1997) it gained large consensus and attentions from clinicians (3, 4) whom started to use it for the treatment of chronic wounds.

This dressing technique consists on an open cell foam dressing put into the wound cavity, connecting it to a vacuum pump with a tube and covering it with an adhe-

University of Perugia, Perugia, Italy
Division of Plastic, Reconstructive and Aesthetic Surgery
(Director: C. Alfano)

© Copyright 2012, CIC Edizioni Internazionali, Roma

sive drape. Despite everything, vacuum-assisted closure therapy cannot be used as a replacement for surgical debridement: initial treatment for every contaminated wound is a necrosectomy (5). Vacuum-assisted closure has a complementary function, and its range of indications includes pressure sores, stasis ulcers, chronic wounds such as diabetic foot ulcers, posttraumatic and postoperative wounds, infected wounds such as necrotizing fasciitis or sternal wounds, soft-tissue injuries, injuries with bone exposure, open abdominal wounds as well as to secure a skin graft.

VAC[®] exposes the wound bed to a negative pressure able to remove fluid from the extravascular space, improves circulation and promotes wound healing and granulation tissue formation as well as to reduce bacterial load (6-8).

We describe our experience with the VAC[®] therapy for the treatment of acute/chronic wounds in 135 patients, during a period of 6 years.

Patients and methods

Between January 2006 and December 2011, at Plastic & Reconstructive Surgery Department of Perugia University, 135 patients were managed for a total of 148 acute/chronic wounds with the negative pressure therapy; 73 (54%) were males and 62 (46%) women with a median age of 42 years. The aetiology of the wounds

was very heterogenic as represented in Figure 1; location of the wounds is shown in Figure 2. The study performed was a randomized controlled trial. Primary outcome measures to assess efficacy were: wound-healing time, granulation rate, change in wound surface and volume (calculated with Xakellis and Frantz method) (9), pain, bacterial clearance, total costs and time of the nursing staff involvement.

Secondary outcome measures were adverse effects and comfort. Wound-healing time was calculated from the date of initial debridement to the date of reaching an endpoint represented by the achievement of a complete granulated wound or a wound ready state for skin grafting or healing by secondary intention.

Exclusion criteria are those mentioned in Table 1. All patients gave written informed consent.

In the wounds was applied a GranuFoam[®] sponge sealed with an adhesive semi-occlusive drape (VAC[®] drape); continuous negative pressure at 75 to 125 mmHg was applied and the dressing was

TABLE 1 - PATIENTS EXCLUSION CRITERIA.

Use of steroid drugs
Malignancy in the wound
Deep fistulas
Sepsis
Underlying osteomyelitis
Patients younger than 18
Severe peripheral vascular disease (ABI < 0,6)

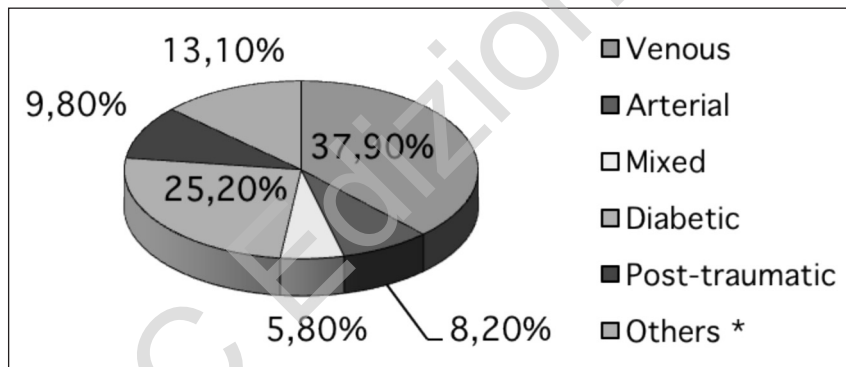


Fig. 1 - Wound's aetiology.
* post-surgical, burns and lymphatics.

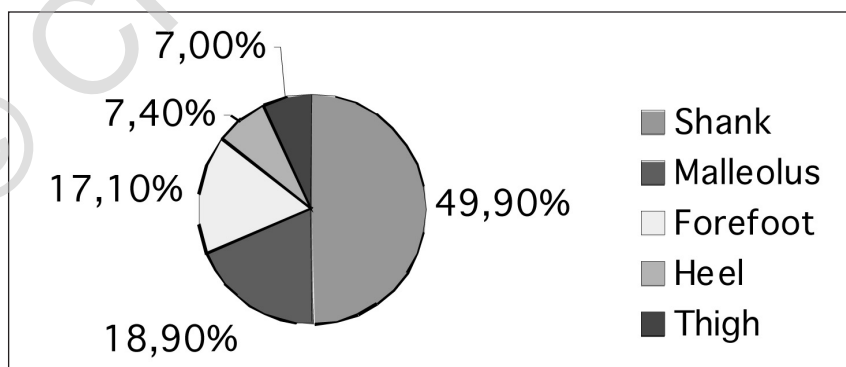


Fig. 2 - Localization of the wounds.

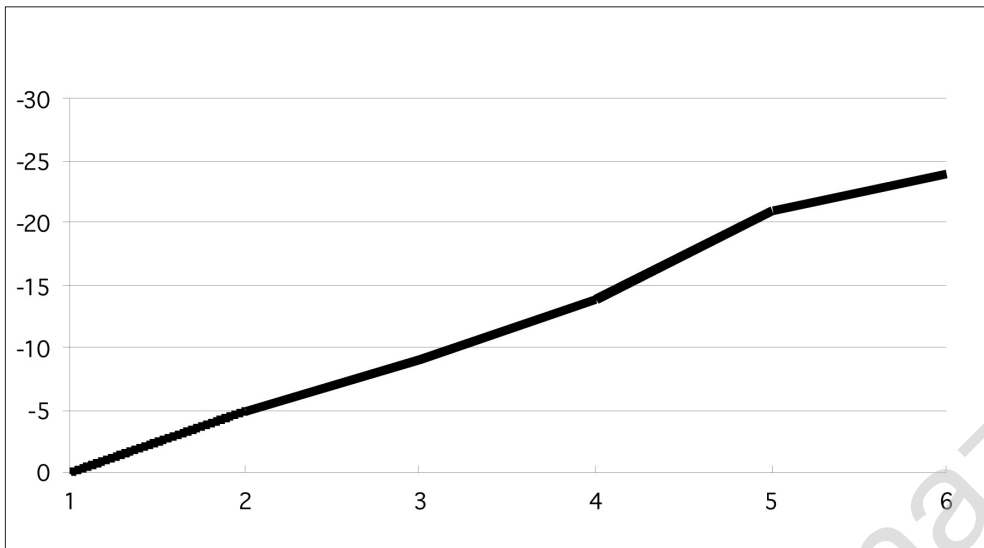


Fig. 3 - Changes in wounds area.

changed every 48 hours as recommended in VAC® guidelines. The VAC® therapy was applied following the first debridement and washing of the necrotic and infected wounds. In accordance with the severity of the wound, patients were exposed to a continuous negative pressure for the first two sessions; intermittent treatment (5 min of suction followed by a break of 2 min) was then delivered at the same pressure.

Results

The VAC® therapy has proved to be very helpful in the treatment of these kind of lesions: the granulation tissue formation was achieved after a mean time of 7.5 days of treatment, with exudate reduction and absence of infection. The treatment was interrupted when vital granulation tissue was formed on the lesion's bottom and/or when the exudation rate was < 20 ml/day. The rate of reduction in wound area was about 5.2 %/day (Fig. 3).

The 12 % (16) of the patients didn't get any improvement from the therapy and were classified as "no responders": the main problem was the compliance of the patients, especially the oldest ones with cognitive impairment. In 3 cases the VAC therapy was discontinued because of a hematoma developing under the dressing after the second day; in 4 patients it was necessary to precede with a split thickness skin graft to cover the defect area since the NPWT was not itself sufficient to achieve a secondary intention healing. The only complain has been the pain, felt especially during the beginning of the treatment but anyway never being a limiting factor. Most of the patients found out this technique to be more comfortable than the classical wound closure therapy, since fewer dressing were required and there was less smell and leakage (Figs. 4, 5).

Discussion

Vacuum-assisted closure therapy has been commonly used during the past decade for acute and chronic wounds. The granulation tissue forms with the VAC therapy is high quality, rich in capillary and totally suitable to receive a skin graft or, if well-controlled during the follow-up, to allow the wound to close by secondary intention. Negative pressure wound therapy provides significant reduction in the wound size. Some studies demonstrated wound volume could be reduced by 59% (10), allowing to reduce the graft dimension and promoting the healing of a smaller wound.

In our experience the VAC therapy has proved very useful in acute/chronic wounds treatment especially in big traumas, diabetic ulcers (reducing the amputation risk) and in the poorly vascularized post-traumatic lesions (11). Our results are comparable to those of other studies performed with vacuum-assisted closure therapy: it seems to be true that vacuum-assisted closure therapy results in faster granulation tissue formation and faster surface area reduction during the first week of treatment. A very important advantage of vacuum-assisted closure therapy is its comfort for the patient mainly because the dressing changes can be reduced to 3 times/week and because the lack of smell and fluid leakage.

Conclusions

Our results show that vacuum-assisted closure therapy provides wound healing that is at least as fast as wound healing with modern wound dressings overall in

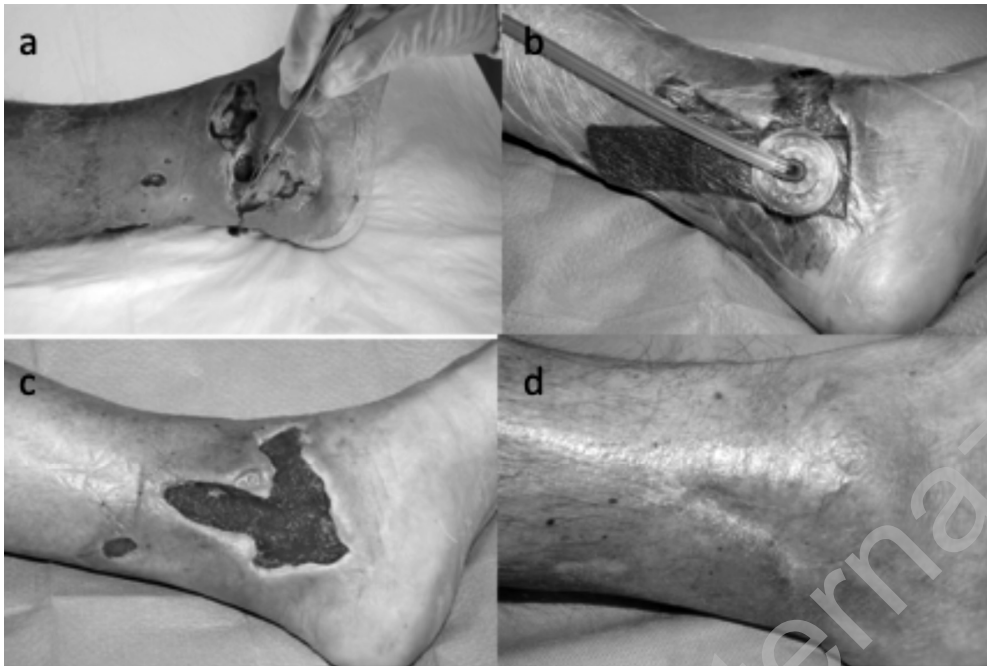

Fig. 4 - A 58 yrs diabetic patient. (a) Before treatment; (b, c) During the therapy: note the great improvement of the granulation tissue; (d) Result of treatment after split-thickness skin grafting.

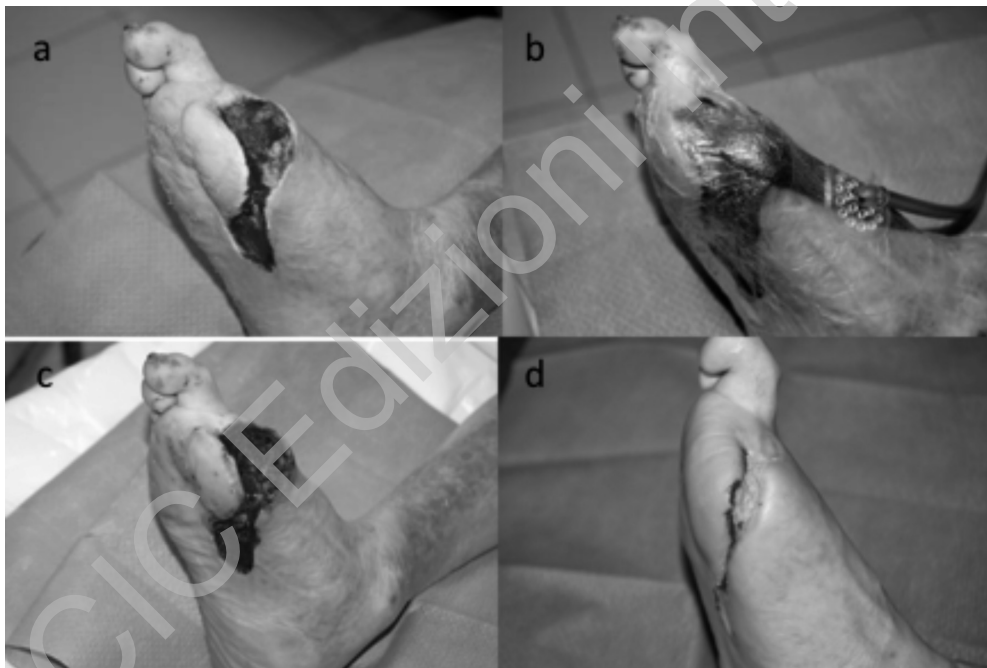


Fig. 5 - A 62 yrs diabetic patient. (a) Before treatment; (b, c) During VAC therapy; (d) Result after 107 days of treatment.

patients with acute and chronic wounds. It is more comfortable for patient and nursing staff.

The VAC therapy deserves a prominent place in the treatment of patients with acute and chronic wounds; however, more research needs to be conducted to confirm our results since in the literature there are contrasting opinions.

In conclusion, our results suggested that VAC therapy, together with debridement and accurate and appropriate antibiotics therapy, enables a higher rate of wounds healing, reducing the hospitalization period as well as the costs resulting in increasing of patient comfort and satisfaction. All this compensates the increased costs associated with the use of this kind of treatment.

References

1. Morykwas MJ, Faler BJ, Pearce DJ, Argenta LC. Effects of varying levels of subatmospheric pressure on the rate of granulation tissue formation in experimental wounds in swine. *Ann Plast Surg* 2001;47:547.
2. Morykwas MJ, Argenta LC, Shelton-Brown EI, McGuirt W. Vacuum-assisted closure: A new method for wound control and treatment. Animal studies and basic foundation. *Ann Plast Surg* 1997;38:553.
3. Fleischmann W, Becker U, Bischoff M, Hoekstra H. Vacuum sealing: Indication, technique and results. *Eur. J. Orthop Surg Traumatol* 1995;5:37.
4. Morykwas MJ, Argenta LC. Nonsurgical modalities to enhance healing and care of soft tissue wounds. *J South Orthop Assoc* 1997;6(4):279-88.
5. Attinger CE, Bulan EJ. Debridement: The key initial first step in wound healing. *Foot Ankle Clin* 2001;6:627.
6. Arslan E, Ozturk OG, Aksoy A, Polat G. Vacuum-assisted closure therapy leads to an increase in plasma fibronectin level. *Int Wound J* 2011;8(3):224-8. doi: 10.1111/j.1742-481X.2011.00772.x. Epub 2011 Mar 15.
7. Nather A, Chionh SB, Han AY, Chan PP, Nambiar A. Effectiveness of vacuum-assisted closure (VAC) therapy in the healing of chronic diabetic foot ulcers. *Ann Acad Med Singapore* 2010;39(5):353-8.
8. Mouës CM, Heule F, Hovius SE. A review of topical negative pressure therapy in wound healing: sufficient evidence? *Am J Surg* 2011;201(4):544-56.
9. Xakellis GC Jr, Frantz RA. Pressure ulcer healing: what's it? What influences it? How is measured? *Adv Wound Care* 1997;10:20-26.
10. Eginton MT, Brown KR, Seabrook GR, Towne JB, Cambria RA. A prospective randomised evaluation of negative-pressure wound dressing for diabetic foot wounds. *Ann Vasc Surger* 2003;17:645-649.
11. Teot L. VAC for treatment of difficult wounds. *ETRS* 2007.