

## Colorectal retained foreign bodies per anum introduced. Three years retrospective study at Emergency Surgery Unit

A. VOLPI, A. PANEBIANCO, P. IALONGO, E. FERRANTE<sup>1</sup>, M.A. MILELLA, B. PASCAZIO, A. PRESTERA, A. TROMBA, N. PALASCIANO

**SUMMARY:** Colorectal retained foreign bodies per anum introduced. Three years retrospective study at Emergency Surgery Unit.

A. VOLPI, A. PANEBIANCO, P. IALONGO, E. FERRANTE, M.A. MILELLA, B. PASCAZIO, A. PRESTERA, A. TROMBA, N. PALASCIANO

*Colorectal foreign bodies per anum introduced are not exceptional. They can be classified as high-lying or low-lying, depending on their location relative to the recto-sigmoid junction. High-lying rectal foreign bodies sometimes require surgery; low-lying ones are often palpable by digital examination and can be removed at bedside. No reliable data exist regarding the frequency of inserted rectal foreign bodies and the literature is largely anecdotal. We review our experience on patients almost all males and heterosexual with retained colorectal foreign bodies and their outcome in Surgical Emergency Unit of a Southern Italy University hospital.*

**RIASSUNTO:** Corpi estranei coloretali ritenuti introdotti per via anale. Studio retrospettivo della durata di 3 anni in una Unità di Chirurgia d'Urgenza.

A. VOLPI, A. PANEBIANCO, P. IALONGO, E. FERRANTE, M.A. MILELLA, B. PASCAZIO, A. PRESTERA, A. TROMBA, N. PALASCIANO

*La presenza di corpi estranei colo-rettali introdotti per via anale non si osserva frequentemente. In relazione alla sede al di sopra o al di sotto della giunzione retto-sigmoidea vengono classificati in high-lying e low-lying: i primi richiedono a volte l'intervento chirurgico, i secondi vengono evidenziati con l'esplorazione rettale e rimossi in ambulatorio. Non ci sono attualmente dati riguardanti la frequenza di questa patologia e la letteratura disponibile è per la maggior parte aneddotica. Noi abbiamo voluto considerare la nostra esperienza clinica, di tre anni, in un campione di pazienti, tutti eterosessuali e per la maggior parte di sesso maschile, condotta in una Unità di Chirurgia d'Urgenza di un importante ospedale universitario dell'Italia meridionale.*

**KEY WORDS:** Colorectal foreign bodies - Colorectal trauma.  
Corpi estranei coloretali - Trauma coloretale.

### Introduction

Colorectal foreign bodies (FB) are not an uncommon presentation to the Emergency Department but are well known by medical and nurse staff. One of the earliest case reports was published in 1919 (1), although Haft and Benjamin (2) referred to a case as long ago as the Sixteenth century.

Rectal foreign bodies can be classified as high-lying

or low-lying, depending on their location relative to the recto-sigmoid junction.

Bodies that are above the rectosigmoid junction are difficult to visualize and remove, and are often unreachable by rigid proctosigmoidoscope and sometimes require surgery. Low-lying rectal foreign bodies are often palpable by digital examination and can be removed at bedside (3).

This study was designed to review our experiences with retained colorectal foreign bodies and to study the management and the outcome of these patients in Surgical Emergency Unit of Southern Italy University Hospital.

### Patients and methods

A review of emergency surgical consultation records from June 2007 through June 2010 at 3<sup>rd</sup> General Surgery Unit of the University

University of Bari, Bari, Italy  
Department of Emergency and Organ Transplantation (DETO)  
III General Surgery Unit  
<sup>1</sup> Faculty of Nursing Sciences

© Copyright 2012, CIC Edizioni Internazionali, Roma

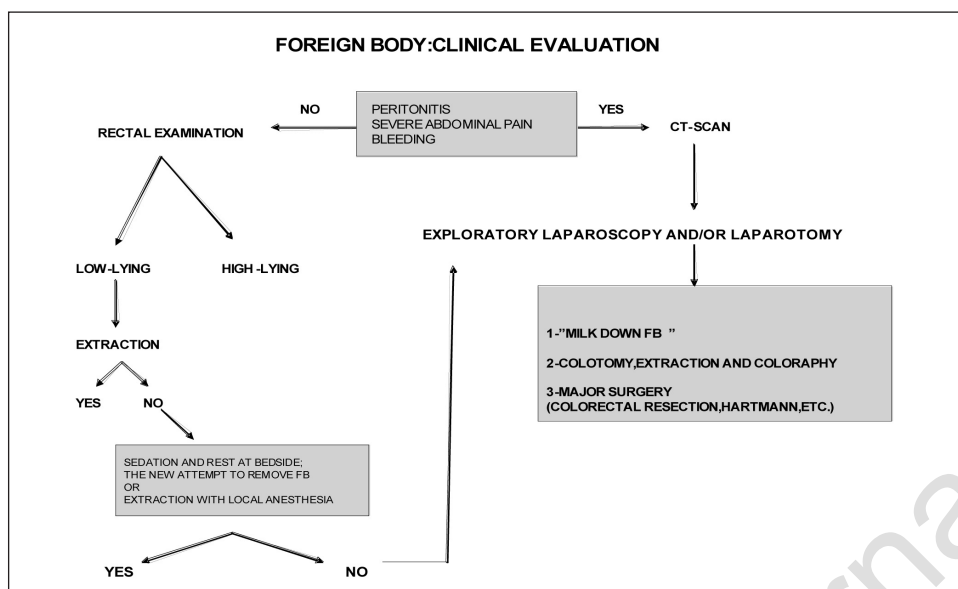


Fig. 1 - Therapeutic algorithm for colorectal retained foreign bodies.

of Bari yielded 10 patients with the diagnosis of rectal retained foreign body per anum introduced. Patient demographics data including age, gender, sexual behaviour, type, size and location of FB, purpose of introduction, diagnostic tools, length of hospital stay and treatments were collected in a data-base. Our practice follows the scheme showed in Figure 1. No statistical analysis were performed.

## Results

Ten patients (all heterosexual) were enrolled in the study 7 male and 3 females (one pregnant) with median age 40 years (range 15-78): 5 underwent only surgical consultation, 5 were admitted in the Unit. The FB retrieved are described in Table 1; two of these were high-lying rectal FB (wooden rasp, vibrator) and 8 were below rectosigmoid junction.

In 8 patients abdomen X-ray were performed. In a

patient with condom's fragment retained x-ray was not necessary because the FB was easily removed; in the pregnant x-ray was not indicated. The purposes of introduction are described in Figure 2. In 30% of cases, the purpose was unrecorded in data base or unsaid by the patients.

Two patients left the Unit without medical authorization: a pregnant who declared that FB was removed during the hospital stay, without medical help and a psychotic patient who suddenly left the hospital with FB still retained. The Figure 3 shows the procedures to remove FB. Only two patients required CT scan and surgery: the first underwent Hartmann's procedure, and the second only required a colotomy to remove FB. No postoperative complication were recorded.

The average length of hospital stay was 3,5 days (median 2 days; range 1-10 days).

TABLE 1 - FOREIGN BODIES RETAINED.

PTS.	FOREIGN BODIES
2	VEGETABLES(CARROT,SMALL PUMPKIN)
1	FRUITS(APPLE)
1	PLASTIC TOP (PINE CONE SHAPED)
1	WOODEN RASP
1	GLASS PROBE
1	RUBBER PUPPET
1	TUBE ( CONTAINING CALCIUM TABLETS )
1	CONDOM fragment
1	VIBRATOR

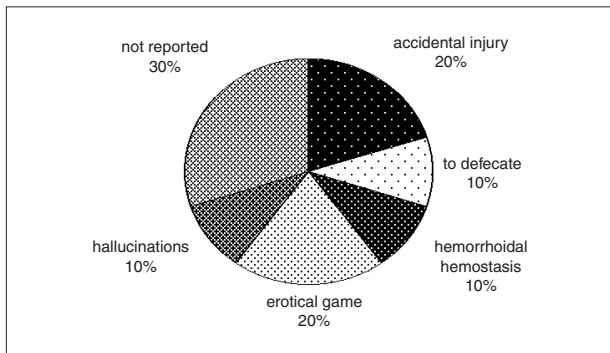


Fig. 2 - Purpose of foreign bodies introduction.

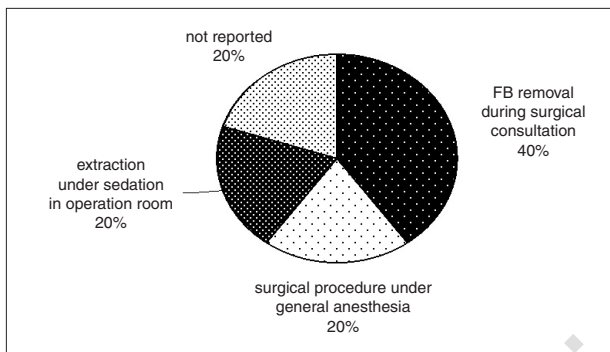


Fig. 3 - Foreign bodies removal procedures.

## Discussion

Colorectal foreign bodies are usually inserted, as result of erotic activity, but sometimes a foreign body may be swallowed, pass through the digestive tract, and eventually get hold up in the rectum. The retained objects are typically dildoes or vibrators, fruits or vegetables, although almost any object can be found, including light bulbs, candles, shot glasses, and odd or unusually large objects such as bottles or other large objects.

No reliable data exist regarding the frequency of inserted rectal foreign bodies. Literature consists of occasional case reports, but more recently case series and descriptions of evaluation and extraction techniques have been documented. The reason is correlated to increase of the use of various objects for anal eroticism (as daily medical experience suggests) and this resulting in an increased incidence of retained foreign bodies and following complications. Controlled studies of patients with rectal foreign bodies have not been conducted, and the literature is largely anecdotal (4,5).

FB in the colon, rectum and anus are an increasing cause of mortality and morbidity. The matter remains taboo and often provokes humorous reactions from staff, but sometimes it can be serious or even life-threatening.

In fact, frequently, delay in presentation and multiple attempts at self-removal lead to mucosal edema and muscular spasms, further hindering removal. Rectal lacerations and perforations may occur but are less common than other complications (6).

These patients usually present to the Emergency Unit, because of pain, or rectal bleeding, often after multiple attempts to remove the object. Presentation is almost always delayed because of embarrassment and occurred most often within 24 h of insertion. The majority of objects were removed transanally using manual manipulation with or without the use of a variety of tools, or via a scope.

Age distribution is bimodal, with peaks in the 20s (anal erotism) and 60s (thought to be secondary to the use of foreign objects for prostatic massage) (7). Most patients are in the age range of 20-30 years.

Our results are similar to international reports: prevalence in men, surgical procedures in 20% of cases.

Colorectal FB are uncommon but is well known by medical and nurse team they are usually inserted during an erotic game. The colorectal retention of FB during erotic games are an underestimate problem; the real incidence is still unknown. The patients require strictly confidential approach and often they lie about the purpose of FB retained.

FB are retained in rectum or sigma for other reasons beyond sexual game. Patients should be asked if the foreign body is the result of assault because this is more likely to result in a serious injury; these cases are notified legal authorities (7).

Detailed history and physical examination are essential for diagnosis and management, in addition to others diagnostic techniques. Type, size and surface pattern of FB are also important: glass objects, breakable or friable objects, sharp or nonsmooth objects may be dangerous. Admission for treatment occurred most often 24 hours from insertion and the majority were removed transanally, using manual manipulation with or without the use of various tools or by endoscopy. Time since insertion and presence of rectal or abdominal pain, fever, or rectal bleeding are important elements of the history. Attempts to extract FB are safely performed under general anaesthesia as this achieves painless removal and relaxes the anal sphincter facilitating nontraumatic retrieval (8).

Medical literature shows few studies about these conditions, most multicentric with huge pts range, recruited up to 10 years. As published by international literature, the management of these patients was strictly gastroenterologic, except those cases that require surgery. In our experience all has been managed by surgeons, although only 20% requires surgery: this means increase of health service cost and unavailability of places in surgery units.

## Conclusion

The keys to adequate care for patients with colorectal FB are: respect for their privacy, evaluation of the type and location of the foreign body, evaluation if extraction can be performed in the Emergency room or if surgery is needed, and use of appropriate techniques for removal. For these reasons it is very important the triage at admission. It is necessary to maintain a high suspicion index of rectal foreign body in psychiatric patients or prisoners who present with rectal pain or bleeding (3). Caregivers should refrain from making disparaging or comical remarks concerning the nature of the problem and

prevent invasions of the patient's privacy by curious hospital staff. The incidence of CFBs is higher in men. The various techniques for removal are available, including minimally invasive procedures. The appropriate technique will depend on the size and surface of the retained object and the presence of complications such as perforation or obstruction. Surgery is required in about 20% also in our database and we think that the problem may be often solved at the Emergency room; only patients with complication must be admitted in a surgical ward. Moreover, with increasing of these sexual habits (8) it is necessary to suggest the use of no traumatic object, a proctological follow-up or proper referral (10).

## References

1. Gould GM, Pyle W. Anomalies and curiosities of medicine. Philadelphia: WB Saunders, 1901:645-8.
2. Smith D. Rectal Foreign Body. *Cal West Med* 1939; 51(5):329.
3. Stack LB, Munter DW. Foreign bodies in the gastrointestinal tract. *Emerg Med Clin North Am* 1996;14(3):493-521.
4. Haft JS, Benjamin HB, Wagner M. Vaginal vibrator lodged in rectum. *Br Med J* 1976;1(6010):626.
5. Turner B. Management of retained foreign bodies and rectal sexual trauma. *Nurs Times* 2004;100(38):30-2.
6. Lake JP, Essani R, Petrone P, Kaiser AM, Asensio J, Beart RW Jr. Management of Retained Colorectal Foreign Bodies: Predictors of operative intervention. *Dis Colon Rectum* 2004;47(10):1694-8.
7. Rodriguez-Hermosa JI, Codina-Cazador A, Ruiz B, Sirvent JM, Roig J, Farres R. Management of foreign bodies in the rectum. *Colorectal Dis* 2007;9(6):543-8.
8. Kurer MA, Davey C, Khan S, Chintapatla S. Colorectal foreign bodies: a systematic review. *BMJ* 1999;318(7181):452-455.
9. Sharma H, Banka S, Walton R, Memon MA. A novel technique for nonoperative removal of round rectal foreign bodies. *Tech Coloproctol* 2007 Mar;11(1):58-9.
10. Bell R. ABC of sexual health. Homosexual men and women. [http://www.mckinley.illinois.edu/handouts/anal\\_sex.html](http://www.mckinley.illinois.edu/handouts/anal_sex.html).