

Incidental cancer in patients surgically treated for benign thyroid disease. Our experience at a single institution

D. COSTAMAGNA¹, L. PAGANO², M. CAPUTO², M. LEUTNER³, F. MERCALLI³, A. ALONZO¹

SUMMARY: Incidental cancer in patients surgically treated for benign thyroid disease. Our experience at a single institution.

D. COSTAMAGNA, L. PAGANO, M. CAPUTO, M. LEUTNER, F. MERCALLI, A. ALONZO

Increased incidence of incidental cancer in patients operated for benign thyroid disease has been reported. We report our experience about incidental thyroid cancer (ITC) in order to better characterize this nosologic entity.

Between 2001 and 2009 a total of 568 patients underwent surgery for benign thyroid disease. Patients with preoperative cytology undetermined or positive for malignancy were excluded. The most frequent indication for surgery was multinodular or diffuse nontoxic goiter. We performed total thyroidectomy in 499 cases and emithyroidectomy in 69 cases. Final histology revealed ITC in 53 patients (9.3%): 44 had papillary carcinoma (20 classic variant and 24 follicular variant), 4 follicular carcinoma, 4 medullary carcinoma and 1 primitive thyroid paraganglioma. The preoperative diagnosis was multinodular or diffuse goiter in 45 cases of ITC and uninodular goiter in 8 cases. We performed total thyroidectomy in 46 case, emithyroidectomy in 4 patients with past history of lobectomy, emithyroidectomy in 3 patients with following radicalization and central neck dissection. In 14 patients the tumor was multifocal and in 12 of these patients the tumor foci were bilateral. The lesion was a microcarcinoma in 34 cases. Mean diameter of the ITC was 1.14 cm.

We retrospectively reconsidered the results of preoperative ultrasound examinations in relation to the exact position of the tumor in the specimens and we found a statistically significant association between echogenicity and papillary histotype. Twenty-six patients were followed up at our Hospital. The mean follow-up period was 38.2 months. A relapse was observed in 3/26 patients.

Incidental thyroid cancer in patients operated for benign disease has its own surgical and oncological relevance. A correct preoperative assessment, with a careful selection of nodules for fine-needle aspiration cytology on the basis of ultrasound pattern, could better address the choice of surgical procedure. The non irrelevant incidence of incidental thyroid cancer, the eventuality of multifocality and bilaterality and the possible occurrence of relapse, support that total thyroidectomy without residuum is a valuable option for treating benign thyroid conditions such as multinodular goitre. When an incidental cancer is diagnosed after emithyroidectomy, a radicalization with central neck dissection

RIASSUNTO: Il carcinoma incidentale nei pazienti operati per patologia tiroidea benigna. L'esperienza di un singolo centro.

D. COSTAMAGNA, L. PAGANO, M. CAPUTO, M. LEUTNER, F. MERCALLI, A. ALONZO

In letteratura è descritto un incremento costante di tumori incidentali in pazienti operati per patologia tiroidea benigna. Nel presente studio riportiamo la nostra esperienza in merito al tumore incidentale della tiroide allo scopo di meglio definire questa entità nosologica.

Dal 2001 al 2009 abbiamo sottoposto ad intervento per patologia benigna 568 pazienti. Sono stati esclusi i pazienti con citologico preoperatorio indeterminato o positivo per malignità. L'indicazione più frequente alla chirurgia è stato il gozzo multinodulare o diffuso non tossico. Abbiamo eseguito una tiroidectomia totale in 499 casi ed una emitiroidectomia in 69 casi. L'istologico definitivo ha rivelato un tumore incidentale in 53 pazienti (9.3%): 44 carcinomi papillari (20 variante classica e 24 variante follicolare), 4 carcinomi follicolari, 4 carcinomi midollari e un paraganglioma primitivo della tiroide. La diagnosi preoperatoria era gozzo multinodulare o diffuso in 45 casi e gozzo uni-nodulare in 8 casi. Abbiamo eseguito una tiroidectomia totale in 46 pazienti, emitiroidectomia in 4 pazienti con pregressa lobectomia, emitiroidectomia con successiva radicalizzazione e dissezione linfonodale del comparto centrale in 3 pazienti. In 14 pazienti il tumore era multifocale ed in 12 di questi pazienti i focolai erano bilaterali. La lesione era un micro-carcinoma in 34 casi. Il diametro medio delle lesioni era 1.14 cm.

Abbiamo riconsiderato retrospettivamente i risultati delle ecografie preoperatorie in relazione all'esatta posizione del tumore sul pezzo operatorio: abbiamo trovato un'associazione statisticamente significativa fra ecogenicità e istotipo papillare. Ventisei pazienti sono stati seguiti presso il nostro ospedale. Il follow-up medio è stato 38.2 mesi. È stata osservata una recidiva in 3/26 pazienti.

Il cancro incidentale della tiroide in pazienti operati per patologia tiroidea benigna ha una propria rilevanza oncologica.

Uno studio preoperatorio corretto, con attenta selezione dei noduli da sottoporre ad ago aspirato sulla base delle caratteristiche ecografiche, potrebbe meglio indirizzare la scelta dell'approccio chirurgico. La non irrilevante incidenza del cancro incidentale della tiroide, l'eventualità di multifocalità e bilaterali e la possibilità di recidiva supportano il fatto che la tiroidectomia totale sia una valida opzione per il trattamento di patologie tiroidee come il gozzo multinodulare. Quando un tumore incidentale viene diagnosticato dopo emitiroidectomia, potrebbe essere considera-

"Maggiore della Carità" University Hospital, Novara, Italy

¹ Second Division of General Surgery

² Division of Endocrinology and Metabolism

³ Division of Pathology and Anatomy

© Copyright 2013, CIC Edizioni Internazionali, Roma

could be considered. We suggest that natural history of papillary microtumors and the correct surgical approach for these lesions could be better defined with a more extensive use of "Porto proposal" criteria.

ta una radicalizzazione con dissezione linfonodale del comparto centrale. Sugeriamo infine che la storia naturale dei microtumori papillari e un corretto approccio chirurgico a tali lesioni potrebbe essere meglio definito con un impiego più esteso dei "Porto proposal" criteria.

KEY WORDS: Incidental thyroid cancer - Papillary microcarcinoma - Papillary microtumors - Total thyroidectomy.
Tumore incidentale della tiroide - Microcarcinoma papillare - Microtumori papillari - Tiroidectomia totale.

Introduction

Incidental thyroid cancer (ITC) is a malignancy undetected by preoperative imaging studies but identified by pathological examination of surgical specimens in patient treated for benign thyroid diseases (1). The incidence of incidental cancer ranges between 3 and 16% (2). ITCs are mainly microcarcinomas. During the last decades decreased mean tumor size has been observed (from 28 to 14 mm in the last 10 years), with increased percentage of thyroid microcarcinoma (3). Most of microcarcinomas are papillary thyroid cancer. In the Literature, an increased incidence of ITC, particularly the papillary microcarcinomas, has been described (3, 4). This exponential increase could possibly be explained by recent improvements in the preoperative diagnostic devices as well as increase of surgical indications and more extensive histological examination of thyroid lesions (5, 6).

According to the World Health Organization (WHO) definition, published in 2004, papillary thyroid microcarcinoma (PTMC) is defined as a papillary carcinoma, often not detectable in clinical examination, that is found incidentally, with a tumor size ≤ 1 cm (7). Incidental papillary microcarcinoma has a relatively good prognosis, with a 10-years disease-free survival (DFS) rate is over 90% (8-10) (96.6% in the series of Ito et al.) (1). According to different Authors, the reported rates of recurrence (in the lymph nodes, in the residual parenchyma, or distant metastases) and cancer-related mortality are respectively 1.7-6% and 0.2-2% (1,8-10). A subgroup of PTMC, designated as papillary microtumor (PMiT) by Rosai et al (11), is likely to have a favourable biological behavior similar to that of clinical benign thyroid diseases.

In the present study we retrospectively review the data of patients operated for benign thyroid diseases in our center, with the aim to assess the frequency of incidental thyroid cancer, to characterize the lesions, to evaluate the role of preoperative ultrasound pattern as predictive factor of presence of ITC, to examine possible associations among histopathologic variables, to discuss the role of total thyroidectomy without residuum in the patients with benign thyroid disease.

Patients and methods

Between January 2001 and December 2009, we consecutively operated 646 patients for thyroid disease. The patients were referred to our center both from the Division of Endocrinology of our Hospital and from other hospitals in the territory. We excluded patients with undetermined or positive for malignancy preoperative cytology (Thy 3-5 according to the *British Thyroid Association Thyroid FNAC Reporting Guidelines*) (12). Of the total, 568 patients underwent surgery for presumably benign disease. The population consisted of 477 women and 91 men, with a mean age of 56.4 years (range 21-82 years). Of these 568 patients, 92 (16.2%) had preoperative fine-needle aspiration cytology (FNAC) with Thy2 result, while 476 patients (83.8%) did not underwent FNAC or had Thy1 and refused to repeat the aspiration. The surgical indications were divided as follows: multinodular or diffuse nontoxic goiter (334), multinodular or diffuse toxic goiter (127), uninodular nontoxic goiter (52), uninodular toxic goiter (55). The surgical procedures were total thyroidectomy in 499 cases and emithyroidectomy in 69 cases.

We determined the frequency of ITC in our series, describing the main histopathologic features of the tumors and the relation with surgical indication. We examined the presence of association among histopathologic variables were computed by χ^2 test, Kendall's τ and Spearman's r , Kruskal-Wallis test. The follow-up was performed according the criteria of *European Thyroid Cancer Taskforce* (15). The disease-free rate was evaluated using Kaplan-Meier statistical analysis. Statistical analysis was carried out using STATA 8.0 statistical software.

This study is conducted in accordance with the principles of the Declaration of Helsinki and 'good clinical practice' guidelines. All patients provided informed consent to the operative treatment, the administration and further analyses of data from their medical records. The hospital ethical committee approved the analysis of these data.

Results

Final histology revealed ITC in 53 patients (9.3%). This group included 46 women and 7 men with a mean age of 56.7 years (range 25-82 years); 12 patients were younger than 45 years of age at the time of diagnosis, whereas 41 patients were 45 years or older. Of the 53 patients, 8 (15.1%) had preoperative FNAC with Thy2 result, while 45 patients did not underwent FNAC or had Thy1 result. Surgical procedures were: total thyroidectomy in 46 cases (86.8%), emithyroidectomy in 4 patients (7.6%) with past history of lobectomy, emithyroidectomy

TABLE 1 - RELATIVE INCIDENCE OF ITC IN DIFFERENT BENIGN THYROID DISEASES.

Thyroid pathology	Cancer incidence with regard to the indications for surgery, n/total (%)
Multinodular or diffuse nontoxic goiter	31/334 (9.28)
Multinodular or diffuse toxic goiter	14/127 (11.02)
Uninodular nontoxic goiter	3/52 (5.77)
Uninodular toxic goiter	5/55 (9.09)
<i>Total</i>	<i>53/568 (9.3)</i>

with following radicalization and central neck dissection in 3 patients (5.7%). In case of total thyroidectomy, preoperative diagnosis was multinodular or diffuse nontoxic goiter in 28 cases, multinodular or diffuse toxic goiter in 13 cases, uninodular nontoxic goiter in 2 cases, uninodular toxic goiter in 3 cases. In case of emithyroidectomy with following radicalization the indication was uninodular nontoxic goiter in one case, uninodular toxic goiter in 2 cases. In the patients with past lobectomy the indication was multinodular or diffuse nontoxic goiter in all cases. The mean weight of the specimen was 48.87 g (range 14-264 g). The relation between surgical indications and diagnosis of ITC is detailed in Table 1. The rate of ITC was 10.4% in toxic disease versus 8.8% in nontoxic disease and 9.8% in multinodular or diffuse goiter versus 7.5% in uninodular goiter. These differences were not significant using a χ^2 test (respectively, $P=0.2664$ and $P=0.2321$). Final histology is shown in Table 2. In 14 patients (26.42%) the tumor was multifocal and in 12 of these patients the tumor foci were bilateral (22.64% of the total and 85.71% of multifocal cases). The lesion was a microcarcinoma in 34 cases (32 patients with a PTMC and 2 patients with diagnosis of medullary carcinoma of less than 1 cm in diameter). In 23 cases (43.40% of 53 patients and 67.65% of microcarcinomas) the lesions met the Porto Proposal criteria (11). In 2 patients (3.77%) the thyroid capsule was infiltrated by the tumor. Other histopathologic characteristics were: vascular invasion (1 case, 1.89%), invasion of the tumoral capsule in the cases of encapsulated variant (5 cases, 9.43%), tall cells features (2 cases, 3.77%). Other associated pathologic pictures were: lymphocytic thyroiditis (5 cases, 9.43%), Hürthle cell adenoma (3 cases, 5.66%), De Quervain thyroiditis (1 case, 1.89%). Mean diameter of the lesions was 1.14 cm (range 0.1-4.5 cm). Excluding the primitive paraganglioma, the TNM staging, following, the 7th edition of International Union Against Cancer/American Joint Committee on Cancer (UICC/AJCC) (13), yielded 44 patients with stage 1 disease (84.62%), 6 patients with stage 2 disease (11.54%), 2 patients with stage 3 disease (1.92%). One of the patients operated in two times had micrometastases in one lymph node of the central compartment. The correlation between preoperative dia-

TABLE 2 - HISTOLOGY IN PATIENTS WITH INCIDENTAL THYROID CARCINOMA.

Histology	n	%	Cumulative %
Papillary carcinoma classic variant	20	37.74	37.74
Papillary carcinoma follicular variant	24	45.28	83.02
Follicular carcinoma	3	5.66	88.68
Follicular carcinoma + PTMC*	1	1.89	90.57
Medullary carcinoma	4	7.55	98.12
Paraganglioma	1	1.89	100

* PTMC: papillary thyroid microcarcinoma

gnosis and all histopathologic variables was not statistically significant.

We retrospectively reconsidered the results of preoperative ultrasound examinations in relation to the exact position of the tumor in the specimens and according to three main parameters: echogenicity, microcalcifications and vascularisation (14). The results are resumed in Table 3. We found a statistically significant association between echogenicity and papillary histotype ($P=0.015$). We also considered the possible associations among all histopathologic variables. We found a significant correlation between tumor diameter and invasion of the tumor capsule (in the encapsulated variant, $P=0.0082$). Moreover we observed that single lesions were most frequently observed in larger specimens (mean weight 55.5 g), while multifocality was more characteristic of small thyroid (29.4 g). This difference was statistically significant ($P=0.0338$). The explanation of statistically significant correlation between histotype and stage ($P=0.012$) is intuitive, being the majority of stage 1 lesions a papillary tumor.

Twenty-six patients (49%) were followed up at the Division of Endocrinology of our Hospital, according to the *European Thyroid Cancer Taskforce* criteria (15). The mean follow-up period was 38.2 months (range 6 – 124 months). In 6/26 cases (23.1%) an ultrasound residuum was present (mean diameter 11.2 mm, range 6

TABLE 3 - ULTRASOUND FEATURES OF THYROID PARENCHYMA IN RELATION TO THE EXACT SITE OF TUMOR ON THE SPECIMEN.

Preoperative ultrasound features		%
Echogenicity	hypoechoogenicity	53.85
	isoechogenicity	7.69
	anechogenicity	7.69
	mixed iso-hypoechoogenicity	30.77
Microcalcification	present	91.67
	absent	8.33
Vascularization	absent	11.11
	peripheral	66.67
	intra-perilesional	22.22

– 22 mm). The radiometabolic therapy was performed in 9/26 patients (34.6%). The scintigraphic residuum after therapy with I_{131} was present in 11/26 patients (42.3%). The captation was usually minimal. A relapse was observed in 3/26 patients (11.5%). The relapse was local in 2 cases and nodal in 1 case. The primitive tumor was papillary in 2 cases and follicular in 1 case, with a mean diameter of 2.15 cm. Figure 1 indicates the disease-free survival (DFS) of patients with incidental thyroid cancer.

Discussion

In our experience, in the 9.3% (n=53) of patients operated for benign thyroid disease final histology revealed

an incidental cancer. Our data are confirmed by the Literature. In the 64% (n=34) of cases the lesion was a microcarcinoma. The most represented histologic variant was the papillary one. Despite papillary microcarcinomas are usually considered to have a good prognosis and a favourable clinical course, there is a possibility of local and nodal recurrence, with a cancer-related mortality rate of 0.2-2% (1,8-10). Moreover, although the large majority of patients had a stage 1 lesion, in the 15% of cases the tumors had a diameter superior to 2 cm, in two cases the thyroid capsule was infiltrated and one patients presented nodal micrometastases. These data suggest that ITC is not an irrelevant nosologic entity. We also must consider that, in addition to the papillary variant, other histotypes with worse prognosis could be represented. In our series we describe four follicular tumors, four medullary tumors and one paraganglioma. The follicular tumors were stage 1 in one case, stage 2 in two cases and stage 3 in one case. We found four cases of medullary carcinoma in patients without preoperative measurement of serum calcitonin. The fall in preoperative identification of medullary tumors could also be related to the small size of the lesions. All medullary tumors were stage 1 lesions, with a mean diameter of 0.8 cm (range 0.5 - 1.2). Primary paragangliomas of the thyroid are very rare neuroendocrine tumours. Very few cases have been reported in the Literature [16]. They are endocrinologically silent, and the diagnosis could be difficult. Due to the potentially malignant behaviour of these lesions, we assume that they could be included in the differential diagnosis of thyroid tumors. In 2003, Rosai et al proposed the term “papillary microtumor of the thyroid” (PMiT) to define a subset of tumors that is likely to have

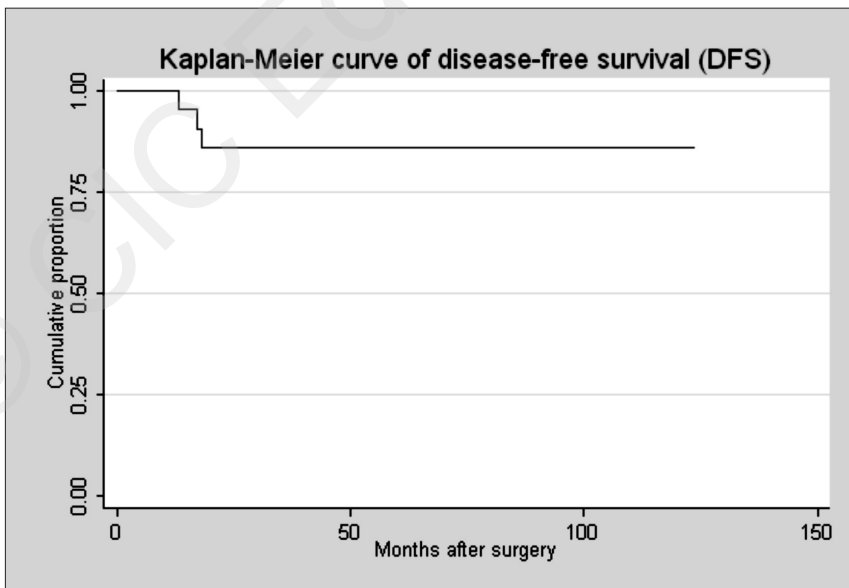


Fig. 1 - Kaplan-Meier curve of disease-free survival (DFS) of patients with incidental thyroid cancer.

a benign biological behaviour (11). We retrospectively reviewed our histological findings according to these criteria (the “Porto proposal” criteria) and we found that they were respected in 23 cases. As suggested by Asioli et al. (5), this terminology is still not largely employed. We assume that a systematic use of these criteria will help to better understand the clinical behaviour and prognosis of this class of lesions.

The retrospective analysis of our series revealed that only 16.2% (n=92) of patients operated for presumably benign disease had a Thy2 preoperative cytology. The majority of patients didn't undergo FNAC, while a very small number of patients had a Thy1 result and refused to repeat the examination. These data could suggest that we underused FNAC. Anyway we still must consider that patients were often sent from other hospitals with a precise indication for surgery, and the organization of a new preoperative diagnostic *iter* could have been difficult. Of 92 Thy2 patients, 8.7% (n=8) had final diagnosis of ITC. Seven patients were stage 1 and one patient was stage 2 (4 with a microcarcinoma). The mean diameter of the tumors was 1.5 cm (range 0.5 – 4.5); the patient with the 4.5 cm lesion was 25 years old and was considered stage 2. According to different series, the reported false-negative rate in FNAC of the thyroid gland is usually between 0.5 and 11.5% (17-19). In consideration that we are now presenting a series of purely incidental cancers, we believe that the percentage of false negative we have presented could be considered completely justifiable. Through the analysis of ultrasound results, we could also confirm that neoplastic lesions are particularly well represented by hypoechogenicity. We suggest to better investigate the possible role of hypoechogenicity as a predictive factor in the preoperative assessment of benign thyroid disease. We believe that the finding of hypoechogenic areas, in particular with microcalcification, should always induce to perform a FNAC, with a careful selection of nodules to aspire on the basis of ultrasonographic pattern and multiple punctures in case of large nodules, as suggested by Miccoli et al. (2).

According to histopathologic findings and clinical features, our population of patients with ITC presented some peculiar characteristics: a large number of follicular variant cases (n=24) versus the classic variant of the papillary tumors (n=20); the inverse correlation between weight of the specimen and multifocality; a particularly elevated mean age at diagnosis (56.7). According to the functional status of the thyroid, Miccoli et al. (2) describe a significantly more elevated incidence of ITC in nontoxic thyroid disease versus toxic thyroid disease. Although not significant, our results were contrasting, with a rate of ITC of 10.4% in toxic disease versus 8.8% in nontoxic disease. We assume that the explanation of these observations could be found in the high prevalence of endemic goitre in our region. The introduction of sy-

stematic iodine supplements could represent a chronic irritative stimulus, altering the common presentation of tumors. The retrospective review of the histopathologic results in our series revealed only 5 cases of lymphocytic thyroiditis and one case of De Quervain thyroiditis. We assume that a revision of sections with specific intention to examine the inflammation could reveal a more elevated percentage of cases of thyroiditis.

When considering surgical approach, total thyroidectomy is the most represented procedure. On the total of 53 patients with ITC we performed 46 total thyroidectomy, 3 emithyroidectomy with following radicalization and central neck dissection and 4 emithyroidectomy in patients with past history of lobectomy. Eight patients had preoperative diagnosis of uninodular goiter and 5 of them underwent total thyroidectomy. In 2 cases of uninodular nontoxic goiter the ITC was multifocal and bilateral. Bradly et al. (6) observed an incidental papillary carcinoma in 40% of patients with follicular adenoma. The tumor was contralateral to the adenoma in a large number of cases. The Authors concluded that lobectomy could be an inadequate procedure for follicular adenoma and that total thyroidectomy could be performed in case of intraoperative detection of contralateral abnormalities (6). Sakorafas et al. (20) suggest total or near-total thyroidectomy in the management of nodular thyroid disease. Despite controversy and as well acknowledging that this remains a controversial issue, we consider total thyroidectomy without residuum as the procedure of choice, in order to reduce recurrences, avoid the risk of reoperation and eliminate the possibility of multifocality. The data reported by Efreimidou et al. (21) support that total thyroidectomy can be performed safely with a low complication rate. As suggested by Sakorafas (20), we remark that total thyroidectomy in particular creates some advantages in monitoring of patients during the follow-up period, with particular regard to scintigraphic scan and thyroglobulin measurement, and in case of postoperative radioactive iodine therapy. In case of diagnosis of ITC after lobectomy, we suggest radicalization with central neck dissection. We assume that a more extensive use of “Porto proposal” criteria will confirm if a less aggressive approach could be considered justified in papillary microtumors.

Conclusions

The review of Literature and analysis of our experience confirm that incidental thyroid cancer in patients operated for benign disease has its own surgical significance and oncological relevance. A correct preoperative assessment, with a careful selection of nodules for fine-needle aspiration cytology on the basis of ultrasound pattern, could better address the choice of surgical proce-

ture. The non irrelevant incidence of incidental thyroid cancer, the eventuality of multifocality and bilaterality and the possible occurrence of relapse, support that total thyroidectomy without residuum is a valuable option for treating benign thyroid conditions such as multinodular goitre. When an incidental cancer is diagnosed after emithyroidectomy, a radicalization with central neck dissection could be considered. We suggest that natural history of papillary microtumors and the correct surgical approach for these lesions could be better defined with a more extensive use of "Porto proposal" criteria.

References

1. Ito Y, Higashiyama T, Takamura Y, Miya A, Kobayashi K, Matsuzuka F, Kuma K, Miyauchi A. Prognosis of patients with benign thyroid disease accompanied by incidental papillary carcinoma undetectable on preoperative imaging tests. *World J Surg* 2007;31:1672-6.
2. Miccoli P, Minuto MN, Galleri D, D'Agostino J, Basolo F, Antonangeli L, Aghini-Lombardi F, Berti P. incidental thyroid carcinoma in a large series of consecutive patients operated on for benign thyroid disease. *ANZ J Surg* 2006;76:123-6.
3. Trimboli P, Ulisse S, Graziano FM, et al. Trend in thyroid carcinoma size, age at diagnosis, and histology in a retrospective study of 500 cases diagnosed over 20 years. *Thyroid* 2006;16:1151-1155.
4. Lin JD, Chao TC, Weng HF, Huang HS, Ho YS. Clinical presentation and treatment for 74 occult thyroid carcinoma. Comparison with nonoccult thyroid carcinoma in Taiwan. *Am J Clin Oncol* 1996;19:504-8.
5. Asioli S, Odasso C, Macrì L, Palestini N, Bussolati G. Merits of the PMiT (Papillary Microtumor) Terminology in the Definition of a Subset of Incidental Papillary Microcarcinomas of the Thyroid. *Int J Surg Pathol* 2009;17:378-83.
6. Bradly DP, Reddy V, Prinz RA, Gattuso P. Incidental papillary carcinoma in patients treated surgically for benign thyroid disease. *Surgery* 2009;146:1099-104.
7. DeLellis RA, Lloyd RV, Heitz PU, Eng C, eds. *Pathology and Genetics: Tumours of Endocrine Organs*. Lyon, France: IARC Press; 2004.
8. Ito Y, Miyauchi A. A therapeutic strategy for incidentally detected papillary microcarcinoma of the thyroid. *Nat Clin Pract Endocrinol Metab* 2007;3:240-8.
9. Chow SM, Law SC, Chan JK, Au SK, Yau S, Lau WH. Papillary microcarcinoma of the thyroid-Prognostic significance of lymph node metastasis. *Cancer* 2003;98:31-40.
10. Mazzaferri EL. Management of low-risk differentiated thyroid cancer. *Endocr Pract* 2007;13:498-512.
11. Rosai J, LiVolsi VA, Sobrinho-Simoes M, Williams ED. Renaming papillary micro-carcinoma of the thyroid gland: the Porto proposal. *Int J Surg Pathol* 2003;11:249-51.
12. British Thyroid Association, Royal College of Physicians: British Thyroid Association Guidelines for the management of thyroid cancer. 2nd edition. 2007 [<http://www.british-thyroid-association.org/Guidelines/>].
13. Edge SB, Byrd DR, Carducci MA, et al, eds. *American Joint Committee on Cancer (AJCC) Cancer Staging Manual*. 7th ed. New York: Springer; 2009.
14. Mandel SJ. Diagnostic use of ultrasonography in patients with nodular thyroid disease. *Endocr Pract* 2004;10:246-52.
15. Pacini F, Schlumberger M, Dralle H, Elisei R, Smit JW, Wiersinga W. European Thyroid Cancer Taskforce. European consensus for the management of patients with differentiated thyroid carcinoma of the follicular epithelium. *Eur J Endocrinol* 2006;154:787-803.
16. Ferri E, Manconi R, Armato E, Ianniello F. Primary paraganglioma of the thyroid gland: a clinicopathologic and immunohistochemical study with review of the literature. *Acta Otorhinolaryngol Ital* 2009;29:97-102.
17. Walsh RM, Watkinson JC, Franklyn J. The management of the solitary thyroid nodule: a review. *Clin Otolaryngol* 1999;24:388-97.
18. Belfiore A, La Rosa GL. Fine-needle aspiration biopsy of the thyroid. *Endocrinol Metab Clin North Am* 2001;30:361-400.
19. Hossein G, Goellner JR. *Fine Needle Aspiration Biopsy of the thyroid gland*. Randolph Surgery of the thyroid and parathyroid glands. Saunders 2003.
20. Sakorafas GH, Stafyla V, Kolettis T, Tolumis G, Kassaras G, Peros G. microscopic papillary thyroid cancer as an incidental findings in patients treated surgically for presumably benign thyroid disease. *J Postgrad Med* 2007;53:23-6.
21. Efreimidou EI, Papageorgiou MS, Liratzopoulos N, Manolas KJ. The efficacy and safety of total thyroidectomy in the management of benign thyroid disease: a review of 932 cases. *Can J Surg*. 2009 Feb;52(1):39-44.