

Laparoscopic-endoscopic *rendez-vous* resection of iuxta-cardial gastric GIST

R. VECCHIO, S. MARCHESE, F.F. AMORE, F. LA CORTE, F. FERLA, L. SPATARO, E. INTAGLIATA

SUMMARY: Laparoscopic-endoscopic *rendez-vous* resection of iuxta-cardial gastric GIST.

R. VECCHIO, S. MARCHESE, F.F. AMORE, F. LA CORTE, F. FERLA, L. SPATARO, E. INTAGLIATA

Gastrointestinal stromal tumors (GISTs) are the most common mesenchymal tumors of the gastrointestinal tract and they often require a surgical removal. Gastrointestinal stromal tumors can originate from

any part of the gastrointestinal tract but gastric location is the most common. In the past the risk of rupture of pseudocapsula and peritoneal dissemination have discouraged surgeons from making a minimally invasive surgical treatment. Recently laparoscopic wedge resection has been proposed. Performance of this mini-invasive technique is however difficult in some gastric location of gastrointestinal stromal tumors, such as iuxta-cardial region. The Authors report and discuss a new technique they used to remove a gastrointestinal stromal tumor located just below the cardia, using a rendez-vous endoscopic and laparoscopic technique.

KEY WORDS: Gastric GIST - Laparoscopic-endoscopic resection.

Introduction

Intramural mesenchymal tumors of the gastro-intestinal tract, (classified as gastrointestinal stromal tumors (GIST) with *c-kit* antigenic mutation, GIST without mutation, true smooth muscle tumors and true Schwann cell tumors) (1), are rare neoplasms which need surgical removal because of their potential malignity. These tumors may develop anywhere along the gastrointestinal tract, but the stomach represent the most common site (1-4). Laparoscopic surgery for removal of gastric GISTs has been proposed (5-11). Laparoscopic wedge resection has been the most common procedure performed (8,9,12). Gastric tumors located near the esophago-gastric junction, however, are difficult to remove by laparoscopic techniques (12). The Authors report a case of iuxta-cardial gastric GIST treated by a *rendez-vous* laparoscopic-endoscopic technique.

Case report

The patient, a 66 years old white female, complained in the last year epigastric pain, dyspepsia and heartburn. Upper endoscopy revealed esophagitis, sliding hiatal hernia and an intramural tumor located just below the Z-line. Endoscopic ultrasound confirmed the intramural location of the iuxta-cardial tumor, which was homogeneous, entirely located in the submucosal layer and measuring about 2 cm in diameter (Figure 1). Reflux esophagitis with hypotonic LES was demonstrated with 24-hours esophageal pH-manometry. The patient was then scheduled for excision of the intramural gastric tumor and laparoscopic antireflux surgery.

Through an Hasson trocar inserted in the epigastric area and other two 5-mm trocars positioned in the subcostal regions, the mobilization of the esophago-gastric junction was accomplished. Then, two 5-mm radially expandable trocars were inserted through the abdominal and gastric walls and a 5 mm 30° scope was introduced into the gastric lumen. Through insufflations of the gastric cavity, an endoscopic polypectomy snare introduced per mouth, was maneuvered by an endoscopist who grasped and tractioned the gastric iuxta-cardial lesion (Figure 2).

An harmonic scalpel device inserted through the other 5 mm laparoscopic trocar was used to remove the gastric tumor with a submucosal resection. The resection of the lesion was accomplished thanks to the traction made by the endoscopist through the polypectomy snare which allowed an excellent exposure of the site of dissection. This laparoscopic-endoscopic *rendez-vous* technique made possible a complete resection of the submucosal GIST, which otherwise could have been more challenging and with intraoperative risks of complications (such as perforation), considering the iuxta-cardial location of the tumor. The specimen was then pulled

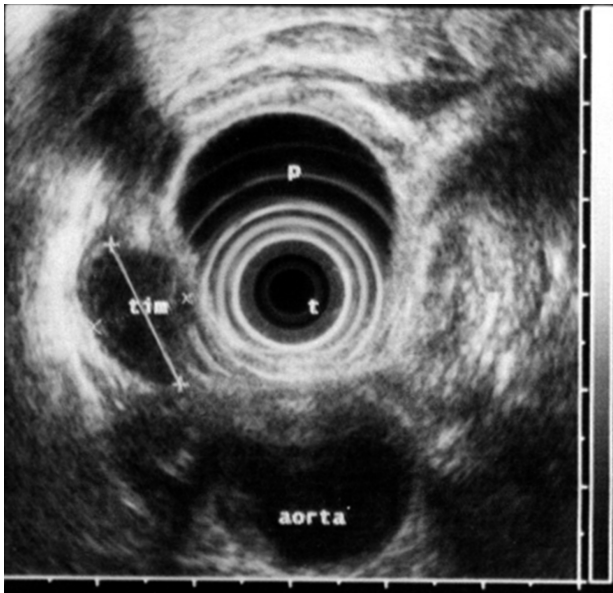


Figure 1 - Ultrasound appearance of iuxta-cardial gastric GIST.

away from the mouth after its introduction in a small plastic bag.

After withdrawal of the expandable trocars and closure of the gastric holes with monofilament non-absorbable sutures, an antireflux floppy Nissen-Rossetti procedure was performed. Performing a “floppy” Nissen allowed us not to use a dilator to calibrate the wrap, which could have led to a threatening risk of perforation of the iuxta-cardial region, in the site of the previous surgical dissection. The naso-gastric tube was left in place.

Post-operative phase was uneventful. The patient passed gas in day one p.o. and started feeding in the same day, after gastrografin X-ray examination and removal of the nasogastric tube. He was discharged from the hospital in day 4 p.o. In a 5 years follow-up with clinical observation, endoscopic and CT scan examinations performed every six months for two years and then yearly, neither complaints nor disease recurrence were observed.

Pathologic examination confirmed the diagnosis of gastric GIST. The tumor was limited to the submucosa and the resection margins were disease-free. Immunohistochemical analysis revealed the CD117 positivity.

Discussion

The incidence of GISTs is estimated to be 1,5-2 cases per 100.000 inhabitants each year (1-3,13). They usually are observed in patients in the 5th - 6th decade of life. The mean age at the diagnosis is 55-63 years (1,13). However, it is estimated, that about 20% of the tumors manifest themselves in patients below 40 years of age (2,3). The majority of GISTs are located in the gastrointestinal tract and the most common site of onset is the stomach (50-60% of the cases) (1-4).

The clinical presentation is not characteristic and depends on the localization and size of the tumor (1,7,14). The most common symptoms and signs are abdominal pain (57-74%), early satiety, subileus or ileus (30-44%), prolonged gastrointestinal bleeding (44-70%), weight loss (16-22%), palpable abdominal mass (16%), perforation with peritonitis (9-11%) (1,2,15).

First-level diagnostic procedures are ultrasound, gastrointestinal x-ray and endoscopy (6,12). Endoscopic ultrasound (6,14,15), CT and MRI (2,6,16) are important diagnostic tools in GISTs that extend in the wall of gastrointestinal tract toward the serosal surface.

However, the final diagnosis is established on the basis of histological examination of the surgical specimen (1,2,6,12). Even if the gastric stromal tumor is usually at low risk for malignancy, standard treatment of located GIST is complete surgical excision (R0), without dissection of clinically negative lymph nodes (6). Surgical techniques adopted depend on place of occurrence and tumor size (1). Benign or low malignant potential, limited disease, small lesions (T<5 cm in diameter) located in easily accessible sites of the stomach can be treated with limited resections that can also be performed by endoscopic and/or laparoscopic approaches (6,8,9,16,17).

Endoscopic enucleation of gastric submucosal tumors has been reported by many authors (18-20). In their se-

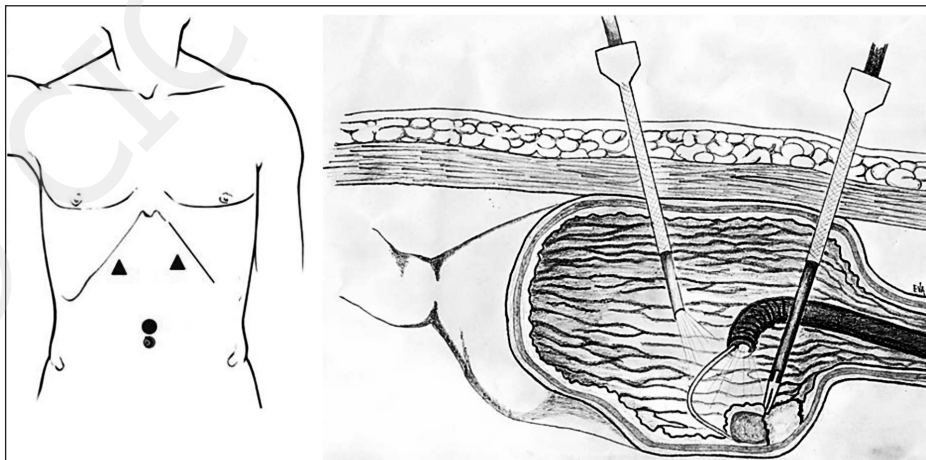


Figure 2 - Position of the two 5-mm expandable trocars and exposure of the dissection plane through the traction of the GIST with the endoscopic grasping.

ries, small gastric GISTs have been treated through endoscopic resection with no serious postoperative complications. However, this approach is challenging and many times technically impossible to perform in iuxta-cardial location of the GIST. Moreover, is not indicated in large tumors or if involvement of the muscularis propria is suspected in the preoperative endoscopic ultrasonography, because the risk of an uncompleted removal of the tumor (10,18-20).

Laparoscopic wedge resection has also been performed for the removal of gastric GIST (11).

As in other laparoscopic technique, the laparoscopic approach is of great advantage over the open techniques, since it induces less post-operative coagulative and metabolic changes (21-24), and can be performed in elderly patients (25, 26) who could benefit from the invasive approach.

In the iuxta-cardial location, as mentioned above for the endoscopic removal, the laparoscopic extra-gastric technique is however difficult to perform (10,12), with an increased risk of post-operative leaking.

In a leiomyoma located in the esophago-gastric junction Taniguchi et al. (10) performed successfully the first laparoscopic intragastric operation with complete excision of the large tumor. In their technique the gastric tumor was removed through 3 trocars (one 12 mm and two 5 mm trocars) inserted through the abdominal and gastric walls. Our technique differs from the other laparoscopic intragastric techniques since we inserted only two 5 mm laparoscopic trocars in the gastric lumen, and suspension of the tumor was accomplished through a grasper inserted and manipulated by an endoscopist who

helped us in the intraoperative exposure dissection of the tumor from the submucosa.

With the technique proposed in the study, trauma on the stomach was minimized and risk of intra-operative or post-operative complications, such as perforation and leaking, are reduced, compared to other laparoscopic techniques. Using this technique, oncologic results for small GIST located in the submucosal layer can also be accomplished.

Conclusion

The technique described in this study is easy to perform and can be reproduced by any experienced laparoscopic team. It allows all the advantages of the laparoscopic surgery and it follow, at the same time, the principles of oncologic surgery (7-9,14). This approach is especially indicated in tumors located near the cardias, where endoscopic removal or laparoscopic wedge resection is difficult or impossible to perform (10). The *rendez-vous* technique, as performed in this study, allows a better exposure of the submucosal layer and a more accurate dissection of the GIST (7,17). In addition, this allows a decreased risk of post-operative leaking from the site of operation or from the gastric laparoscopic holes, which are reduced in number and size compared to other intragastric similar technique reported in the Literature (10). The Authors suggest this technique in tumors located near the cardia, which are thought to be benign at the preoperative work up.

References

1. De Silva CM, Reid R. Gastrointestinal stromal tumors (GIST): C-kit mutations, CD117 expression, differential diagnosis and target cancer therapy with Imatinib. *Pathol Oncol Res* 2003;13:9. Epub 2003 Apr 18.
2. Cichoż Lach H, Kasztelan Szczerbińska B, Słomka M. Gastrointestinal stromal tumors: epidemiology, clinical picture, diagnosis, prognosis. *Pol Arch Med Wewn* 2008 Apr;118(4):216-21.
3. Miettinen M, Lasota J. Gastrointestinal stromal tumors-definition, clinical, histological, immunohistochemical, and molecular genetic features and differential diagnosis. *Virchows Arch* 2001 Jan;438(1):1-12.
4. Kim HC, Lee JM, Kim SH, Kim KW, Lee M, Kim YJ, Han JK, Choi BI. Primary gastrointestinal stromal tumors in the omentum and mesentery: CT findings and pathologic correlations. *AJR Am J Roentgenol* 2004 Jun;182(6):1463-7.
5. Berindoague R, Targarona EM, Feliu X, Artigas V, Balagué C, Aldeano A, Lahoud A, Navines J, Fernandez-Sallent E, Trias M. Laparoscopic resection of clinically suspected gastric stromal tumors. *Surg Innov* 2006 Dec;13(4):231-7.
6. P. G. Casali & J. -Y. Blay. Gastrointestinal stromal tumours: ESMO Clinical Practice Guidelines for diagnosis, treatment and follow-up. *Ann Oncol* 2010 May;21 Suppl 5:v98-102.
7. Rohatgi A, Singh KK. Laparoendoscopic management of gastrointestinal stromal tumors. *J Laparoendosc Adv Surg Tech A* 2003 Feb;13(1):37-40.
8. Granger SR, Rollins MD, Mulvihill SJ, Glasgow RE. Lessons learned from laparoscopic treatment of gastric and gastroesophageal junction stromal cell tumors. *Surg Endosc* 2006 Aug;20(8):1299-304. Epub 2006 Jul 24.
9. Catena F, Di Battista M, Fusaroli P, Ansaloni L, Di Scioscio V, Santini D, Pantaleo M, Biasco G, Caletti G, Pinna A. Laparoscopic treatment of gastric GIST: report of 21 cases and literature's review. *J Gastrointest Surg* 2008 Mar;12(3):561-8. Epub 2007 Nov 27. Review.
10. Taniguchi E, Kamiike W, Yamanishi H, Ito T, Nezu R, Nishida T, Momiyama T, Ohashi S, Okada T, Matsuda H. Laparoscopic intragastric surgery for gastric leiomyoma. *Surg Endosc* 1997 Mar;11(3):287-9.
11. Yamashita Y, Bekki F, Kakegawa T, Umetani H, Yatsuka K. Two

- laparoscopic techniques for resection of leiomyoma in stomach. *Surg Laparosc Endosc* 1995;5:38-42.
12. Ludwig K, Wilhelm L, Scharlau U, Amtsberg G, Bernhardt J. Laparoscopic-endoscopic rendez-vous resection of gastric tumors. *Surg Endosc* 2002;16:1561-1565.
 13. Nilsson B, Bümbling P, Meis-Kindblom JM, Odén A, Dortok A, Gustavsson B, Sablinska K, Kindblom LG. Gastrointestinal stromal tumors: the incidence, prevalence, clinical course, and prognostication in the preimatinib mesylate era--a population-based study in western Sweden. *Cancer* 2005 Feb 15;103(4):821-9.
 14. Seelig MH, Hinder RA, Floch NR, Klingler PJ, Seelig SK, Branton SA, Woodward TA. Endoorgan and laparoscopic management of gastric leiomyomas. *Surg Laparosc Endosc* 1999 Jan;9(1):78-81.
 15. Brand B, Oesterhelweg L, Binmoeller KF, Sriram PV, Bohnacker S, Seewald S, De Weerth A, Soehendra N. Impact of endoscopic ultrasound for evaluation of submucosal lesions in gastrointestinal tract. *Dig Liver Dis* 2002 Apr;34(4):290-7.
 16. Hwang SH, Park do J, Kim YH, Lee KH, Lee HS, Kim HH, Lee HJ, Yang HK, Lee KU. Laparoscopic surgery for submucosal tumors located at the esophagogastric junction and the prepylorus. *Surg Endosc* 2009 Sep;23(9):1980-7. Epub 2008 May 10.
 17. Ridwelski K, Pross M, Schubert S, Wolff S, Günther T, Kahl S, Lippert H. Combined endoscopic intragastral resection of a posterior stromal gastric tumor using an original technique. *Surg Endosc* 2002 Mar;16(3):537. Epub 2002 Jan 9.
 18. Katoh T, Itoh Y, Mohri T, Suzuki H. Endoscopic enucleation of gastrointestinal stromal tumors of the stomach: report of five cases. *World J Gastroenterol* 2008 Apr 28;14(16):2609-11.
 19. Park YS, Park SW, Kim TI, Song SY, Choi EH, Chung JB, Kang JK. Endoscopic enucleation of upper-GI submucosal tumors by using an insulated-tip electro-surgical knife. *Gastrointest Endosc* 2004; 59:409-415.
 20. Rosch T, Sarbia M, Schumacher B, Deinert K, Frimberger E, Toerner T, Stolte M, Neuhaus H. Attempted endoscopic en bloc resection of mucosal and submucosal tumors using insulated-tip knives: a pilot series. *Endoscopy* 2004;36:788-801.
 21. Vecchio R, Cacciola E, Cacciola RR, Marchese S, Intagliata E. Portal vein thrombosis after laparoscopic and open splenectomy. *J Laparoendosc Adv Surg Tech A* 2011 Jan-Feb;21(1):71-5. Epub 2010 Dec 29.
 22. Vecchio R, MacFadyen BV. Laparoscopic common bile duct exploration. *Langenblocks Arch Surg* 2002;387(1):45-54.
 23. Vecchio R, Cacciola E, Martino M, Cacciola RR, MacFadyen BV. Modifications of coagulation and fibrinolytic parameters in laparoscopic cholecystectomy. *Surg Endosc* 2003 Mar;17(3):428-33. Epub 2002 Dec 4.
 24. Vecchio R, Marchese S, Intagliata E, Swehli E, Ferla F, Cacciola E. Long-term results after splenectomy in adult idiopathic thrombocytopenic purpura: comparison between open and laparoscopic procedures. *J Laparoendosc Adv Surg Tech* 2013;23(3):192-8.
 25. Barbaros U, Dinççağ A, Sümer A, Vecchio R, Rusello D, Randazzo V, Issever H, Avei C. Prospective randomized comparison of clinical results between hand-assisted laparoscopic and open splenectomies. *Surg Endosc* 2010;24(1):25-32.
 26. Vecchio R, Marchese S, Swehli E, Intagliata E. Splenic hilum management during laparoscopic splenectomy. *J Laparoendosc Adv Surg Tech* 2011;11:717-20.