

## Circumscribed myositis ossificans of the masseter muscle: report of a case

P. PIOMBINO<sup>1</sup>, G. DELL'AVERSANA ORABONA<sup>2</sup>, V. ABBATE<sup>3</sup>,  
G. FINI<sup>4</sup>, G.M. LIBERATORE<sup>5</sup>, E. MICI<sup>6</sup>, E. BELLI<sup>7</sup>

**SUMMARY:** Circumscribed myositis ossificans of the masseter muscle: report of a case.

P. PIOMBINO, G. DELL'AVERSANA ORABONA, V. ABBATE, G. FINI,  
G.M. LIBERATORE, E. MICI, E. BELLI

*Myositis Ossificans (MO) is an unusual pathological entity still largely unknown, characterized by dystrophic calcification leading to heterotopic ossification of intramuscular connective tissue. The masticatory muscles are exceptionally involved.*

*Four distinct types of myositis ossificans have been described: MO Progressiva, which is a genetic disorder involving several muscular groups; MO Circumscripta, limited to a single muscle and generally due to calcification of an intramuscular haematoma following severe trauma and progressive ossification; MO Pseudo-malignant limited to soft tissue and not associated to any trauma; MO associated to paraplegia.*

*A case of circumscribed myositis ossificans of the masseter muscle in a 62 years-old woman is reported.*

KEY WORDS: Myositis ossificans - Circumscribed Myositis Ossificans - Masseter muscle.

### Introduction

Myositis ossificans (MO) is a non neoplastic lesion, localised, self limiting, characterised by a more or less wide bone production from interstitial connective tissue. It involves muscles and only rarely tendons, ligaments, periosteum and subcutaneous fat tissue (1).

MO includes four distinct clinical pathologies:

1. Circumscribed or traumatic MO indicates bone metaplasia in a muscle, when in the clinical history there is a report of a trauma, in which the intramuscular haemorrhage causes a bone metaplasia. It can be due also to repeated microtraumas and/or inflammatory disease. It generally involves the lateral pterygoid

muscle (2) and medial pterygoid muscle (3) and only rarely the masseter muscle.

2. MO Progressiva also called fibrodysplasia ossificans progressiva, is an autosomal dominant disease of the pediatric age, more frequent in females; characterized by symmetric skeletal malformations of the hands and feet such as microdactilia, syndactilia, polydactilia, agenesis of one or more feet phalanx; moreover it presents a progressive heterotopic ossification of soft tissues (4).

3. Pseudomalignant MO is a myositis without history of trauma (5). These patients present a soft tissue mass with intermittent pain and localized erythema. More frequent localization is around the pelvis, greater trochanter, femur, and knee.

4. MO associated with paraplegia; the prognosis is poor. Costello e Brown (6) indicate as primitive event the atrophy and tissue degeneration.

MO is considered as predisposing factor for Temporomandibular Joint ankylosis.

### Case report

A 62-years-old, Caucasian female was observed at our Department of Maxillofacial surgery because of an opening mouth reduction. The patient was affected by hypertension since 12 years

<sup>1</sup> ENT Unit, Second University of Naples, Naples, Italy

<sup>2</sup> Maxillofacial Department, "Federico II" University of Naples, Naples, Italy

<sup>3</sup> Maxillofacial Resident Department,

"Federico II" University of Naples, Naples, Italy

<sup>4</sup> Maxillofacial Unit, Faculty of Medicine and Psychology,

"Sapienza" University of Rome, Rome, Italy

<sup>5</sup> Unit of Maxillo-Facial Surgery, University of Pisa,

Azienda Ospedaliera Universitaria Pisana, Pisa, Italy

<sup>6</sup> Maxillofacial Resident, Faculty of Medicine and Surgery,

University of Messina, Messina, Italy

<sup>7</sup> Maxillofacial Unit, Faculty of Medicine and Psychology,

"Sapienza" University of Rome, Rome, Italy

Corresponding author: Elidon Mici; elidon.mici@yahoo.it

© Copyright 2013, CIC Edizioni Internazionali, Roma

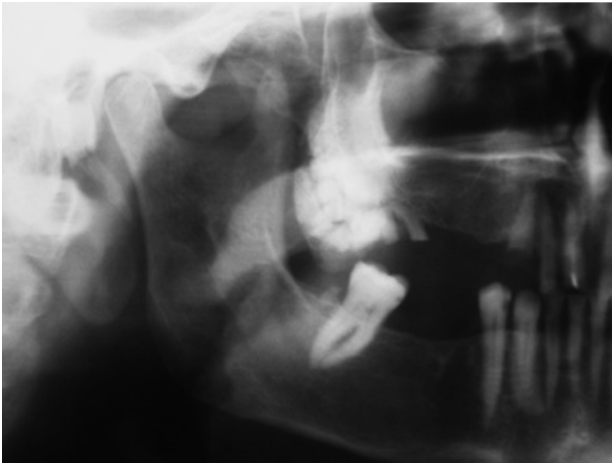


Fig. 1 - Preoperative orthopantomography showing an iperdense area of the right upper jaw.

and underwent colon resection two years before for colorectal carcinoma. Two months before our observation an incidental orthopantomography was performed that showed an iperdense area of the right upper jaw (Fig. 1). Clinically there was a flattening of the upper right vestibular fornix, with a modest reduction of the mouth opening for the presence in 18-16 area of a hard, smooth mass. The Computed Tomography (CT) scan showed a grossly round mass, 3 cm in the larger diameter, fixed to the posterior-lower part of right malar bone, with inhomogeneous bone density (Figs. 2a,b). This lesion was in close proximity to Bichat fat and masseter muscle, and presented inside calcific microformations compatible with tooth bud.

Under general anaesthesia the mass was removed by a trans-oral approach (Fig. 3).

The lesion measured 3 cm in greatest diameter, and was well circumscribed. The cut surface was white and soft in the centre, and yellow-grey with a rough granular surface at the periphery (Fig. 4). The tumour was routinely fixed in 10% buffered formaldehyde and embedded in paraffin; 5µ thick sections were cut and stained with haematoxylin-eosin.

Microscopically, the lesion showed lamellar bone together with intersperses fat cells, fibrous tissue, and thin-walled vascular spaces. The results suggested the diagnosis of MO.

The patient was followed-up every three months for two years with orthopantomography and CT scan twice a year (Fig. 5). After surgery there was an improvement in opening of the jaw that was observed constant also during following controls.

## Discussion

Myositis ossificans, contrary to the name, is not an inflammatory condition and in some case there is no evidence of bone or muscle in the lesion. Gilmer e Anderson (7) consider myositis ossificans a benign condition with eterotopic formation of bone in the muscular tissue.

The anamnesis and the clinical examination in patients with reduced mouth opening and/or recently operated in the oral cavity is fundamental for the diagnosis. Radiologic findings (Computed Tomography and Magnetic Resonance) allow to define the extension and,

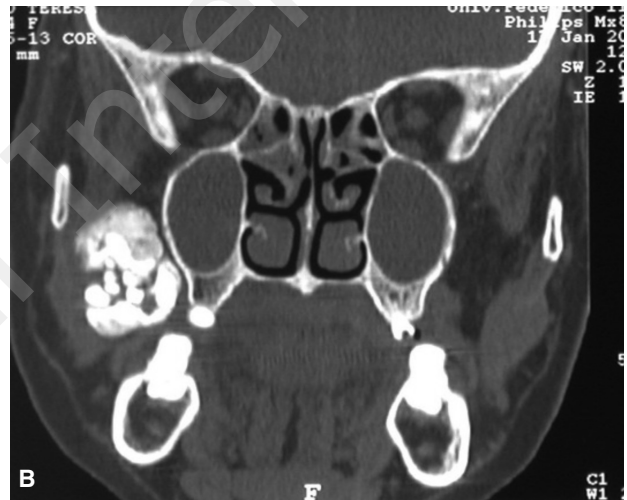
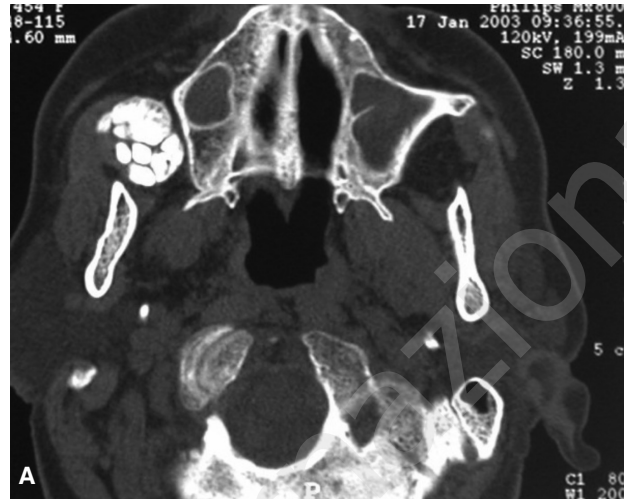
Fig. 2 - Preoperative CT scans in axial (A) and coronal (B) view showing an inhomogeneous bone density mass fixed to the posterior-lower part of right malar bone.

in many cases, the nature of the lesion with characteristic pattern according the degree of development (8, 9).

Histology is very important in diagnosis identifying the characteristic *zonal* arrangement of the lesion and in order to avoid incorrect diagnosis it is indicated to remove the entire lesion.

Firstly Gotte (10) and then Wakely (11) described the characteristic zonal arrangement:

- a central zone characterised by the presence of an inflammatory infiltrate with macrophages, lymphocytes, polymorphic fibroblasts and angiogenesis phenomena, muscular fibres with atrophic or degenerative appearance;
- an intermediate zone with a more regular appearance with collagen trabeculae and immature, osteoid cells;
- a peripheral zone made by calcified osteoid with ar-

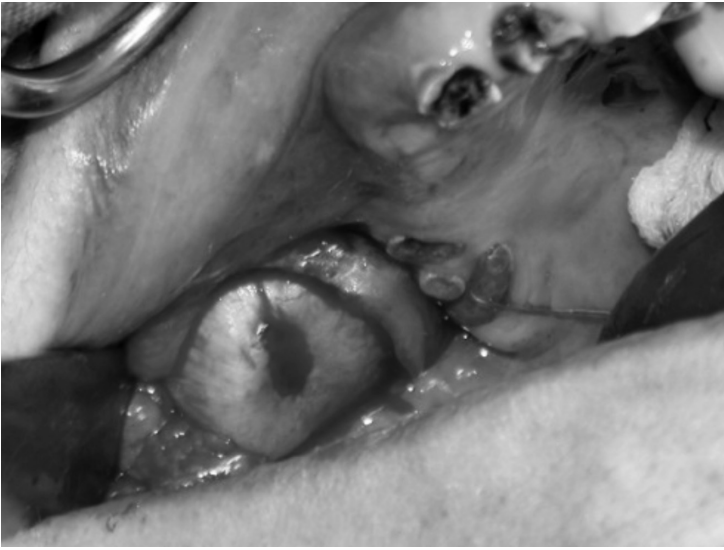

Fig. 3 - Intraoperative picture showing the trans-oral approach for mass removal.

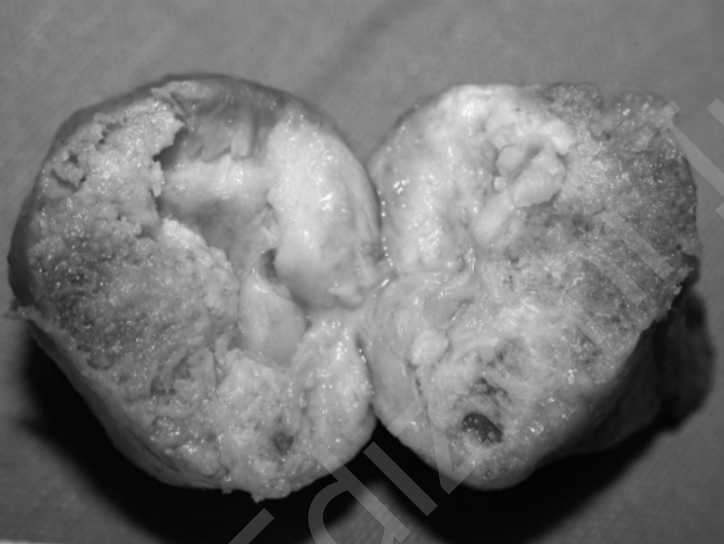

Fig. 4 - The cut surface was white and soft in the centre, yellow-grey with a rough granular surface at the periphery.

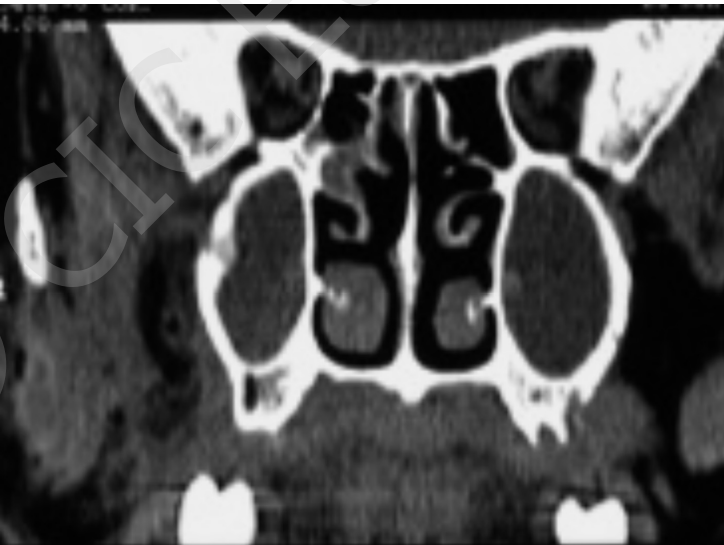

Fig. 5 - Two year postoperative TC scan on coronal view showing the complete mass removal.

reas of cartilaginous metaplasia and lamellar mature bone separated from the surrounding muscle by connective tissue without inflammatory infiltrate.

Therapy is based on surgical complete removal of the lesion followed by a prudent rehabilitation with minimal trauma starting as soon as possible. Nowadays en-

doscopy is widely used in maxillofacial surgery, and it can be used for removal of such lesions (12-15).

Sometimes a medical treatment is still indicated with prolonged assumption of Etidronic Acid (16) and myorelaxing drugs. After surgery we recommend cold therapy in order to minimize swallow and post oper

## References

1. Ackerman LV, Extra-osseous localized non-neoplastic bone and cartilage formation (so-called myositis ossificans). *J Bone Joint Surg Am* 1958;49:279-98.
2. Abidin HA, Prabhu SR. Traumatic myositis ossificans of lateral pterygoid muscle. *J Oral Med* 1984;39:54-6.
3. Narang R, Dixon RA Jr. Myositis ossificans: medial pterygoid muscle a case report. *Br J Oral* 1974;12:229-39.
4. Kaplan FS, Tabas JA, Zasloff MA. Fibrodysplasia ossificans progressiva: a clue from the fly. *Calcif Tissue Int* 1990;47:117-25.
5. Heinrich SD, Zembo MM, MacEwen GD. Pseudomalignant myositis ossificans. *Orthopedics* 1989;12:599-602.
6. Costello FV, Brown A. Myositis ossificans complicating anterior poliomyelitis. *J Bone Joint Surg Br* 1951;33:594-7.
7. Gilmer WS, Anderson LD. Reactions of soft somatic tissue which may progress to bone formation: circumscribed (traumatic) myositis ossificans. *South Med J* 1959;52:1432-48.
8. Shorkhoda A, Armin AR, Bis KG, Makris J, Irwin RB, Shetty AN. MR imaging of myositis ossificans: variable patterns at different stages. *J Magn Reson Imaging* 1995;5(3):287-92.
9. Cvitanic O, Sedlak J. Acute myositis ossificans. *Skeletal Radiol* 1995;24(2):139-41.
10. Gotte P, Cortelazzi R, Politi M, Sonetti F, Pelosi G. Myositis ossificans traumatica del muscolo pterigoideo mediale. *Minerva Stomatol* 1988;37(10):757-62.
11. Wakely PE jr Almeida M, Frable WJ. Fine-needle aspiration biopsy cytology of myositis ossificans. *Mod Pathol* 1994;7(1):23-5.
12. Belli E, Rendine G, Mazzone N. Concha bullosa: endoscopic treatment. *J Craniofac Surg* 2009;20(4):1165-8.
13. Belli E, Longo B, Balestra FB, Matteini C. Could transcranial endoscopy represent an alternative to craniotomy in skull base surgery. *J Craniofacial Surg* 2005;16(1):155-8.
14. Castelnuovo PG, Belli E, Bignami M, Battaglia P, Sberze F, Tomei G. Endoscopic nasal and anterior craniotomy resection for malignant nasoethmoid tumors involving the anterior skull base. *Skull Base* 2006;16(1):15-8.
15. Belli E, Matteini C, D'Andrea GC, Mazzone N. Navigator system guided endoscopic intraoral approach for remodelling of mandibular condyle in Garré syndrome. *J Craniofac Surg* 2007;18(6):1410-5. Erratum in: *J Craniofac Surg* 2008;19(1):293.
16. Oz BB, Boneh A. Myositis Ossificans Progressiva: a 10-year follow-up on a patient treated with etidronate disodium. *Acta Paediatr* 1994;83(12):1332-4.
17. Belli E, Rendine G, Mazzone N. Cold therapy in maxillofacial surgery. *J Craniofac Surg* 2009;20(3):878-80.