

# Paget's disease of the hip

Javad Parvizi<sup>1</sup>  
Camilo Restrepo<sup>1</sup>  
Franklin H. Sim<sup>2</sup>

<sup>1</sup> Rothman Institute of Orthopedics, Jefferson Hospital, Philadelphia and <sup>2</sup> Mayo Clinic, Rochester, Minnesota, USA

Address for correspondence:

F.H. Sim, M.D.  
Department of Orthopedic Surgery  
Mayo Clinic, Rochester, MN 55905, USA  
Ph. +1 507 284 2511  
Fax +1 507 266 4623  
E-mail: sim.franklin@mayo.edu

## Summary

**Paget's disease often affects the femur and the acetabulum. The old age of these patients together with the underlying disease can result in progressive arthritis of the hip necessitating hip arthroplasty. Uncemented hip arthroplasty is a viable option for these patients with good mid-term results. Concurrent corrective osteotomy or need for custom made prosthesis may need to be considered.**

**KEY WORDS:** Paget's disease of bone, orthopedic complications, hip arthroplasty.

## Introduction

First described by Sir James Paget in 1876, the exact etiology of the disease remains unknown today. Genetic predisposition, slow virus or bacterial infection has been postulated as possible causes (1). Although its incidence may be declining (2), Paget's disease may affect up to 3.5 per cent of persons older than forty-five years (3). The pelvis and the femur are the areas of the skeleton most commonly involved and may be affected in up to eighty per cent of patients with Paget's disease (4, 5). Paget's disease is a localized disorder of the bone marked by increased bone resorption, bone formation and remodeling, which may lead to major deformity and altered joint mechanics. These deformities, alterations in bone quality, and the older age of the pagetoid patients may all contribute to the development of severe degenerative joint disease of the hip.

## Pathophysiology

The metabolic hyperactivity is the main feature of Paget's disease. Excessive activity of osteoclasts results in resorption of the bone, leading to creation of voids and cavities in the bone. The physiological compensatory mechanism for repair results in lying down of fibrotic tissue in these cavities and even new bone by osteoblasts. There is a high degree of vascularity in

the pagetoid bone due to the increased metabolic activity. The disruption of the architecture of the bone occurring as a result of excessive osteoclast activity leads to mechanical weakening of the cortex and creation of microfractures. The increased bone resorption and the excessive metabolic activity as well as microfractures are all thought to be the cause of pain in patients with underlying Paget's disease of the bone (6). The newly formed bone matrix remains non-organized and lacks the mechanical strength of normal bone (7). The continued process of excessive activity and creation of microfractures result in deformities with resultant change in the biomechanical milieu of the adjacent joints. The latter combined with the old age predispose these patients to arthritis.

Femur is one of the most commonly affected bones (4, 5). The deformities observed around the hip in patients with Paget's disease includes coxa vara, femoral bowing with enlargement of the intramedullary canal, and protrusio acetabuli (5).

## Diagnosis

The radiographs of affected pagetoid bone have a classical appearance (Figure 1). There is combination of sclerosis and radiolucencies of the affected cortex. Disruption of the normal architecture is apparent with loss of tension bands in the proximal femur and the periacetabular region. The pagetoid bone appears capacious and disorganized on cross sectional studies such as CT scan and MRI. Bone scan shows area of dense uptake in pagetoid bone because of the underlying high metabolic activity.

Serological markers can also be helpful in diagnosis of Paget's disease. The bone specific alkaline phosphatase is elevated. The level of bone breakdown products such as pyridolines and hydroxyproline are also high.

Patients with Paget's disease usually present with severe pain and may exhibit gross deformities of the long bones. The flat bones particularly that of skull may also be affected resulting in frontal bossing. The vertebra, when affected, becomes disrupted with narrowing of the spinal canal. Symptoms of spinal stenosis are not uncommon in these patients. In addition loss of hearing, affected inner ear bones, and high output cardiac failure may be seen.

## Treatment

Management of patients with Paget's disease can be challenging. The mainstay of treatment is to relieve pain and improve function. This often necessitates administration of nonsteroidal anti-inflammatory medications and other analgesics. In order to retard excessive osteoclastic activity bisphosphonate drugs may be administered. Joint arthroplasty for Paget's patients with end-stage symptomatic arthritis may be indicated. Due to gross deformities osteotomy of the affected bone either as an isolated procedure or at the time of arthroplasty may be indicated (8). When a subcapital or intracapsular hip fracture occurs in a pre-existing pagetoid bone, total hip arthroplasty may be indicated if acetabular bone is also affected (9).

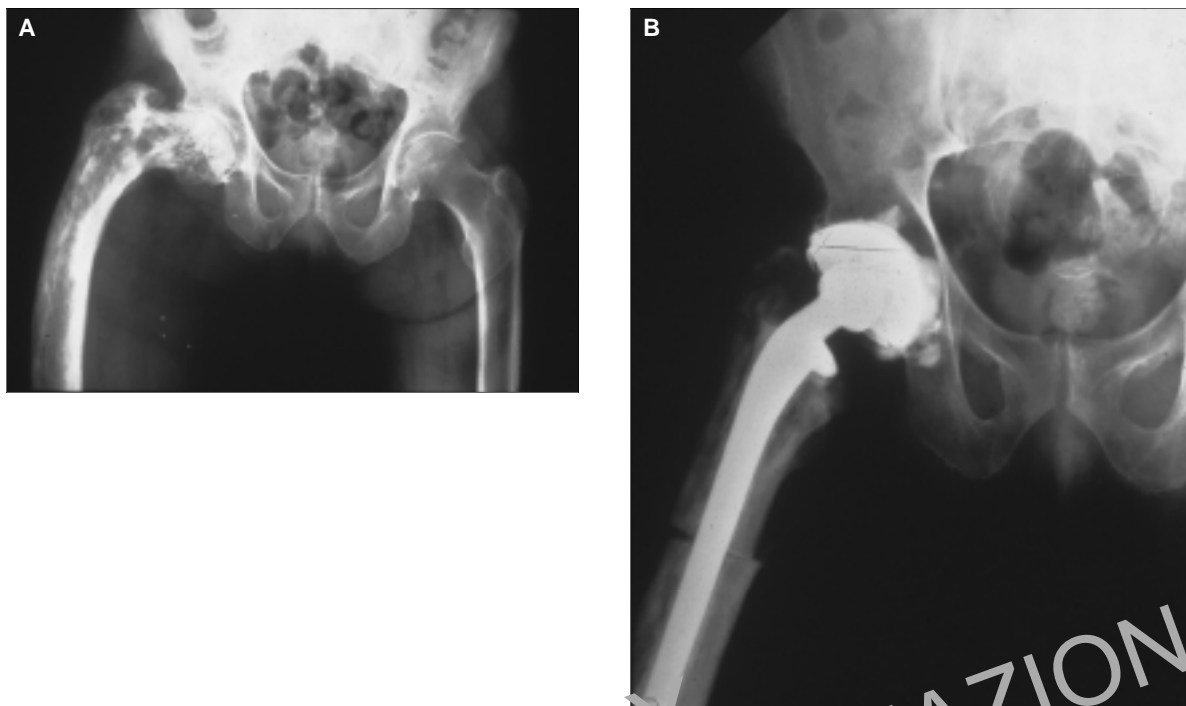


Figure 1 - Anteroposterior radiograph of a patient with Paget's disease. The loss of normal trabecular pattern of the bone, widening of the canal, and the ensuing deformity is all apparent (A). Intraoperative osteotomy had to be performed to allow insertion of femoral prosthesis (B).

### Outcomes

Although few patients with Paget's disease ever require surgical therapy, successful surgical management of severe orthopedic complications has improved the quality of life for these patients. Total hip arthroplasty (THA) has consistently been reported to improve function for these patients (10, 11).

The optimal method of fixation of hip components against pagetoid bone has been debated in the past. Cemented total hip arthroplasty is reported to be a viable and accepted treatment modality for symptomatic coxarthrosis of the hip in patients with Paget's disease (5, 12-16). However, a higher incidence of symptomatic and asymptomatic radiolucencies around the bone-cement interface of components placed against pagetoid bone has been documented with the possibility of increased rates of implant failure over an intermediate time frame postoperatively discussed (12, 14, 15). Radiolucencies occurred in twenty of thirty-two acetabular components implanted against pagetoid bone in one series (12). Merkow et al. reported on twenty-one cemented hips that showed the need for two revisions (9.5%) at 5.2 years follow-up (15). Previously McDonald et al. reported the results of ninety-one cemented total hip arthroplasties in eighty patients with significantly higher incidence of revision (fifteen per cent) in patients with Paget's disease compared to the unselected population receiving total hip arthroplasty during the same time period ( $p < 0.001$ ) (13). Radiographic loosening of twenty-nine per cent, cup loosening of 13.5 per cent, and a fall off of good and excellent results to seventy-four per cent of the total in that same series, all pointed to increasing problems with longer follow-up (13).

Use of uncemented acetabular components during hip arthroplasty has become the preferred method for the majority of hip arthroplasties, with reports of better survivorship and a lower

loosening rate for uncemented acetabular components when compared to cemented alternatives (17-19). Concerns exist, however, regarding implantation of uncemented components against pagetoid bone, as it is not known whether the altered quality and morphology of bone adversely influences ingrowth into uncemented implants. Some surgeons, because of the underlying abnormal bone metabolism, refrain from placing an uncemented component in the hip. However, in recent years there have been reports showing excellent osseointegration of press fit components placed against pagetoid bone (10, 20). The mid-term result of uncemented femoral and acetabular components in patients with Paget's disease have been encouraging (10, 20). Paradoxically uncemented hip arthroplasty may be a better treatment option for patients with Paget's disease as sclerotic abnormal bone in these patients precludes optimal cement interdigitation. In one study intended cementing of hip components had to be abandoned in some patients because of perceived inability to obtain good cement interdigitation and bonding.

### Complications

Osteolysis following THA in Paget's disease patients, thought to be related to the increased metabolic turnover though rare has been reported (18, 21, 22). But much more evidence has been reported reinforcing the concept that no rapid osteolysis has been found after cemented (15) and uncemented (5, 10, 23, 24) primary or revision THA.

Patients with Paget's disease are still at moderate risk for developing heterotopic ossification (HO) after THA, compared to those at high risk like previous history of HO in either hip, bilateral hypertrophic osteoarthritis or posttraumatic arthritis. This is

the basis for starting preventive measures (pre-op and post-op radiation and prophylactic drug regimens) (1, 25).

Excessive bleeding during surgery is one of the most common complications related to Paget's disease, which is attributed to hypervascularity of the bone, technical difficulty prolonging the procedure, and the need for additional procedures such as osteotomy during the hip arthroplasty (10, 24). In any case large amount of cross matched blood may need to be available for pagetoid patients undergoing surgical procedures.

Other complications include nonunion of the trochanteric osteotomy (24) in the formerly used approach for THA, and higher incidence of periprosthetic fractures around hip arthroplasty components (26).

Continuation of bone pain following joint arthroplasty, due to the presence of disease or coexistent deformity, pathological microfractures and on very rare instances malignant transformation can also occur. Malignancy, mostly osteosarcoma, can develop in one percent of Paget's patients (27). Transmission of Paget's disease, during autologous bone grafting, from one location to another has also been described (28).

## References

1. Ferguson DJ, Itonaga I, Maki M, et al. Heterotopic bone formation following hip arthroplasty in Paget's disease. *Bone*. 2004;34(6):1078-83.
2. Van Staa TP, Selby P, Leufkens HG, et al. Incidence and natural history of Paget's disease of bone in England and Wales. *J Bone Miner Res*. 2002;17(3):465-71.
3. Pygott F. Paget's disease of bone; the radiological incidence. *Lancet*. 1957;272(6980):1170-1.
4. Cooper C, Dennison E, Schaffheutle K, et al. Epidemiology of Paget's disease of bone. *Bone*. 1999;24(5 Suppl):3S-5S.
5. Ludkowsky P, Wilson-MacDonald J. Total arthroplasty in Paget's disease of the hip. A clinical review and review of the literature. *Clin Orthop*. 1970;(255):160-7.
6. Winfield J, Starup TC. Bone and joint deformations in Paget's disease. *Am J Rheum Dis*. 1984;43(6):769-75.
7. Salmon H. Loss of chaotic trabecular structure in OPG-deficient juvenile Paget's disease patient indicates a chaogenic role for OPG in nonlinear pattern formation of trabecular bone. *J Bone Miner Res*. 2004;19(5):695-702. Epub 2004 Feb 16.
8. Parvizi J, Frankle MA, Tiags RD, et al. Corrective osteotomy for deformity in Paget disease. *J Bone Joint Surg Am*. 2003;85-A(4):697-702.
9. Sorbie C. Arthroplasty in the treatment of subcapital hip fracture. *Orthopedics*. 2003;26(3):337-41; quiz 342-3.
10. Parvizi J, Schall DM, Lewallen DG, et al. Outcome of uncemented hip arthroplasty components in patients with Paget's disease. *Clin Orthop*. 2002;(403):127-34.
11. Kirsh G, Kligman M, Roffman M. Hydroxyapatite-coated total hip replacement in Paget's disease: 20 patients followed for 4-8 years. *Acta Orthop Scand*. 2001; 72(2):127-32.
12. Martell JH, Galante JO, Pierson RH, et al. Clinical experience with primary cementless total hip arthroplasty. *Chir Organi Mov*. 1992; 77(4):383-96.
13. McDonald DJ, Sim FH. Total hip arthroplasty in Paget's disease. A follow-up note. *J Bone Joint Surg Am*. 1987;69(5):766-72.
14. Merkow RL, Lane JM. Paget's disease of bone. *Orthop Clin North Am*. 1990;21(1):171-89.
15. Merkow RL, Pellicci PM, Hely DP, et al. Total hip replacement for Paget's disease of the hip. *J Bone Joint Surg Am*. 1984;66(5):752-8.
16. Stauffer RN, Sim FH. Total hip arthroplasty in Paget's disease of the hip. *J Bone Joint Surg Am*. 1976;58(4):476-8.
17. Callaghan JJ, Forest EE, Sporer SM, et al. Total hip arthroplasty in the young adult. *Clin Orthop*. 1997;(344):257-62.
18. Lewallen DG. Hip arthroplasty in patients with Paget's disease. *Clin Orthop*. 1999;(369):243-50.
19. Smith SE, Garvin KL, Jardon OM, et al. Uncemented total hip arthroplasty. Prospective analysis of the tri-lock femoral component. *Clin Orthop*. 1991;(269):43-50.
20. Hozack WJ, Rushton SA, Carey C, et al. Uncemented total hip arthroplasty in Paget's disease of the hip: a report of 5 cases with 5-year follow-up. *J Arthroplasty*. 1999;14(7):872-6.
21. Alexakis PG, Brown BA, Hohl WM. Porous hip replacement in Paget's disease. An 8-2/3-year followup. *Clin Orthop*. 1998;(350):138-2.
22. Oakley AP, Matheson JA. Rapid osteolysis after revision hip arthroplasty in Paget's disease. *J Arthroplasty*. 2003;18(2):204-7.
23. Namba RS, Brick CW, Murray WM. Revision total hip arthroplasty with a correctional femoral osteotomy in Paget's disease. *J Arthroplasty*. 1997;12(5):591-5.
24. Cocharan DH, Porter ML. Charnley low-friction arthroplasty for Paget's disease of the hip. *J Arthroplasty*. 2000;15(2):210-9.
25. Iorio R, Healy WL. Heterotopic ossification after hip and knee arthroplasty: risk factors, prevention, and treatment. *J Am Acad Orthop Surg*. 2002;10(6):409-16.
26. Dunlop DJ, Donnachie NJ, Treacy RB. Failure after customized curved femoral stems in total hip arthroplasty for Paget's disease. *J Arthroplasty*. 2000;15(3):398-401.
27. Haibach H, Farrell C, Dittrich FJ. Neoplasms arising in Paget's disease of bone: a study of 82 cases. *Am J Clin Pathol*. 1985;83(5):594-600.
28. Hamadouche M, Mathieu M, Topouchian V, et al. Transfer of Paget's disease from one part of the skeleton to another as a result of autogenous bone-grafting: a case report. *J Bone Joint Surg Am*. 2002; 84-A(11):2056-61.